



MEMBERS NEWS EDUCATION & RESEARCH MEETINGS JOURNAL

## ARS NOSE NEWS OCTOBER 2017

### TABLE OF CONTENTS

[President's Report](#)  
[Summer Sinus Symposium: Recap](#)  
[Past President's Report](#)  
[Rhinology Perspectives: Management of Epistaxis](#)  
[Quality Improvement Committee Report](#)  
[Cast of the Quarter](#)  
[2017 Friends in Research Update](#)  
[Patient Advocacy Committee Reprt](#)  
[Thank you to Corporate Sponsors](#)  
[ARS Contact Information](#)

### PRESIDENT'S REPORT

Richard Orlandi, MD, FARS

*"The American Rhinologic Society's mission is to serve, represent and advance the science and ethical practice of rhinology."*

It is an honor for me to serve this next year as the president of your American Rhinologic Society. Under the leadership of our previous president, John DelGaudio, MD, FARS, the ARS is strong and vibrant. Joseph Jacobs, MD, FARS, is completing the third year of his outstanding service as our Executive Vice President. We have an extremely committed executive committee, board of directors, consultants to the board, and committee chairs who serve the interests of our members and our patients.

I would like to extend a thank you to Sarah Wise, MD, FARS, and Rick Chandra, MD, FARS, for their dedicated service on the board of directors these last three years. Subinoy Das, MD, FARS, and Devyani Lal, MD, FARS, just completed their terms as very involved consultants to the board and deserve our thanks as well. At our last meeting in Chicago, we also paid tribute to six committee chairs who completed their service. Marilene Wang, MD, FARS, Jastin Antisdell, MD, FARS, Zara Patel, MD, FARS, Eric Holbrook, MD, FARS, Samer Fakhri, MD, FARS, and Peter Manes, MD, FARS, are all to be thanked for advancing the ARS through their leadership. Their replacements indeed have big shoes to fill.



The ARS remains strong because of leaders like these and because of the large number of physician volunteers who are dedicated to its mission. Whether it's contributing to our educational mission on our awards, CME, education, and program committees; providing guidance and oversight through our audit and bylaws committees; enhancing the care of our patients in our research, patient advocacy or quality improvement committees; or providing essential support in our membership, development, IT, marketing, newsletter, pediatric, international, and residents/fellows committees, each of you make the ARS the great society it is!

We will undoubtedly have some headwinds this next year. There is no reason to believe this year will be any different than the past and I am certain that our leaders in the ARS up are to the task. They are a vibrant and engaged group with diverse backgrounds and perspectives. I urge you to continue to contribute to our society

and, if you are not yet as involved as you could be, please consider making that change. Our 1st Vice President, Robert Kern, MD, FARS, leads the committee on committees and will be seeking new members for all of our committees this coming year.


Finally, as ARS members, our different experiences and backgrounds give us a variety of perspectives. Each of these is valuable and important – even essential – as we face our collective challenges. Your input is welcomed and encouraged. Please don't hesitate to contact me or any of your ARS leaders with ideas and concerns.

[Back to top](#)

## SUMMER SINUS SYMPOSIUM 2017 RECAP

Greg Davis, MD FARS; Marc Dubin, MD FARS; Doug Reg, MD FARS

This was a year of firsts for the Summer Sinus Symposium with 3 new course directors and a new city, Washington D.C. The Omni Shoreham in D.C. proved to be a terrific venue. We had our best attendance ever with 454 people attending, exceeding the previous (record breaking) year's attendance by over 100 registrants. Over 50 viewers registered for and watched the global cast live stream.



The meeting kicked off with keynote speaker Congressman Phil Roe, MD. Dr. Roe serves the First Congressional District of Tennessee and is the current co-chair of the House GOP Doctors Caucus and is a member of the Health Caucus. The room was packed as Dr. Roe discussed ongoing health care reform and the challenges faced by Congress. This was followed by excellent panels on primary endoscopic sinus surgery, revision sinus surgery and technical challenges for successful frontal sinus surgery. The opening date was capped off by an excellent dissection performed by Dr. Jivianne Lee and moderated by incoming ARS President, Richard Orlandi.

The following day saw packed audiences enjoying panels on new trends in the medical management of CRS moderated by Tim Smith, novel technologies and post-operative steps to improve outcomes in sinus surgery. On Saturday afternoon, there were multiple, excellent non-CME corporate hosted dissection labs where participants could try out new technologies and learn novel surgical techniques in 4 live dissection labs. The course finished on Sunday with multiple break-out rooms covering topics ranging from the neurology lecture on evaluation and management of headaches in sinus patients, advances in in-office allergy treatments and advanced endoscopic skull base techniques.

Next year, this fabulous meeting moves to Seattle, WA at the Westin Seattle on July 12-14, 2018. We continue to solicit feedback from our participants to expand and improve the program to cover topics that are important to the otolaryngologist treating patients with chronic sinus disease and allergy. This meeting has been and will continue to be a great success since it is a meeting run by you and for you. So please join us in Seattle, WA in July 2018! It's a meeting that isn't to be missed.

[Back to top](#)

## PAST PRESIDENT'S REPORT

John DeIGaudio, MD, FARS

I am honored to have had the opportunity to serve as the President of the American Rhinologic Society for the past year. In addition to hosting 3 successful national meetings, much has happened in the past year.

The most significant event was the revaluation of the FESS codes. There was great contribution by the ARS membership in completing the surveys, and I would like to thank Pete Manes for his ongoing role in the process. Although the preliminary recommendations were not as favorable as we had hoped, the process is

still ongoing and we are working to get the best possible outcome for our specialty. Regardless of the result, this has opened the door to the ARS partnering with the AAO for the development of new codes for extended sinus procedures.

As I mentioned in my Spring Presidential address, we have focused significant effort on building our membership both here and abroad. One benefit of membership is free registration to the Summer Sinus Symposium. The 6th SSS was held in Washington DC in July. This is the first time it has been held anywhere other than Chicago. It was a very successful meeting, once again exceeding the attendance of the previous SSS meetings. Ninety-five first-time attendees became new members of the ARS. Thanks to first time SSS course directors Doug Reh, Mark Dubin, and Greg Davis for a successful first meeting. You have set yourself a high bar. Next year's SSS will be July 12-14 in Seattle. We look forward to seeing you there.



Significant progress has also been made in our International membership drive, as we are working to further expand the reach of the ARS beyond US borders. We value our international members and the relationships we have with rhinologic societies worldwide. ARS leadership met with the European Rhinologic Society leadership at IFOS in Paris and with multiple Asian Rhinologic Society leaders at Rhinology World in Hong Kong. I would like to thank Jivianne Lee and David Kennedy for their efforts in this process, along with Peter Hwang and Brent Senior for their willingness to broker some of the meetings with our Asian Rhinology leaders. The fall meeting of the ARS featured panel participation from Professors Claire Hopkins and Lou Zhang, representing leadership from the European and Chinese Rhinologic societies, along with our colleagues from many other countries. We look forward to continued participation of our international colleagues at our meetings. To attract more international members, we have rolled out a lower individual international membership rate, along with group membership rates for international societies. Thanks to Stacey Gray (Membership Chair) and Samer Fakhri (International Committee Chair) for their efforts.

Over the past year we have had significant growth of our educational content on the ARS website. Under the direction of Zara Patel, Chair of the Education Committee, the ARS webcast Virtual Rhinology II was viewed in all continents except Antarctica. This event featured national and international faculty and is available for viewing by all members on the ARS website. The fall ARS meeting featured the 2nd Annual ARS Resident Sinus Course, which was a success. The Education Committee, in conjunction with the Education Task Force, is working on additional offerings for our membership. Stay tuned ...

In the past year, a new Quality Improvement Committee was formed to be proactive in defining and evaluating quality in Rhinology. It is in the best interest of our specialty to take the lead in this process and not allow outside parties to define the metrics. In this short period of time, under the leadership of Luke Rudmik (Chair), two manuscripts have been published in IFAR. We look forward to further progress in this important process.

We are 8 months into the successful launch of DocMatter, the Rhinology communication board, which has been a great success. Under the direction of Spencer Payne, Chair of the IT Committee, we are planning significant expansion of the platform to interface with IFAR and other ARS links.

IFAR continues to be a highly-ranked Otolaryngology journal, now with a monthly publication. Over the past year there have been significant additions to the IFAR offering. The Case of the Month, headed by Ben Bleier, and the Scope it Out Podcast, hosted by Tim Smith, have been hugely successful. Please take the time to check out these new offerings.

Those of us who have been in practice for some time realize there is more and more regulation regarding how we interact and partner with industry. Despite these changes, the ARS continues to cultivate and strengthen our corporate partnerships. This is due to the hard work of our Development Committee. I would like to thank all our corporate sponsors for their continued support and partnership, without which we would not be able to offer many of the ancillary sessions that occur during our meetings. Please show your appreciation for their support by visiting with them during the breaks at the upcoming scientific meetings.

All our board members, committee chairs, and committee members selflessly devote their time and efforts to make our society better. You should know that each of you are greatly appreciated. Thank you for your dedication and service to the ARS.

And as always, I would be remiss to not recognize the glue that holds the ARS together, Wendi Perez. Thank you for your help over these past years, making sure I know where to be and when, and for all you do for the society.

I would like to take this opportunity to recognize the individuals who will be rotating off from their committee

chair and Board of Directors positions.

#### Chairs:

- Marilene Wang - Awards
- Jastin Antisdell - By-Laws
- Zara Patel - Education
- Eric Holbrook - Ethics
- Peter Manes - Newsletter
- Samer Fakhri - International
- Jamie Litvack - Residents & Fellows

#### Consultants to the Board

- Subinoy Das
- Devyani Lal

#### Board Members

- Rakesh Chandra
- Sarah Wise

Thank you for the privilege of serving as the President of the American Rhinologic Society this past year. It has been a highlight of my career. I look forward to continuing to serve the ARS in any way that I can be useful.



[Back to top](#)

## RHINOLOGY PERSPECTIVES: MANAGEMENT OF EPISTAXIS

Edward El Rassi, MD; Benjamin S. Bleier, MD

### Introduction

Epistaxis is a common problem affecting upwards of 60% of the population at some point in their lifetime<sup>1</sup>. The etiology of epistaxis is often idiopathic but known causes include trauma, nasal dryness, mucosal irritation, sinonasal tumors, and recent nasal or sinus surgery. Hypertension and bleeding diatheses are contributing systemic factors that play a role in the degree of epistaxis but are typically not the cause of epistaxis alone. Fortunately, the majority of epistaxis is minor and self-limiting; occasionally, epistaxis can be recurrent or severe prompting patients to seek medical attention. Epistaxis represents one of the most common otolaryngologic emergencies accounting for approximately 1 in every 200 emergency department visits in the United States<sup>2</sup>.

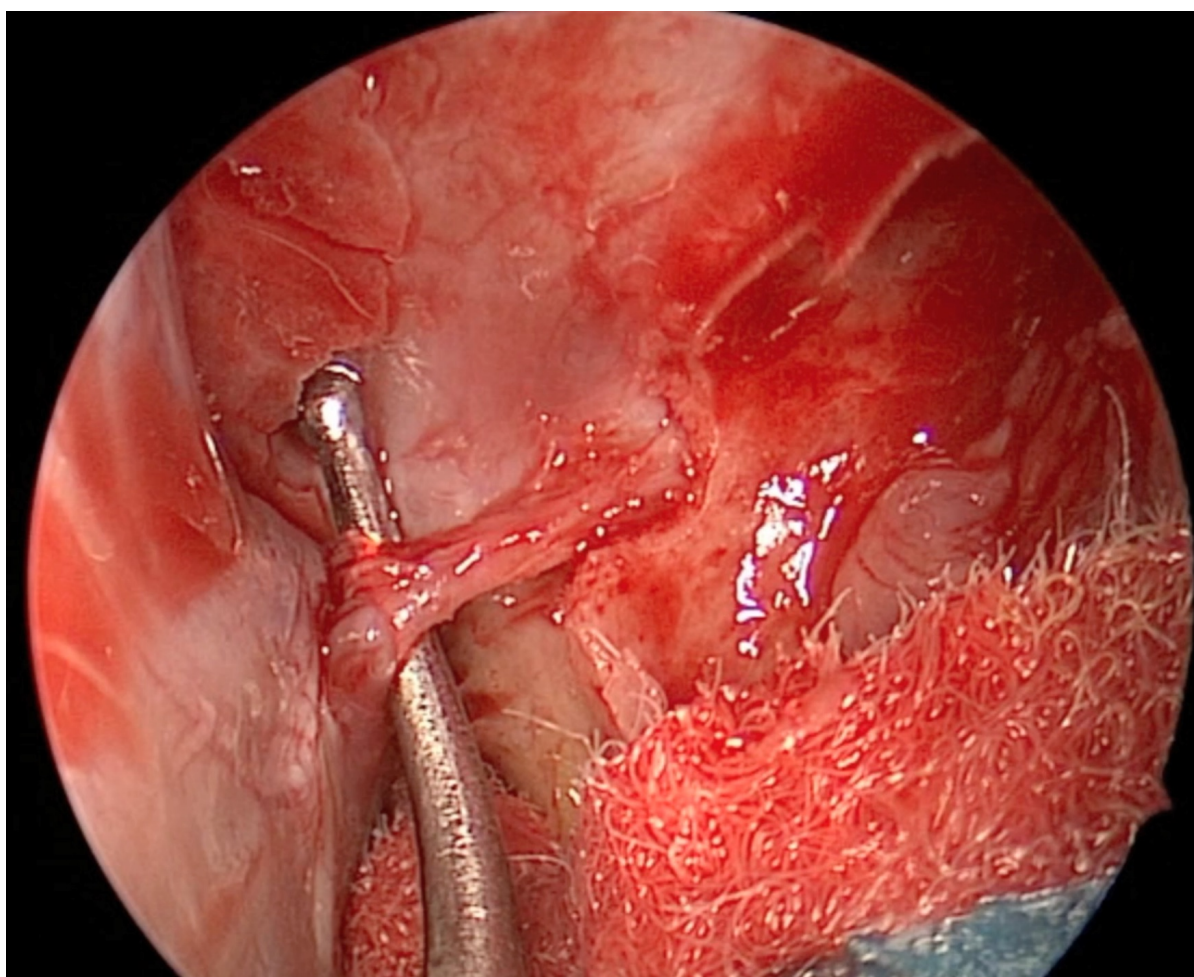
Epistaxis is generally classified as either anterior or posterior depending on the source location. The delineation between anterior and posterior epistaxis is somewhat arbitrary although practically speaking anterior epistaxis can be localized with a nasal speculum and headlight whereas posterior epistaxis cannot. Anterior epistaxis is more common, accounting for approximately 90% of epistaxis<sup>3</sup>, and is typically located along the anterior nasal septum from the Kiesselbach plexus or Little's area. Posterior epistaxis typically arises from more proximal branches of the sphenopalatine artery (SPA) along the nasal septum or from the lateral nasal wall in the area of the Woodruff plexus. Recent endoscopic sinus surgery can also result in posterior epistaxis, frequently from the posterior septal branch of the SPA injured at the time of sphenoidotomy.

Treatment of epistaxis can often be accomplished by digital pressure and vasoconstrictive medications alone although occasionally targeted cautery, application of thrombotic materials, and/or anterior nasal packing is necessary. Patients with intractable epistaxis who fail initial attempts at anterior nasal packing have traditionally been managed with prolonged posterior nasal packing. Unfortunately, posterior nasal packing has a high failure rate<sup>4-6</sup>, is poorly tolerated by patients<sup>7</sup>, and requires inpatient admission for cardiac monitoring. Due to these disadvantages, both endoscopic sphenopalatine artery ligation (ESPAL) and endovascular embolization are increasingly being used as first line treatment in patients with intractable epistaxis. A recent analysis evaluating national trends over a 5-year period demonstrated that although rates

of endovascular embolization have remained stable, the rates of ESPAL have declined<sup>8</sup>. A review of the literature on the two treatment options is presented here.

### Endoscopic Sphenopalatine Artery Ligation

Early descriptions of arterial ligation for epistaxis included trans-antral ligation of the internal maxillary artery via a sublabial incision and anterior maxillotomy<sup>9</sup>. This procedure was relatively successful but was associated with significant morbidity including facial pain, facial numbness, and oroantral fistula. As endoscopic endonasal techniques have evolved, ESPAL has become the procedure of choice for surgical management of epistaxis. The procedure has demonstrated great efficacy with published success rates from single-institution case series of over 30 patients ranging from 87% to 97%<sup>10-15</sup> with a pooled success rate of 91%. Failure has been associated with coagulopathy due to thrombocytopenia or the use antiplatelet or anticoagulant medication. Although clipping the artery was the initial description, there is evidence that cauterization of the sphenopalatine should be performed as well<sup>12</sup>. Risks are similar to that of endoscopic sinus surgery and include crusting (34%), sinusitis (3%), and septal perforation (3%) with a procedure specific complication of palatal numbness occurring in 13% of patients attributed to injury of the nearby greater palatine nerve<sup>10</sup>. This latter complication argues for the use of bipolar cautery and the need to skeletonize the artery and branches medial to the sphenopalatine foramen (Figure 1). Although quite rare, turbinate necrosis after ESPAL has been documented in case reports and carries the potential for significant morbidity.<sup>16,17</sup>



**Figure 1.** Skeletonization of the left sphenopalatine artery prior to ligation.

ESPAL begins with removal of any nasal packing and the clearing of blood contents from the nasal cavity. If there is concern for significant bleeding once the pack is removed, a greater palatine foramen injection of local anesthetic with epinephrine may be performed. The nasal cavity is then inspected to identify the source(s) of bleeding which can be addressed with targeted cauterization. Preparation of the nasal cavity is similar to that of endoscopic sinus surgery with decongestion and/or injections dependent on surgeon preferences. Next, a vertical mucosal incision is made medially along the palatine bone located just posterior to the posterior fontanelle. If necessary, a maxillary antrostomy may be performed to aid in visualization while resulting in a free mucosal edge along the palatine bone. Submucosal dissection proceeds posteriorly to identify the crista ethmoidalis which is removed to uncover the sphenopalatine foramen. The SPA and its branches are then identified, cauterized, and clipped.



It is important to be aware of the variability in the anatomy of the sphenopalatine foramen and the branches of the SPA. Although the SPA typically exits as a single artery, a prior anatomical study identified two branches in 33%, and three or more branches are present in 6% of patients.<sup>18</sup> Additionally, in approximately 9% of patients, an accessory foramen can be present often containing the posterior septal branch.<sup>19</sup> Failure to address all branches is thought to be a major contributing factor to failed ESPAL. For this reason, broad exposure with dissection extending towards the sphenoid rostrum or dissection laterally for more proximal ligation has been advocated.<sup>20</sup>

### **Endovascular Embolization**

Endovascular embolization of the internal maxillary artery for the management of epistaxis was first described in 1974.<sup>21</sup> The technique has been refined leading to the development of standardized protocols for a more systematic approach.<sup>22</sup> Additionally, the advent of super-selective embolization has led to the ability for more targeted treatment of specific branches of the internal maxillary artery with the purported advantage of decreased complications.<sup>23</sup> Since its introduction, endovascular embolization has become an established treatment option with comparable efficacy to ESPAL in the management of epistaxis with published success rates ranging from 71% to 100% and a pooled success rate of 88%.<sup>24</sup>

Embolization typically begins with pre-embolization angiography of the ipsilateral external carotid artery (ECA) and internal carotid artery (ICA) systems. This is done to identify specific causes of epistaxis (such as aneurysms, vascular malformations, or tumors) as well as dangerous anastomoses between the ECA and ICA that may increase the risk of blindness or stroke. Embolization of the ipsilateral internal maxillary artery is then performed distal to the middle meningeal artery (MMA) due to the potential of ECA to ICA anastomoses from the MMA. If significant contributions are present from the ipsilateral facial artery, embolization of this artery is completed as well. Importantly, embolization of the facial artery should be distal to the submandibular artery to prevent ischemic sialoadenitis. Diagnostic angiography is then performed on the contralateral side with embolization of the contralateral internal maxillary artery and facial artery being performed only if felt to be contributing significantly. Nasal packing is typically left in place and removed 12-24 hours after embolization.

Endovascular embolization is generally considered to be safe although not without its complications which are categorized as either minor transient, major transient, or permanent.<sup>25</sup> Minor transient complications include headache, facial pain, facial paresthesia, trismus, groin hematoma, and groin pain and occur in upwards of 25%. Major transient complications are quite uncommon with an incidence of less than 1% and include symptoms of temporary visual loss, hemiparesis, and soft tissue sloughing. Permanent complications are also uncommon with an incidence of 1-2% but carry significant morbidity and include visual loss, facial paralysis, scarring from soft tissue necrosis, and stroke. Clinicians should incorporate the risk of a major or permanent complication into their decision to pursue endovascular embolization and should inform patients of these risks when this treatment strategy is chosen.

### **Deciding Between Sphenopalatine Artery Ligation and Endovascular Embolization**

The decision between ESPAL and endovascular embolization often depends on the availability and clinical expertise of subspecialty trained physicians at a respective institution. Although ESPAL is only a minor extension beyond standard endoscopic sinus surgery, some otolaryngologists may not feel comfortable with the technique or may wish to maintain a more elective practice. Conversely, some institutions may not have interventional radiology or the appropriate experience with endovascular embolization for epistaxis. In these situations, the decision between ESPAL and endovascular embolization is forced. When both ESPAL and endovascular embolization are available, there are important considerations for the treating physician to consider since both have relatively equal success rates at controlling intractable epistaxis.

In the current healthcare climate where there is a growing emphasis on the responsible utilization of healthcare resources, clinicians should seek out strategies which are considered cost-effective. In an analysis by Villwock and Goyal<sup>26</sup> average costs across the United States for early treatment via ESPAL versus endovascular embolization were \$9746 and \$20,305, respectively. In a subsequent analysis, Rudmik and Leung performed a cost-effectiveness analysis between ESPAL and endovascular embolization incorporating published rates of rebleeding and complications with their associated costs.<sup>27</sup> The economic evaluation was performed using a decision tree model with the primary outcomes being cost per successful control of epistaxis and the incremental cost-effectiveness ratio (ICER). In this analysis, ESPAL was cheaper (\$12,484.14 vs \$22,324.70) but slightly less effective compared to embolization (0.68 vs 0.70). The ICER for embolization was \$492,028, indicating that the slight increased effectiveness is not cost-effective based on the generally accepted willingness-to-pay threshold of \$50,000 for in the United States.

Although cost-effectiveness is certainly important, the issue of risk and potential patient morbidity must also be considered by the treating physician. Surgical or endovascular intervention should not be taken lightly and patients should be informed on their options, including posterior nasal packing, and associated risks. Despite known rates of adverse events for all three treatment options, direct comparisons are difficult due to the difference in nature of complications and whether they are temporary or permanent. To standardize associated risk, Leung et al. performed an analysis of several ladder algorithms for the management of intractable epistaxis to determine what impact the order of intervention might have on the risk for an individual patient.<sup>28</sup> The risk model used published rates of adverse events associated with each intervention and monetized risk based on Environmental Protection Agency recommendations. Algorithms involving ESPAL as first-line interventions were associated with significant less risk than algorithms where endovascular embolization was first-line treatment on the order of approximately \$9,000. A significant limitation to the analysis is that it was based on a 50-year old patient with no relevant medical comorbidities and not taking any anticoagulant medication. Patients with epistaxis are often elderly patients with multiple cardiovascular comorbidities on anticoagulant medication which limits the application of this risk analysis.

Beyond cost-effectiveness and risk, there are a few intuitive advantages of electing ESPAL or endovascular embolization. At the time of ESPAL, anterior ethmoid artery (AEA) ligation may be attempted if felt to be indicated. This technique has been described and can be carried out via either a transcutaneous, transcaruncular, or endoscopic approach<sup>20</sup>. Due to the AEA branching off of the ophthalmic artery, embolization of the AEA is contraindicated due to the risk of blindness. It is important to stress that the exact role of AEA ligation in the management of epistaxis is not well delineated but it continues to be an option for select cases. ESPAL also allows for endoscopic examination of the nasal cavity to evaluate for an underlying pathology that could otherwise be missed as there have been reports of delay in diagnosis of sinonasal tumors in patients who underwent endovascular embolization.<sup>29</sup> Perhaps most significantly, ESPAL does not carry the risk of permanent ischemic events such as blindness or cerebrovascular accident. As for endovascular embolization, the ability to perform diagnostic angiography followed by targeted embolization of both the ipsilateral and contralateral branches of both the facial artery and internal maxillary artery offers an advantage of mapping out comprehensive vascular anatomy and targeted intervention. Clearly, the utility of endovascular embolization is irreplaceable in patients with a vascular abnormality such as an aneurysm or known vascular tumor (Figure 2 and Figure 3). Avoidance of intranasal instrumentation might also be preferred in the patient on antiplatelet or anticoagulant medications which is a risk factor of failed ESPAL. Lastly, endovascular embolization can be performed under sedation alone making it an appealing option in the patient with multiple medical comorbidities who is unable to tolerate general endotracheal anesthesia.

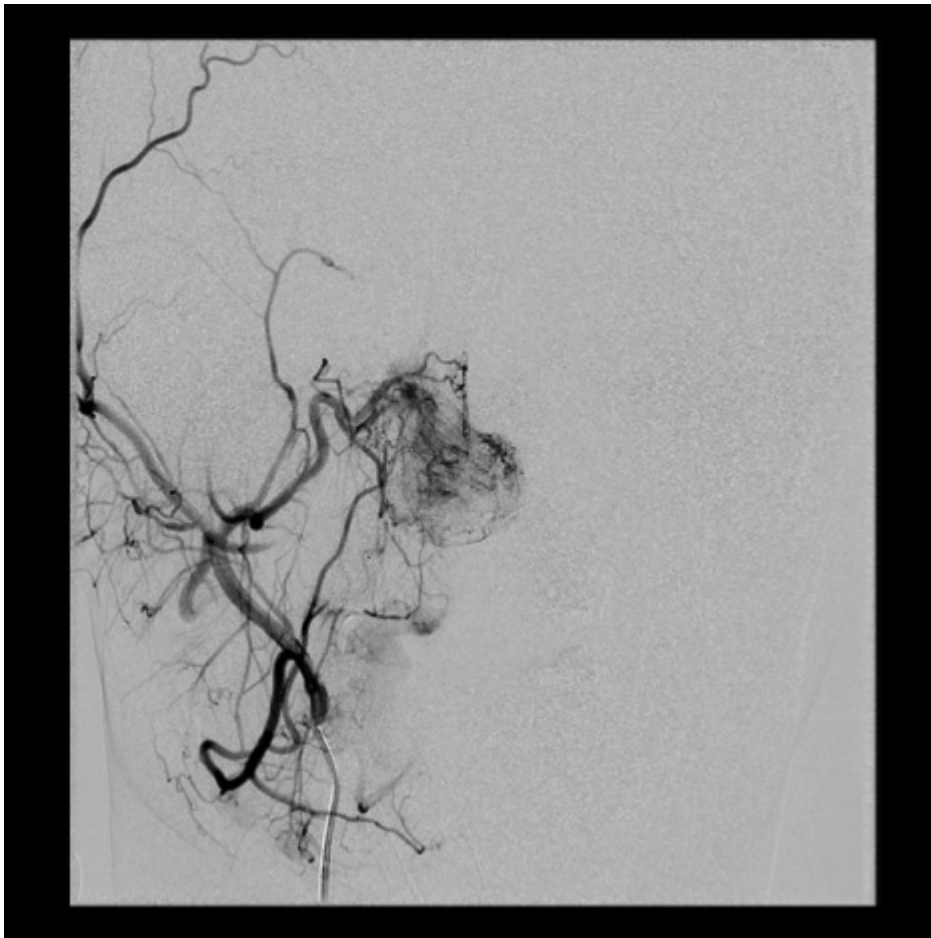
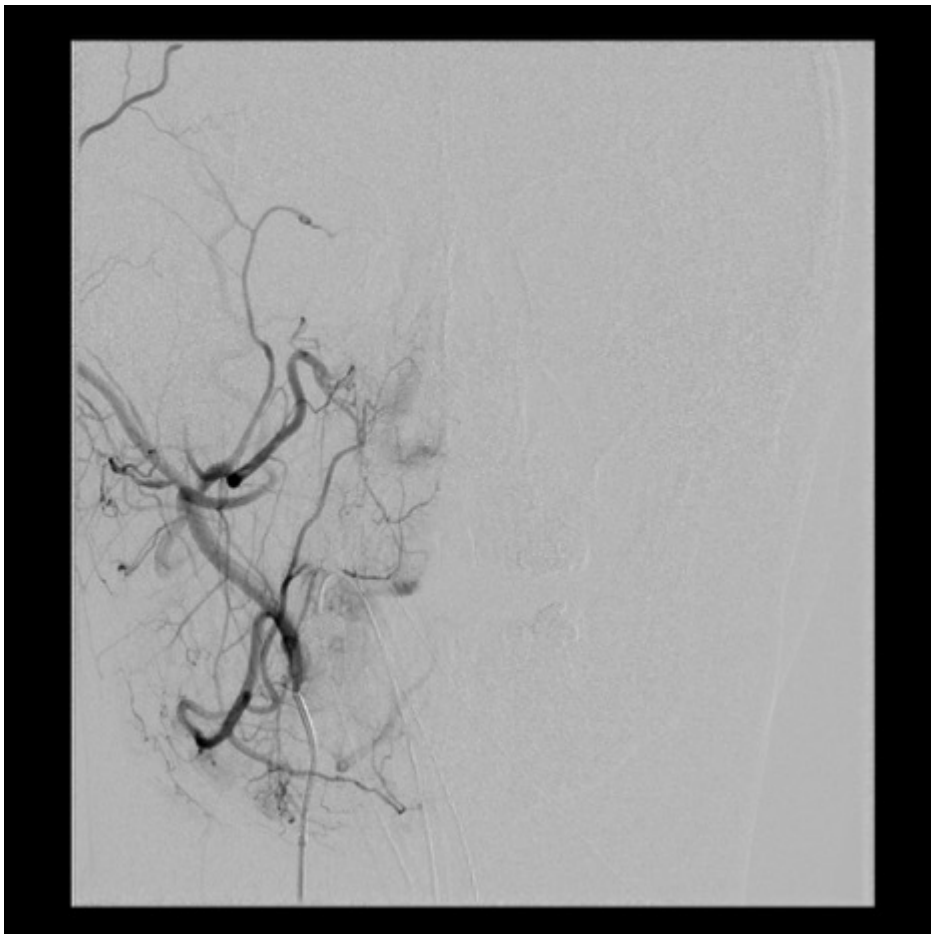


Figure 2. Diagnostic angiography of a patient with a right juvenile nasopharyngeal angiofibroma.





**Figure 3.** Angiography post-embolization of the right internal maxillary artery of the same patient in Figure 2.

## Conclusion

Epistaxis is a common reason for patients to present to the emergency department. Although most cases of epistaxis can be managed with conservative measures, occasionally epistaxis persists even despite anterior nasal packing. Posterior nasal packing continues to be an option; however, it is poorly tolerated and clinicians should be weary of the high failure rate. Based on the available evidence, ESPAL appears to be a safe, cost-effective first-line option in patients who can tolerate general endotracheal anesthesia yielding success rates greater than 90%. In patients who have a tumor, vascular abnormality, bleeding diathesis, or who are medically unfit for general endotracheal anesthesia, endovascular embolization should be preferred over ESPAL.

## References

1. Small M, Murray JA, Maran AG. A study of patients with epistaxis requiring admission to hospital. *Health Bull (Raleigh)*. 1982;40(1):20-29.
2. Pallin DJ, Chng Y-M, McKay MP, Emond JA, Pelletier AJ, Camargo CA. Epidemiology of epistaxis in US emergency departments, 1992 to 2001. *Ann Emerg Med*. 2005;46(1):77-81.
3. Padgham N. Epistaxis: anatomical and clinical correlates. *J Laryngol Otol*. 1990;104(4):308-311.
4. Schaitkin B, Strauss M, Houck JR. Epistaxis: medical versus surgical therapy: a comparison of efficacy, complications, and economic considerations. *Laryngoscope*. 1987;97(12):1392-1396.
5. Shaw CB, Wax MK, Wetmore SJ. Epistaxis: A Comparison of Treatment. *Otolaryngol Neck Surg*. 1993;109(1):60-65.
6. Klotz DA, Winkle MR, Richmon J, Hengerer AS. Surgical management of posterior epistaxis: a changing paradigm. *Laryngoscope*. 2002;112(9):1577-1582.
7. Nikolaou G, Holzmann D, Soyka MB. Discomfort and costs in epistaxis treatment. *Eur Arch Oto-Rhino-Laryngology*. 2013;270(8):2239-2244.
8. Sylvester MJ, Chung SY, Guinand LA, Govindan A, Baredes S, Eloy JA. Arterial ligation versus embolization in epistaxis management: Counterintuitive national trends. *Laryngoscope*. 2017;127(5):1017-1020.
9. Chandler JR, Serrins AJ. Transantral ligation of the internal maxillary artery for epistaxis. *Laryngoscope*. 1965;75(7):1151-1159.
10. Snyderman CH, Goldman SA, Carrau RL, Ferguson BJ, Grandis JR. Endoscopic sphenopalatine artery ligation is an effective method of treatment for posterior epistaxis. *Am J Rhinol*. 13(2):137-140.
11. Abdelkader M, Leong SC, White PS. Endoscopic control of the sphenopalatine artery for epistaxis: long-term results. *J Laryngol Otol*. 2007;121(8):759-762.
12. Nouraei SAR, Maani T, Hajioff D, Saleh HA, Mackay IS. Outcome of endoscopic sphenopalatine artery occlusion for intractable epistaxis: a 10-year experience. *Laryngoscope*. 2007;117(8):1452-1456.
13. Minni A, Dragonetti A, Gera R, Barbaro M, Magliulo G, Filippo R. Endoscopic management of recurrent epistaxis: the experience of two metropolitan hospitals in Italy. *Acta Otolaryngol*. 2010;130(9):1048-1052.
14. Soyka MB, Nikolaou G, Rufibach K, Holzmann D. On the effectiveness of treatment options in epistaxis: an analysis of 678 interventions. *Rhinology*. 2011;49(4):474-478.
15. Howe DJ, Wazir U, Skinner DW. Outcomes of endoscopic sphenopalatine artery ligation for epistaxis: a five-year series from a single institution. *Ear Nose Throat J*. 2012;91(2):70-72.
16. Moorthy R, Anand R, Prior M, Scott PM. Inferior turbinate necrosis following endoscopic sphenopalatine artery ligation. *Otolaryngol Head Neck Surg*. 2003;129(1):159-160.
17. Elsheikh E, El-Anwar MW. Septal perforation and bilateral partial middle turbinate necrosis after bilateral

sphenopalatine artery ligation. *J Laryngol Otol.* 2013;127(10):1025-1027.

18. Gras-Cabrerizo JR, Ademá-Alcover JM, Gras-Albert JR, et al. Anatomical and surgical study of the sphenopalatine artery branches. *Eur Arch Oto-Rhino-Laryngology.* 2013;271(7):1947-1951.

19. Wareing MJ, Padgham ND. Osteologic classification of the sphenopalatine foramen. *Laryngoscope.* 1998;108(1 Pt 1):125-127.

20. Lin G, Bleier B. Surgical Management of Severe Epistaxis. *Otolaryngol Clin North Am.* 2016;49(3):627-637.

21. Sokoloff J, Wickbom I, McDonald D, Brahme F, Goergen TC, Goldberger LE. Therapeutic percutaneous embolization in intractable epistaxis. *Radiology.* 1974;111(2):285-287.

22. Lasjaunias P, Marsot-Dupuch K, Doyon D. The radio-anatomical basis of arterial embolisation for epistaxis. *J Neuroradiol.* 1979;6(1):45-53.

23. Seidel DU, Remmert S, Brassel F, Schlunz-Hendann M, Meila D. Superselective microcoil embolization in severe intractable epistaxis: an analysis of 12 consecutive cases from an otorhinolaryngologic and an interventional neuroradiologic point of view. *Eur Arch Otorhinolaryngol.* 2015;272(11):3317-3326.

24. Christensen N, Smith D, Barnwell S, Wax M. Arterial Embolization in the Management of Posterior Epistaxis. *Otolaryngol - Head Neck Surg.* 2005;133(5):748-753.

25. Willems PWA, Farb RI, Agid R. Endovascular Treatment of Epistaxis. *Am J Neuroradiol.* 2009;30(9):1637-1645.

26. Villwock JA, Goyal P. Early versus delayed treatment of primary epistaxis in the United States. *Int Forum Allergy Rhinol.* 2014;4(1):69-75.

27. Rudmik L, Leung R. Cost-effectiveness Analysis of Endoscopic Sphenopalatine Artery Ligation vs Arterial Embolization for Intractable Epistaxis. *JAMA Otolaryngol Neck Surg.* 2014;140(9):802.

28. Leung RM, Smith TL, Rudmik L. Developing a Laddered Algorithm for the Management of Intractable Epistaxis. *JAMA Otolaryngol Neck Surg.* 2015;141(5):405.

29. Ortiz JM, Bhattacharyya N. Management pitfalls in the use of embolization for the treatment of severe epistaxis. *Ear Nose Throat J.* 2002;81(3):178-183.


[Back to top](#)

---

## QUALITY IMPROVEMENT COMMITTEE REPORT

Luke Rudmik, MD MSc FRCSC

For many decades, health care systems focused on reducing medical errors as the primary strategy to improve quality of care<sup>1</sup>. However, in 2001, the Institute of Medicine (IOM) published a landmark article titled "Crossing the Quality Chasm: A New Health Care System for the 21st Century"<sup>2</sup> which highlighted that patient safety was only one piece of a very large health care quality puzzle and emphasized the need to improve other quality domains such as effectiveness, timeliness, equity, and efficiency of care. Since then, most health care systems have invested large amounts of resources to measure quality as a prerequisite to taking steps to improve quality of care. Therefore, it is important for surgeons and surgical societies not only to understand the implications of quality measurement,



but also to be active participants in the development of appropriate quality improvement (QI) strategies. Failure of a clinical specialty or society to become involved with QI will ultimately leave important clinical decisions in the hands of other stakeholders that may have conflicting goals and objectives, and this may result in unintentional negative impact how we provide care to patients. This reality was the impetus behind the development of the Quality Improvement Committee for the American Rhinologic Society (ARS).

The ARS is dedicated to the promotion of excellence in the care of patients with diseases of the nose, sinuses and skull base through research, education, and advocacy. With the enactment of the Affordable Care Act, law now mandates the development of a core set of health quality and performance measures to improve the quality of care while at the same time reduce costs (Title III; Part II; Sections 3011 to 2015). The Merit-based Incentive Payment System (MIPS) enacted under the Medicare Access and CHIP Reauthorization Act of 2015 (MACRA) requires that physicians be scored on quality measures, cost, advancing care information, and clinical practice improvement activities. However, the manner in which physicians caring for diseases of the nose and paranasal sinuses will be scored and the metrics utilized remains undetermined. Members of the ARS have the clinical and research expertise to lead and to assist other health care stakeholders to develop, to implement, and to monitor patient-centered initiatives focused on QI for managing diseases of the nose and paranasal sinuses.

The QI Committee of the ARS was developed to function as a bridge between the ARS Board of Directors (BOD) and other important stakeholders in health care, such as the American Academy of Otolaryngology – Head and Neck Surgery (AAO-HNS), third party payers, policy makers, industry, and patients. The purpose is to ensure that strategies to improve quality of care are appropriately developed, communicated, and implemented in a manner that is aligned with the overarching objectives of the ARS.

Given the implications of QI on how members of the ARS provide patient care, the QI committee understands the importance of being transparent when representing ARS perspective. Therefore, important studies, reports, and reviews developed from the QI committee will be submitted to both the ARS BODs and the official journal of the ARS (International Forum of Allergy and Rhinology) for peer review. The purpose of this peer review process is not only to improve the integrity of published articles but also to improve the dissemination of important information to the ARS membership. As of September 2017, the QI committee has published two articles.

The first article is titled “Rhinology-specific Priority Setting for Quality Improvement” and focused on developing a prioritized list of rhinologic diseases for QI from the perspective of the ARS.<sup>3</sup> Given that there are large costs associated with quality measurement,<sup>4</sup> rhinology-specific QI initiatives should focus on diseases that will have the largest positive impact on health system performance. The results from this study demonstrated that the top three rhinologic diseases for QI were: chronic rhinosinusitis (CRS), recurrent acute rhinosinusitis, and sinonasal neoplasms. Although this study provides helpful information to guide rhinology-specific QI, there are several important points to consider when interpreting the outcomes. First, the rankings for the importance of QI was performed from the perspective of the subspecialty of rhinology and took into consideration the likelihood of other clinical specialties leading QI initiatives for each disease category (such as the American Academy of Allergy Asthma & Immunology leading QI initiatives for allergic rhinitis and asthma). Secondly, the priority rankings from this study reflected the perspective of the ARS and may not accurately reflect the same priorities of other otolaryngology or rhinology societies from various geographic regions such as Europe or Asia. Lastly, the prioritized list of diseases developed from this study are meant to provide an evidence-based guide for QI initiatives and do not imply that lower prioritized diseases are unimportant and/or not worth improving quality of care. This list is simply meant to assist in focusing initial efforts for QI toward diseases that are felt to carry the highest value for members of the ARS.

The second study published by the QI committee is titled “Quality Measurement for Rhinosinusitis” and focused on reporting the current state of quality measurement for management of both acute bacterial rhinosinusitis (ABRS) and CRS.<sup>5</sup> The results from this review demonstrated that the majority of quality measurement is focused on process measures assessing the appropriateness of ABRS management, such as the decision to prescribe an antibiotic and choice of antibiotic. There were several important gaps in quality measurement that were identified. First, there is a dearth of quality measurement for CRS with only one metric being actively collected by the Physician Quality Reporting System (PQRS) (more than one CT obtained within 90 days of first diagnosis). Other gaps in quality measurement for rhinosinusitis included the lack of outcome-based quality metrics and lack of metrics that assess other quality domains such patient-centeredness and timeliness of care. Given the high prevalence and large practice variation for both ABRS and CRS, it is important for the ARS to work with other stakeholders to design appropriate quality metrics that can translate into improved quality of care.

The QI committee is currently working on several projects focused on assisting clinicians with providing high-quality care to patients with CRS. Specifically, we are working to finalize a project that defines key preoperative quality metrics while focusing on the diagnosis, treatment, and counselling of patients with uncomplicated refractory adult CRS. The goal of this project is to ensure that most patients are receiving consistent high quality pre-operative care that involves appropriate use of medical therapies and surgery along with optimizing shared-decision making. In addition to the CRS appropriate preoperative care protocol, the QI committee is working to build collaborations with several other stakeholders in health care, such as the American Academy of Otolaryngology – Head and Neck Surgery, with the shared purpose to further advance the quality of

rhinologic care.

In conclusion, the QI committee is focused on representing the ARS membership during a rapidly evolving QI landscape. Failure to work with other stakeholders during the development of rhinologic QI initiatives may result in decisions that do not reflect the perspective of the ARS and that may have a negative impact on the care of patients with diseases of the nose, sinuses, and skull base. Using the guiding principles that care should be patient-centered and reflect best-available evidence, the QI committee is fully dedicated to working on behalf of the ARS to advocate that future QI initiatives are appropriate and minimize negative consequences to its membership.

1. Medicine Io. To Err Is Human: Building a Safer Health System. Washington, DC: The National Academies Press, 2000.
2. IOM: Crossing the Quality Chasm (Committee on Quality of Health Care in America). Washington: National Academy Press, 2001.
3. Rudmik L, Mattos JL, Stokken JK et al. Rhinology-specific priority setting for quality improvement: a modified Delphi study from the Quality Improvement Committee of the American Rhinologic Society. International forum of allergy & rhinology 2017.
4. Schuster MA, Onorato SE, Meltzer DO. Measuring the Cost of Quality Measurement: A Missing Link in Quality Strategy. *Jama* 2017.
5. Rudmik L, Mattos J, Schneider J et al. Quality measurement for rhinosinusitis: a review from the Quality Improvement Committee of the American Rhinologic Society. International forum of allergy & rhinology 2017; 7:853-860.

[Back to top](#)

---

## CASE OF THE QUARTER: INTRANASAL DRUG ABUSE WITH COMBINED ACETAMINOPHEN/OPIOID PRESCRIPTION MEDICATIONS

Bobby A. Tajuddin, MD

### Case Description:

A 25-year old male with a history of intranasal drug use presented with a complaint of persistent nasal congestion, obstruction, postnasal discharge, anosmia and severe facial pain. His history of intranasal drug use included combined opioid/acetaminophen medications. Examination was notable for a stiffened, fibrotic appearing soft palate with copious postnasal discharge and poor dentition (**Figure 1**). Nasal endoscopy showed a large septal perforation with a central conglomerate of white debris (**Figure 2**). A fine-cut CT revealed bilateral pansinusitis, a large defect involving the nasal septum, and erosive changes of the posterior hard palate and inferior turbinates (**Figure 3**). He was urgently taken to the operating room for removal of the dense debris and bilateral sinus surgery. Intraoperatively, the palate was fibrotic and inferior turbinates completely eroded. The middle turbinates had fused to the septum and lateral nasal wall causing complete sinus obstruction bilaterally. Histopathology revealed chronic sinusitis with fibrosis and basement membrane thickening. Budding yeast were present without evidence of invasive fungal disease. Fungal cultures grew *Aspergillus fumigatus* and *Candida albicans*. He did well after surgery with improvement in nasal symptoms with widely patent sinuses. He continued to have debilitating facial pain and required multidisciplinary care for his pain and addiction.

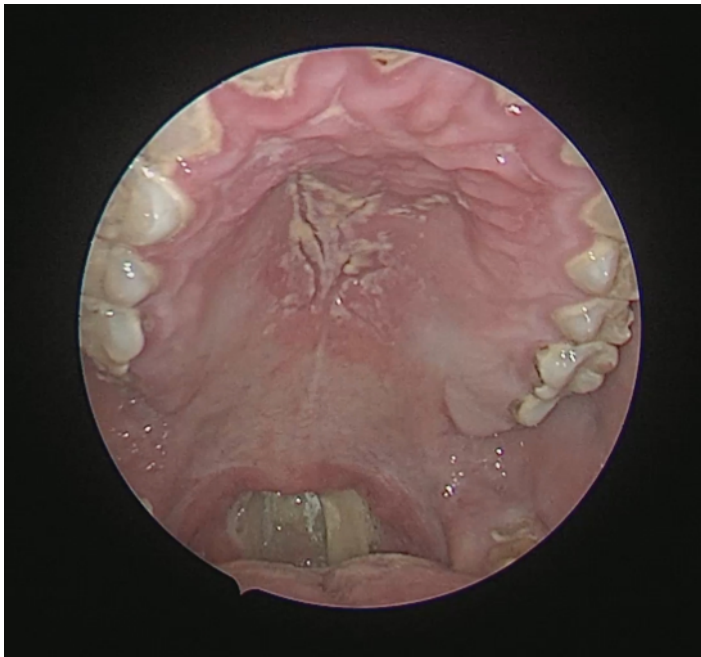
### Discussion:

Intranasal abuse of prescription combined acetaminophen-opioid medications (COAMs) have been a growing problem in the United States. Several case reports and small series in the literature have characterized the deleterious complications of intranasal abuse of COAMs.<sup>1-8</sup> Presenting symptoms include intractable nasal pain in nearly 100% of patients, nasal congestion (86%), dysphagia, otalgia, and dysphonia.<sup>7</sup> Endoscopic examination findings may include severe inflammation, copious white fibrinous material, necrotic tissue and septal/palatal perforation.

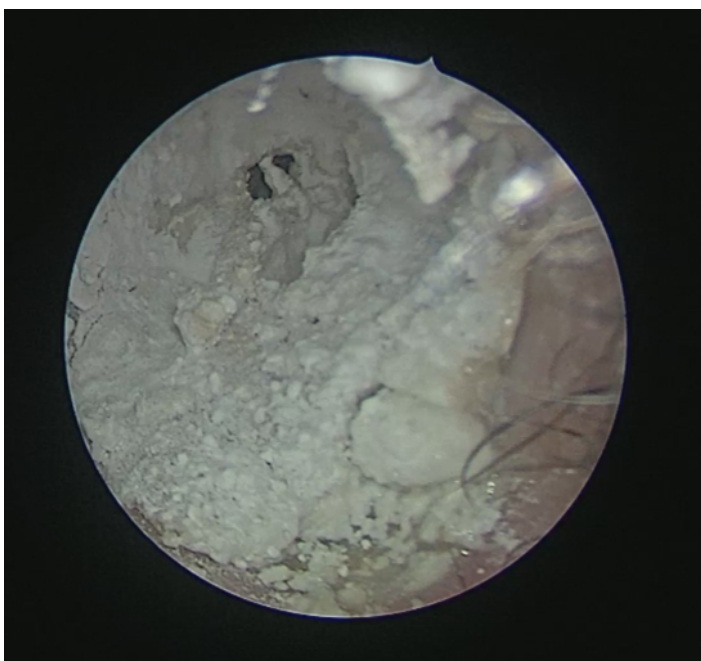
Historically, intranasal drug abuse was once limited entirely to cocaine. The mechanism of destruction is well described and attributed to the vasoconstrictive effects of cocaine. Less is known about the mechanism of tissue destruction in COAMs. The leading hypothesis presumes the process to be due to vasculitis induced by

drug formulation additives, most notably the binding agent talc. Talc is hydrated magnesium silicate crystal that is notable to cause pulmonary disease characterized by robust foreign body giant cell reaction resulting in the formation of polarizable birefringent crystals.<sup>9</sup> In the largest series characterizing pathologic characteristics of intranasal abuse of COAMs, Volser et al noted 57% of nasal specimens to contain birefringent crystals on histology providing additional support for this theory.<sup>7</sup>

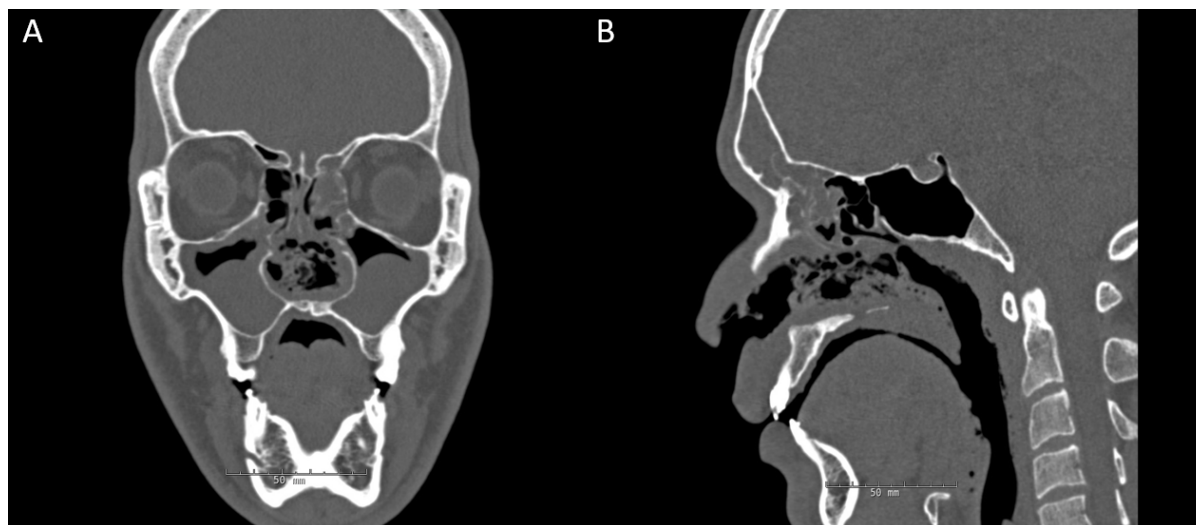
Prompt and precise diagnosis is critical in order to provide appropriate counseling and treatment. Laboratory workup should rule out vasculitides. CT imaging is critical to assess the degree of tissue destruction and concomitant sinonasal disease. Surgical treatment includes surgical debridement of fibrinous and necrotic tissue, and functional endoscopic sinus surgery to address sinus disease if present such as in the case presented. Although fungal elements are seen in greater than 85% of patients, this is presumed to be due to superficial fungal colonization of necrotic and inert material and antifungal therapy does not provide benefit.<sup>7</sup> Care should be taken in immunocompromised patients to rule out the potential for invasive fungal disease. Above all, optimal treatment requires abstinence from intranasal drug use and close multi-disciplinary follow up with pain and addiction specialists.



**Figure 1.** Intraoral examination demonstrating copious postnasal discharge, thickened palate and poor dentition.



**Figure 2.** Nasal endoscopy showing large conglomerate of white debris and septal perforation due to intranasal abuse of combined opioid/acetaminophen medication.



**Figure 3.** (A) Coronal CT imaging demonstrating bilateral pansinusitis and destruction of the nasal septum and inferior turbinates. (B) Erosive change of the posterior hard palate is noted on sagittal imaging.

#### REFERENCES:

1. Alexander D, Alexander K, Valentino J. Intranasal hydrocodone-acetaminophen abuse induced necrosis of the nasal cavity and pharynx. *Laryngoscope*. 2012;122(11):2378-2381.
2. Birchenough SA, Borowitz K, Lin KY. Complete soft palate necrosis and velopharyngeal insufficiency resulting from intranasal inhalation of prescription narcotics and cocaine. *J Craniofac Surg*. 2007;18(6):1482-1485.
3. Greene D. Total necrosis of the intranasal structures and soft palate as a result of nasal inhalation of crushed OxyContin. *Ear Nose Throat J*. 2005;84(8):512, 514, 516.
4. Hardison SA, Marcum KK, Lintzenich CR. Severe necrosis of the palate and nasal septum resulting from intranasal abuse of acetaminophen. *Ear Nose Throat J*. 2015;94(10-11):E40-42.
5. Jewers WM, Rawal YB, Allen CM, et al. Palatal perforation associated with intranasal prescription narcotic abuse. *Oral Surg Oral Med Oral Pathol Oral Radiol Endod*. 2005;99(5):594-597.
6. Sloan PA, Klimkina O. Intranasal abuse of prescription hydrocodone/acetaminophen results in oronasal fistula: a case report. *J Opioid Manag*. 2009;5(6):383-385.
7. Vosler PS, Ferguson BJ, Contreras JI, Wang EW, Schaitkin BM, Lee S. Clinical and pathologic characteristics of intranasal abuse of combined opioid-acetaminophen medications. *Int Forum Allergy Rhinol*. 2014;4(10):839-844.
8. Yewell J, Haydon R, Archer S, Manaligod JM. Complications of intranasal prescription narcotic abuse. *Ann Otol Rhinol Laryngol*. 2002;111(2):174-177.
9. Siddiqui MF, Saleem S, Badireddi S. Pulmonary talcosis with intravenous drug abuse. *Respir Care*. 2013;58(10):e126-128.

[Back to top](#)

## FRIENDS IN RESEARCH CAMPAIGN

We want to express our sincere thanks for the generous donations to the 2017 ARS Friends in Research Campaign.

With your support, we can continue to fund the studies that provide clinical insights valuable to the care of our patients. In the past, these efforts have helped to establish the ARS and its members as the leaders in



rhinologic research. This work not only advances the care of our patients through scientific innovation, but also generates important data establishing the efficacy and cost effectiveness of our care. In the current financial landscape, this is equally important to ensure that our patients have access to the treatment necessary to address their complaints. If you are interested in donating to the ARS, please visit <https://www.american-rhinologic.org/donate>.

We thank you again for your help in this worthy endeavor.

**2017 FRIENDS IN RESEARCH FUND SUPPORTERS\***

**Diamond**

Anonymous

**Platinum**

Roy Casiano, MD  
 John Del Gaudio, MD  
 Joseph Han, MD  
 Peter Hwang, MD  
 Robert Kern, MD  
 Stil Kountakis, MD  
 Jivianne Lee, MD  
 Lee Mandel, MD  
 James Palmer, MD  
 Spencer Payne, MD  
 David Poetker, MD  
 Doug Reh, MD  
 Marc Rosen, MD  
 Rodney Schlosser, MD  
 Michael Sillers, MD  
 Tim Smith, MD  
 Michael Stewart, MD  
 Eugenia Vining, MD  
 Marilene Wang, MD  
 Sarah K. Wise, MD

**Gold**

Jeremiah Alt, MD  
 Pete Batra, MD  
 Rick Chandra, MD  
 Do Yeon Cho, MD  
 Charles Ebert, MD  
 Stacey Gray, MD  
 John Houck, MD  
 Andrew Lane, MD  
 Peter Manes, MD  
 Richard Orlandi, MD  
 Murugappan Ramanathan, Jr. MD  
 Belachew Tessema, MD  
 Jonathan Ting, MD  
 Bozena Wrobel, MD

**Silver**


Jastin Antisdel, MD  
 Noam Cohen, MD  
 Stephanie Joe, MD  
 Douglas O'Brien, MD  
 Shawn Allen, MD  
 Gary Snyder, MD  
 Elina Toskala-Kennedy, MD

**Bronze**

Nadeem Akbar, MD  
 Greg Davis, MD  
 Neto Deusdedit, MD  
 Francisca Fernandez, MD  
 Rohit Garg, MD  
 Suman Golla, MD  
 Corinna Levine, MD  
 Loring Perry, MD  
 Inell Rosario, MD  
 Stephanie Smith, MD  
 Ron Swain, Jr  
 Jay Yates, MD

**Friend**

Saad Alsaleh, MBBS  
 Mark Capener, MD  
 Carlos Chone, MD  
 Perrin Clark, MD  
 Steven Davis, MD  
 Elizabeth Duncan, MD  
 Ashleigh A. Halderman, MD  
 John B. Jiu, MD  
 Garrison Morin, MD  
 Jeffrey Myhill, MD  
 Michael Platt, MD  
 Daniel Sommerz Best, MD  
 Elizabeth Willingham, MD



\* as of Oct 25, 2017

[Back to top](#)

**PATIENT ADVOCACY COMMITTEE REPORT**


Seth M. Brown, MD, MBA FARS

This is a follow up from the last Nose News in which we discussed the revaluation of sinus codes. These changes were recently presented for comment by CMS. This article summarizes some of the key points. It is important to note that these changes, however, will not be finalized until CMS releases its Final Rule.

As of January 2018, there will be several new sinus codes as well as reevaluation of some of the existing codes.

New for 2018 is a code for endoscopic sphenopalatine ligation. This code will have similar value to the current value of the endoscopic frontal sinus surgery code.

There will also be combined codes for sinus surgery. Moving forward we will be required to use the bundled codes when a sphenoidotomy or frontal sinusotomy is performed with an ethmoidectomy. There is also going to be a bundled code when a frontal balloon dilation is done in conjunction with a sphenoid balloon dilation.



Epistaxis codes were also reviewed, and it is anticipated that these will not change in value.

Most surgical endoscopic sinus codes are going down in value however. These are planned to decrease in work value between 10-25%, depending on the specific code.

There is also a slight change in the work value for balloon sinus dilation codes; for the most part, however, these will be similar.

Lastly, there will be a slight reduction in the value of code 30140, submucosal resection of inferior turbinates. This will also change from a 90-day global period to a 0-day global period.

Further information will likely be available shortly, including recommendations on coding sinus surgery with the advent of the combined codes.

The American Rhinologic Society is committed to informing our members and dealing with coding and reimbursement issues affecting our membership. As a result we have engaged a consultant to help with this. Please contact the ARS directly for any coding and reimbursement issues so we can do our best to inform our membership and support their efforts.

[Back to top](#)

---

## CORPORATE SUPPORTERS: THANK YOU

The American Rhinologic Society would like to express our deepest thanks and appreciation to the participants of our Corporate Partners Program. Our corporate partnerships have been invaluable in their support of ARS initiatives to promote excellence in rhinology and skull base surgery. Through our ongoing collaborative relationships, we hope to continue to mutually develop exciting and lasting opportunities for our members to enhance education, investigation, clinical care, and patient advocacy in the future.

---

## PLATINUM

# Medtronic





Your Vision, Our Future

GOLD

---



SILVER

---



BRONZE

---



## ARS OFFICERS

**Richard Orlandi, MD**  
President  
**James Palmer, MD**  
President-Elect  
**Joseph Jacobs, MD**  
Executive Vice President  
**Robert Kern, MD**  
First Vice President  
**Joseph Han, MD**  
Second Vice President  
**Pete Batra, MD**  
Secretary  
**Rodney Schlosser, MD**  
Treasurer  
**John DelGaudio, MD**  
Immediate Past President

## BOARD OF DIRECTORS

Subinoy Das, MD  
Deyani Lal, MD  
David Poetker, MD  
Douglas Reh, MD  
Raj Sindwani, MD  
Kevin C Welch, MD

## CONSULTANTS TO THE BOARD

Noam Cohen, MD  
David Conley, MD  
Amber Luong, MD  
K. Chris McMains, MD

## NOSENEWS EDITOR

R. Peter Manes, MD

## ADMINISTRATOR

Wendi Perez  
PO Box 269  
Oak Ridge, NJ 07438  
Tel: 973-545-2735  
Fax: 973-545-2736  
wendi@amrhso.com

## IN CLOSING

Take a moment to explore the ARS Website where you'll find useful meeting-related information and much more.

### QUICK LINKS

Donate to the ARS

[More Info](#)

ARS Summer Sinus Symposium

[More Info](#)

ARS at AAOHNS

[More Info](#)

ARS at COSM

[More Info](#)