



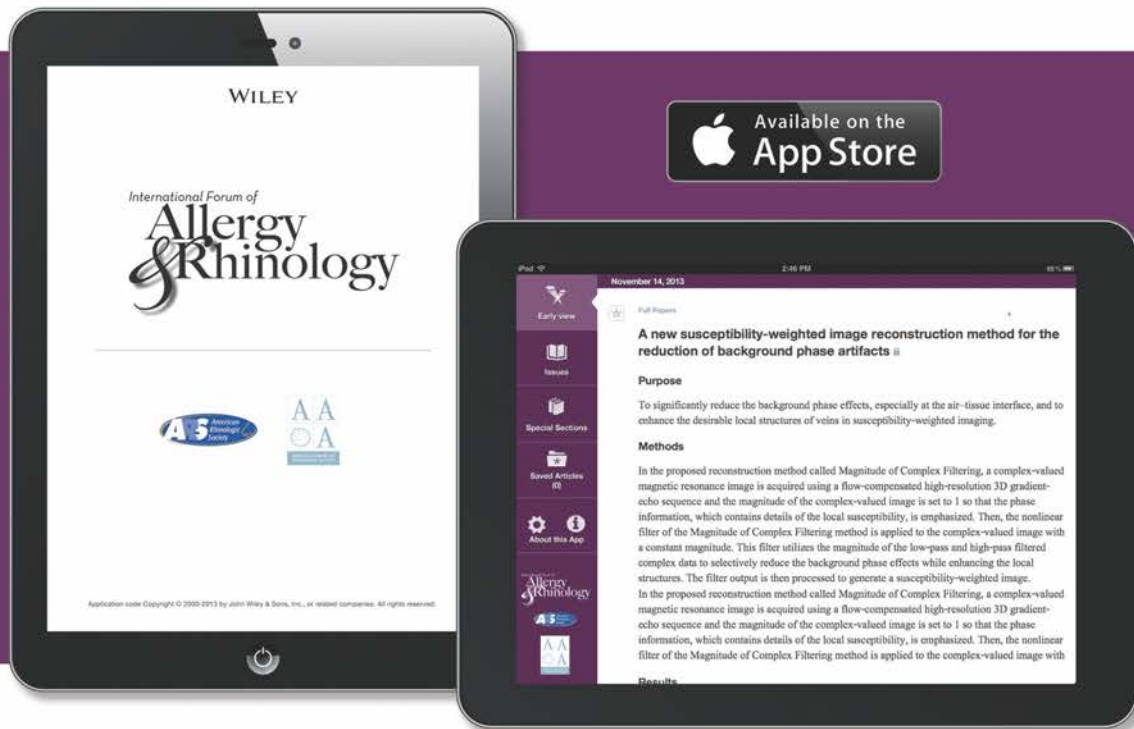
# ARS at AAO 60<sup>TH</sup> ANNUAL MEETING

SEPTEMBER 20, 2014

HYATT REGENCY ORLANDO  
ORLANDO, FLORIDA



# Your invitation to experience the International Forum of Allergy & Rhinology app



## International Forum of Allergy & Rhinology. To Go.

Introducing International Forum of Allergy & Rhinology for the iPad®, iPhone®, and iPod®.

Keep up to date with current research regarding the management of otolaryngic allergy, rhinologic, and skull base diseases.

- Readable, print-like experience enhanced with dynamic figures, tables, and references
- Rapid access to breaking research — Early View articles updated as they publish
- Adjustable text and table sizing with “pinch and zoom”
- Ability to browse content before downloading an issue, and to download issues to read offline
- Email and social media sharing tools
- Links to supplemental material online
- Convenient alerts when new issues are available

Apple, iPad, iPhone, and iPod are trademarks of Apple Inc., registered in the U. S. and other. App Store is a service mark of Apple Inc.

### If your institution subscribes to IFAR, follow the steps below to get access:

- 1 Register to create an account on Wiley Online Library or, if you already have one, log in
- 2 Access Wiley Online Library from your institution's network and log in. If you are off-site and need help getting access to licensed content, contact your librarian
- 3 Visit the roaming access section of “My Profile” and click “Activate Roaming Access”
- 4 Download the International Forum of Allergy & Rhinology app from iTunes
- 5 Launch app from the Newsstand, and follow the steps in the access wizard

Enter your Wiley Online Library account information. For more detailed instructions, visit Journal iPad® App Frequently Asked Questions

Can't Access International Forum of Allergy & Rhinology? Recommend this title to your institutional library.

**ARS Members! Your subscription includes the new app!** Log in with your regular Wiley Online Library log-in to access journal content with the app

**WILEY**



TIM L. SMITH, MD, MPH



## Presidential Welcome to the 60<sup>th</sup> Annual Meeting of the ARS

On behalf of the Board of Directors, it is my great honor and pleasure to welcome you to the 60th Annual Meeting of the American Rhinologic Society in sunny Orlando. Under the direction of Program Chair, Roy Casiano, MD, and his program committee, we hope to offer an exciting, valuable and enjoyable program. Once again, the Kennedy Lecture highlights the Annual Program. This year our esteem colleague and friend, Claus Bachert, MD, will deliver the 10th Annual Kennedy Lecture. A world leader in research in rhinology, Prof. Bachert will share with us his experience studying endotypes in chronic rhinosinusitis. This year's program will also feature informative panels and will showcase ARS research and our flagship journal, the International Forum of Allergy & Rhinology. It is our sincere goal to provide program content that is broad and timely as we recognize the wide array of interests and needs amongst our membership.

I must take a moment to recognize the true generosity our corporate partners in support of our organization and endeavors. It is only through these strong relationships that we are able to realize our goals of excellence in education, training, research, and patient advocacy. On behalf of the entire Board of Directors, I am proud to say that these partnerships are stronger than ever with aligned strategic goals. Please join me in thanking our corporate partners by exploring the exhibits and visiting with them.

I believe this Annual Meeting of the ARS, the 60th in our history, will prove to be our finest yet as an organization. Please enjoy your time in Orlando and welcome to the ARS!

Tim L. Smith, MD, MPH  
President, American Rhinologic Society

P.S. Are you a member of the ARS? If not, please join us in advancing the field by becoming a member at this meeting. Come see me and I can get you set up!



## President-Elect Welcome

### Welcome to the ARS at AAO-HNS Orlando!

I would like to welcome you to the ARS at AAO-HNS Orlando 2014! The ARS is proud to provide an educational program designed for all practicing otolaryngologists and allied health care providers throughout the world. Even if rhinology is a small part of your practice, this meeting is for you. At the ARS, we have worked very hard to arrange a program that has something for everyone. We've developed clinical debates and moderated panels that address the most pressing issues in our field, and a scientific program that is second to none in the world. Our society journal (International Forum of Allergy and Rhinology; IFAR) has continued its rise to the top of peer reviewed journals in otolaryngology, and is read throughout the world.

ROY CASIANO, MD

We especially extend our warmest welcome to this year's guest countries; Brazil, Venezuela, Colombia, and Mexico. Whether you are an American or international otolaryngologist, if this is the first time you have attended an ARS meeting, we hope this will be the first of many ARS meetings you will attend in the future, and encourage your continued involvement with our Society. Don't forget about our other two annual meetings in the spring (at COSM), and the summer (Summer Sinus Symposium). Each has its own unique venue that promises to deliver the highest quality, state-of-the-art, fair and balanced, education programs in rhinology and endoscopic skull base surgery.

Also, we would like to invite you to become a member. For a relatively modest annual fee, you get a number of outstanding benefits, including access to our journal. Please ask our staff if you would like to hear more about becoming an ARS member and its benefits.

It is our sincere hope that there is "something outstanding" in this program for every attendee. Thank you for your continued support of the American Rhinologic Society. Please seek me out and provide me with your critical feedback about the program.

I'll see you at one of our corporate partners' coffee breaks!

**EN ESPAÑOL:** Me gustaría darle la bienvenida a la Sociedad Rinológica Americana en Orlando 2014! El comité científico es de proporcionar un programa educativo diseñado para todos los otorrinolaringólogos en ejercicio y profesionales de la salud aliados en todo el mundo. Incluso si rinología es una pequeña parte de su práctica, esta reunión es para usted. En la Sociedad Rinológica, hemos trabajado muy duro para organizar un programa que tiene algo para todo el mundo. Hemos desarrollado debates clínicos y paneles moderados que abordan las cuestiones más apremiantes en nuestro campo, y un programa científico que no tiene rival en el mundo. Nuestra revista ("International Fórum of Allergy and Rhinology; IFAR) ha continuado su ascenso a la cima de revistas revisadas por pares en otorrinolaringología, y se lee en todo el mundo.

En especial, nos extendemos nuestra más cordial bienvenida a los países invitados de este año; Brasil, Venezuela, Colombia, y México. Si usted es un otorrinolaringólogo estadounidense o internacional, si esta es la primera vez que ha asistido a una reunión de la Sociedad, esperamos que esta será la primera de muchas reuniones que va a asistir en el futuro, y fomentar su participación continua con nuestra Sociedad. No se olvide de las otras dos reuniones anuales en la primavera (en COSM) y el verano (Summer Sinus Simposio). Cada uno tiene su propio lugar único que se compromete a entregar la más alta calidad, actualización en tratamientos y tecnología, y mejor educación en rinología y cirugía endoscópica de la base del cráneo.

También, nos gustaría invitarlo hacerse miembro de la Sociedad Rinológica. Por una cuota anual relativamente modesto, se obtiene una serie de ventajas excepcionales, incluido el acceso a nuestra revista. Por favor pregunte a nuestro personal si usted desea saber más acerca de hacerse un miembro de la Sociedad y sus beneficios.

Es nuestra sincera esperanza de que hay "algo excepcional" en este programa para cada asistente. Gracias por su continuo apoyo a la Sociedad Rinológica Americana. Por favor, me buscará y me dan su opinión crítica sobre el programa.

Nos vemos en unos de los "coffee breaks" con nuestros socios corporativos!

## ARS Executive Committee - 2014



**Timothy Smith, MD**  
*President*  
Oregon Health & Science University  
Oregon Sinus Center  
3181 SW Sam Jackson  
Park Rd PV- 01  
Portland, OR 97239  
Tel: 503-494-7413  
Fax: 503-494-4631  
Email: smithtim@ohsu.edu



**Roy Casiano, MD**  
*President-Elect*  
University of Miami Hospitals  
& Clinics  
1120 NW 14<sup>th</sup> Street  
5th floor, Clinical Research Bldg  
Miami, FL 33136  
Tel: 305-401-7088  
Email: rcasiano@med.miami.edu



**James Palmer, MD**  
*Secretary*  
University of Pennsylvania  
Medical Center  
5 Ravdin, Division of Rhinology  
3400 Spruce Street  
Philadelphia, PA 19104  
Tel: 215-662-7746  
Fax: 215-614-0071  
Email: secretaryars@gmail.com




**Joseph B. Jacobs, MD**  
*Treasurer*  
NYU Medical Center  
345 E. 37<sup>th</sup> Street #306  
New York, NY 10016  
Tel: 646-754-1202  
Fax: 646-754-1222  
Email: joseph.jacobs@nyumc.org



**Peter Hwang, MD**  
*First Vice President*  
801 Welch Road  
Stanford, CA 94305  
Tel: 650-725-6500  
Fax: 650-725-8502  
Email: phwang@ohns.stanford.edu



**John DelGaudio, MD**  
*Second Vice President*  
Emory University  
550 Peachtree Street, NE  
11<sup>th</sup> Floor  
Atlanta, GA 30305  
Tel: 404-778-3381  
Email: jdelgau@emory.edu



**Todd T. Kingdom, MD**  
*Immediate Past President*  
University of Colorado  
School of Medicine  
12631 E. 17<sup>th</sup> Avenue, #B205  
Aurora, CO 80045  
Tel: 303-724-1960  
Fax: 303-724-1961  
Email: todd.kingdom@ucdenver.edu



## Board of Directors



Pete Batra, MD



Michael Stewart, MD



Marc Dubin, MD



Joseph Han, MD



Robert Kern, MD




Jivianne Lee, MD

## Consultants to the Board



Parul Goyal, MD



David Poetker, MD



Kevin Welch, MD



Sarah Wise, MD

## Staff



Wendi Perez  
*Executive Administrator*



Susan Arias  
*Development & Fundraising*



Mary Stahl  
*Administrative Assistant,  
Membership & Committee  
Chair Liaison*



Kathryn Belluci  
*Treasurer's Assistant*



Kathleen Bogie  
*Meetings Assistant*

## Committee Chairs



AUDIT  
Subinoy Das, MD



AWARDS  
David Poetker, MD



BY-LAWS  
Douglas Reh, MD



BUSINESS DEVELOPMENT  
Joseph Jacobs, MD



CME  
Raj Sindwani, MD




EDUCATION  
Rick Chandra, MD



ETHICS  
Mark Zacharek, MD



FELLOWSHIP  
Todd T. Kingdom, MD



INFORMATION  
TECHNOLOGY  
Kevin Welch, MD



INTERNATIONAL  
LIAISON  
Nicholas Busaba, MD



MEMBERSHIP  
Christopher Melroy, MD



NEWSLETTER  
Sarah Wise, MD



PATIENT  
ADVOCACY  
Seth Brown, MD



PEDIATRIC  
RHINOLOGY  
Hassan Ramadan, MD



RESEARCH GRANTS  
Noam Cohen, MD



RESIDENT/FELLOWS  
Belachew Tessema, MD

## Program Committee

Program Chair: Roy Casiano, MD	Justin Turner, MD
Program Committee:	Karen Fong, MD
Abtin Tabaei, MD	Kevin Welch, MD
Adam Folbe, MD	Lori Lemmonier, MD
Adam Zanation, MD	Luke Rudmik, MD
Amber Luong, MD	Mark Tabor, MD
Ameet Singh, MD	Mark Zacharek, MD
Amin Javer, MD	Martin Citardi, MD
Amy Anstead, MD	Michael Stewart, MD
Andrew Lane, MD	Nadeem Akbar, MD
Anne Getz, MD	Nathan Sautter, MD
Ashutosh Kacker, MD	Naveen Bhandarkar, MD
Ayesha Khalid, MD	Nithin Adappa, MD
Belachew Tessema, MD	Noam Cohen, MD
Bruce Tan, MD	R. Peter Manes, MD
Charles Ebert, MD	Ramzi Younis, MD
Devyani Lal, MD	Richard Orlandi, MD
Deya Jourdy, MD	Rodney Schlosser, MD
Erin O'Brien, MD	Sarah Wise, MD
Erin Wright, MD	Seth Brown, MD
Esther Kim, MD	Seth Lieberman, MD
Eugene Chang, MD	Stacey Gray, MD
Gary Josephson, MD	Stella Lee, MD
Greg Davis, MD	Steven Pletcher, MD
J. Pablo Stolovitzky, MD	Timothy Smith, MD
Jacquelynn Corey, MD	Toy Woodard, MD
Jamie Litvack, MD	Vijay Anand, MD
Jastin Antisdell, MD	Vijay Ramakrishnan, MD
Jayakar Nayak, MD	William Collins, MD
Jean Anderson Eloy, MD	Zachary Soler, MD
Jeb Justice, MD	Zara Patel, MD
Jeffrey Suh, MD	Zoukaa Sargi, MD
John Lee, MD	



## ARS Mission Statement

The American Rhinologic Society's mission is to serve, represent and advance the science and ethical practice of rhinology. The Society promotes excellence in patient care, research and education in Rhinology and Skull Base Disorders. The American Rhinologic Society is dedicated to providing communication and fellowship to the members of the Rhinologic community through on-going medical education, patient advocacy, and social programs. The ARS continuing medical education activities serve to improve professional competence, performance, and promote research.

## Business/ACCME

### Continuing Education

#### Accreditation Statement

The American Rhinologic Society (ARS) is accredited by the Accreditation Council for Continuing Medical Education to provide continuing medical education for physicians.

#### Credit Designation Statement

The ARS designates this live activity for a maximum of 8.75 *AMA PRA Category 1 Credits™*. Physicians should claim only the credit commensurate with the extent of their participation in the activity.

## Learning Objectives from Practice Gaps

At the conclusion of this meeting participants will be able to:

1. Discuss the latest information on disease modifying agents available in the management of CRS and associated conditions.
2. Demonstrate an appreciation of developments in surgical techniques and technology used in nasal, sinus, and skull base surgery.
3. Show an appreciation of the postulated etiologies and factors related to disease progression in CRS and current directions of research.

## Past Presidents

1954 - 1955	Maurice H. Cottle, MD*
1955 - 1956	Ralph H. Riggs, MD*
1956 - 1957	Walter E. E. Loch, MD*
1958 - 1959	Kenneth H. Hinderer, MD*
1959 - 1960	Roland M. Loring, MD*
1960 - 1961	Ivan W. Philpott, MD*
1962 - 1963	Raymond I. Hilsinger, MD*
1963 - 1964	H. Ashton Thomas, MD*
1964 - 1965	Carl B. Spath, MD
1966 - 1967	Walter J. Aagesen, MD
1967 - 1968	Richard Hadley, MD*
1968 - 1969	Henry L. Williams, MD*
1970 - 1971	Charles A. Tucker, MD*
1971 - 1972	Pat A. Barelli, MD
1972 - 1973	Gerald F. Joseph, MD
1973 - 1974	Manuel R. Wexler, MD*
1974 - 1975	George H. Drumheiler, MD*
1975 - 1976	Joseph W. West, MD*
1976 - 1977	Albert Steiner, MD*
1977 - 1978	Anthony Failla, MD*
1978 - 1979	Clifford F. Lake, MD*
1979 - 1980	W. K. Locklin, MD
1981 - 1982	Eugene B. Kern, MD
1982 - 1983	Carlos G. Benavides, MD
1983 - 1984	Leon Neiman, MD
1984 - 1985	George C. Facer, MD
1985 - 1986	Larry E. Duberstein, MD
1986 - 1987	Glenn W. Drumheiler, DO
1987 - 1988	Alvin Katz, MD
1988 - 1989	Donald Leopold, MD
1990 - 1991	Pierre Arbour, MD
1991 - 1992	Fred Stucker, MD
1992 - 1993	David W. Kennedy, MD
1993 - 1994	Sanford R. Hoffman, MD
1994 - 1995	Richard J. Trevino, MD
1995 - 1996	Vijay K. Anand, MD
1996 - 1997	Dale H. Rice, MD
1997 - 1998	Michael S. Benninger, MD
1998 - 1999	William Panje, MD
1999 - 2000	Charles W. Gross, MD
2000 - 2001	Frederick A. Kuhn, MD
2001 - 2002	Paul Toffel, MD
2002 - 2003	Donald C. Lanza, MD
2003 - 2004	James A. Hadley, MD
2004 - 2005	Joseph B. Jacobs, MD
2005 - 2006	Michael J. Sillers, MD
2006 - 2007	Howard L. Levine, MD
2007 - 2008	Marvin P. Fried, MD
2008 - 2009	James Stankiewicz, MD
2009 - 2010	Stilianos Kountakis, MD
2010 - 2011	Brent A. Senior, MD
2011 - 2012	Michael Setzen, MD
2012 - 2013	Todd Kingdom, MD

\*Deceased

## Past Secretaries

2013 - present	James Palmer, MD
2009-2012	Peter Hwang, MD
2005-2008	Brent A. Senior, MD
1999 - 2005	Marvin P. Fried, MD
1995 - 1999	Frederick Stucker, MD
1990-1995	Frank Lucente, MD
1985-1990	George Facer, MD
1980 - 1985	Pat A. Barelli, MD
1975 - 1980	Glenn H. Drumhillier, MD
1970 - 1975	Ralph H. Riggs, MD

## Friends in Research Campaign Donors\* - 2014

### Platinum Members

Garrett Bennett, MD  
Roy Casiano, MD  
Michael Cruz, MD  
John DelGaudio, MD  
Karen Fong, MD  
Peter Hwang, MD  
Robert Kern, MD  
Boris Karanfilov, MD  
Todd Kingdom, MD  
Ralph Metson, MD  
Richard Orlandi, MD  
James Palmer, MD  
Douglas Reh, MD  
Michael Rho, MD  
Marc Rosen, MD  
Rodney Schlosser, MD  
Timothy Smith, MD  
James Stankiewicz, MD  
Michael Stewart, MD  
Winston Vaughan, MD  
Eugenia Vining, MD  
Marilene Wang, MD

### Gold Members

Benjamin Bleier, MD  
Rick Chandra, MD  
Noam Cohen, MD  
Charles Ebert, MD  
Berrylin Ferguson, MD  
Eric Holbrook, MD  
Joseph Han, MD  
Ashutosh Kacker, MD  
Kevin Welch, MD  
Sarah Wise, MD

### Silver Members

Ford Albritton IV, MD  
Sanford Archer, MD  
Stephanie Joe, MD  
Chris Melroy, MD  
Hassan Ramadan, MD  
Andrew Reid, MD

### Bronze Members

Jeb Justice, MD

### Friends Members

Stephanie Shintani-Smith, MD

---

For information on the Friends in Research Fund and/or how to support the fund, please contact Wendi Perez, ARS Administrator at [wendi@amrhso.com](mailto:wendi@amrhso.com) or 845-988-1631. \*List updated as of 9/1/14.

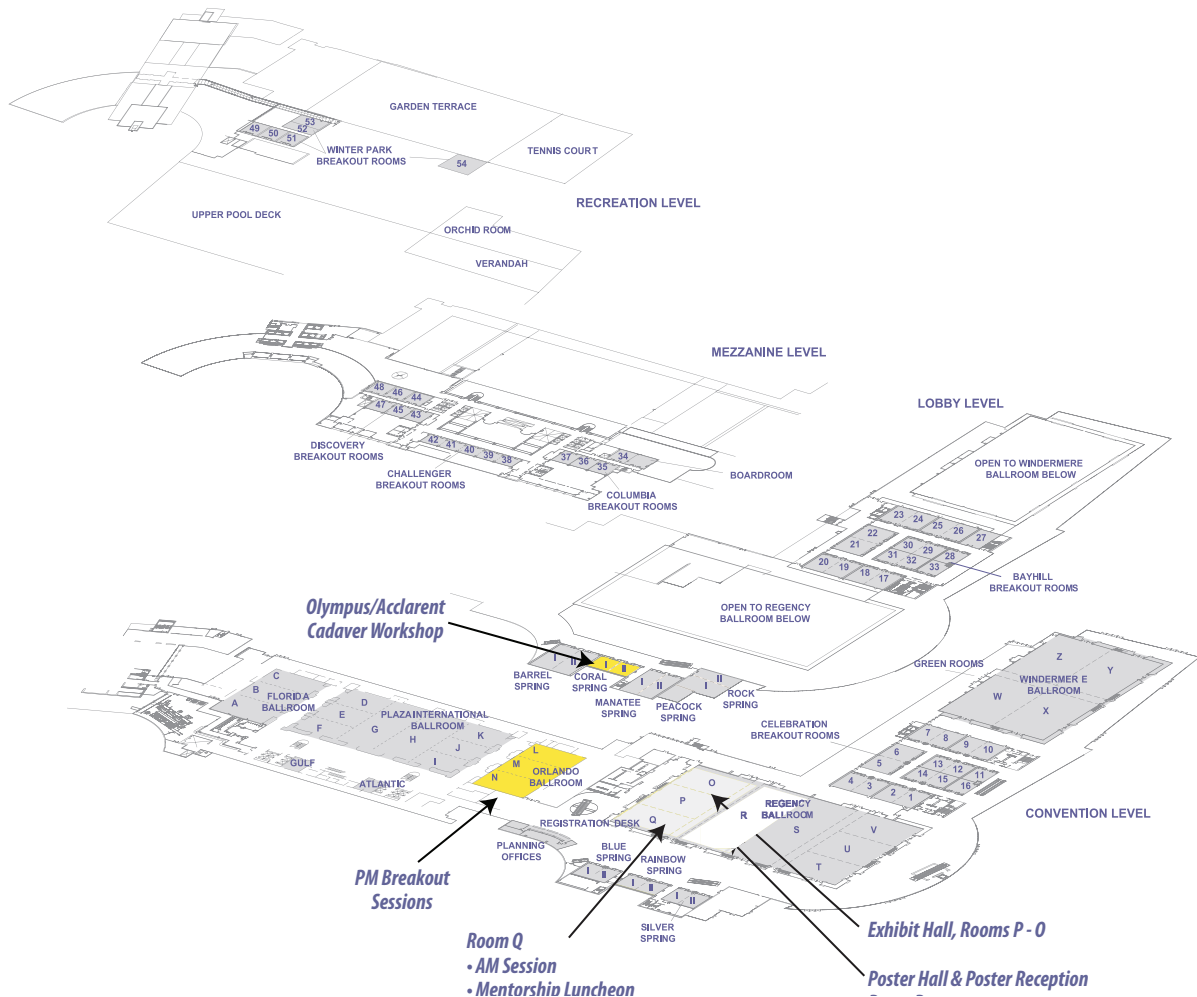


# Hyatt Regency Orlando - Floor Plan

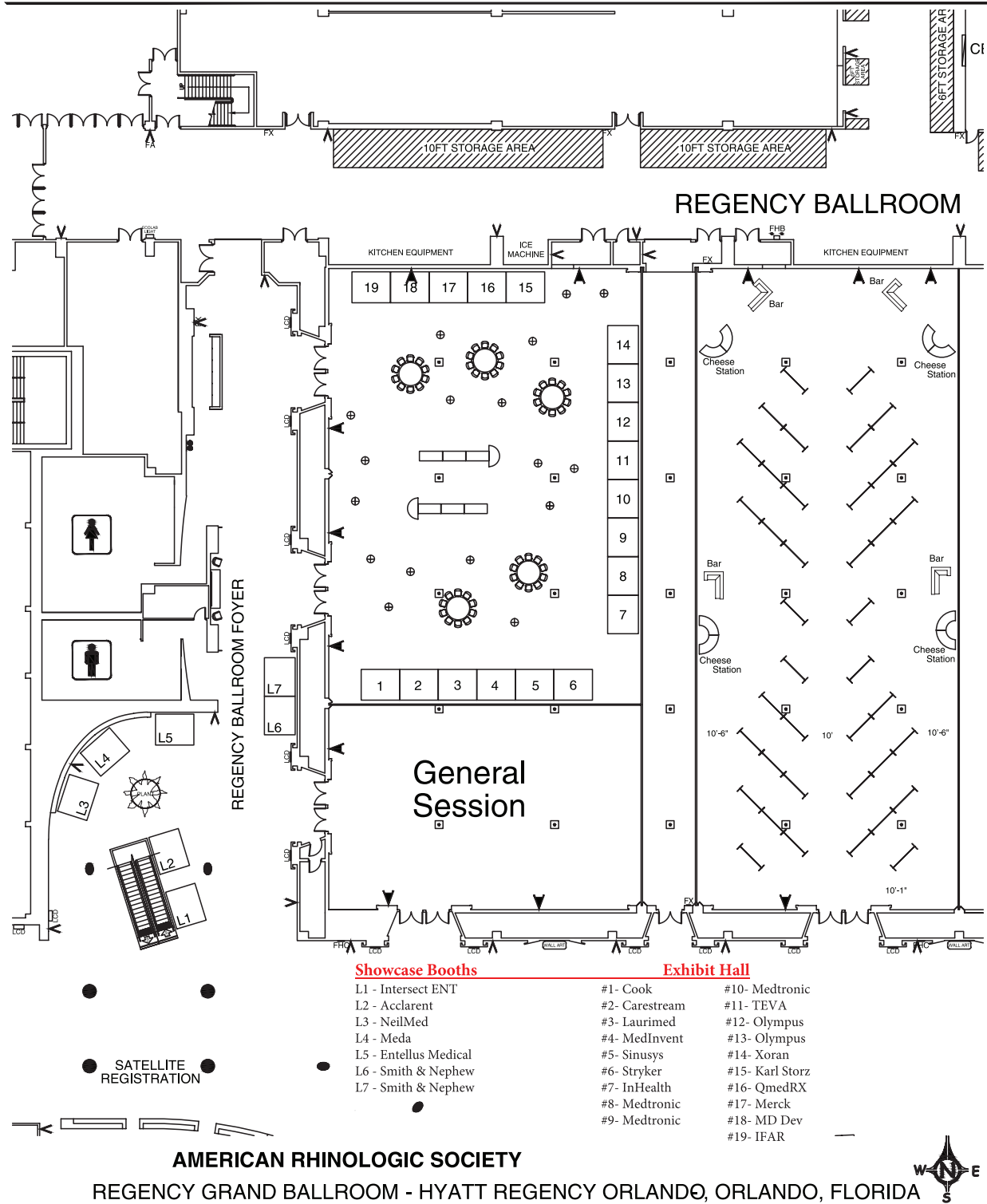
**HYATT REGENCY ORLANDO**  
 9801 International Drive  
 Orlando, FL 32819  
 USA  
  
 T +1 407 284 1234  
 F +1 407 351 0073  
 orlando.regency.hyatt.com



**FLOOR PLAN**  
 3-D Floor Plan



# Hyatt Regency Orlando - Floor Plan







## PROGRAM AT A GLANCE

### FRIDAY, 9/19/14

#### EVENING SESSIONS:

**4:00pm - 9:00pm**

Speaker Ready Room - Gulf Room

**4:30pm - 5:00pm**

**Olympus/Acclarent Office Based Cadaver Workshop**

**Didactic Session**

Coral Springs I & II

**5:00pm - 5:40pm**

**Olympus/Acclarent - Hands on with Acclarent Balloons**

Coral Springs I & II

**5:40pm - 6:00pm**

**Olympus/Acclarent - Hands on with Celon Generator/ Probes**

Coral Springs I & II

### SATURDAY, 9/20/14

#### MORNING SESSIONS:

#### Regency Ballroom Q

**5:00am -2:00pm**

Speaker Ready Room - Gulf Room

**6:55-7:55 AM**

**Olympus Breakfast Symposium**

*Perils and Pitfalls in the Office*

**8:00 AM**

**Welcome** - Roy R. Casiano, MD, FACS, President-Elect and Program Chair

**8:05 AM**

**PANEL: ARS/AOA Combined Session; Allergic Fungal Sinusitis; Is it Really Different?**

Moderator: Sarah K.Wise, MD

Panelists: Joe Han, MD; Matt Ryan, MD; Amber Luong, MD; Rod Schlosser, MD

**8:55 AM**

**Introduction of the 10th Annual Kennedy Lecturer  
The 10th Annual Kennedy Lecture**

Claus Bachert, MD

Endotypes of Chronic Rhinosinusitis and Therapeutic Consequences

**9:25 AM Presidential Address:** Timothy Smith, MD, MPH

**9:40 AM BREAK WITH EXHIBITORS**

**Regency Ballroom P-O**

**10:00 AM**

**PANEL: Rhinology past, present, and future: Emerging Technologies, Promising Medical Therapies, New Directions in Research, and Scope of Practice**

Moderator: Martin Citardi, MD

Panelists: Mike Sillers, MD; Chris Melroy, MD, James Palmer, MD, Winston Vaughan, MD, Amin Javer, MD

**10:40 AM**

**Panel: Pediatric Rhinology: Endoscopic Endonasal Surgery for non CRS Conditions**

Moderator: Fuad Barood MD

Panelists: Ramzi Younis, MD Gary Josephson, MD,MBA William Collins, MD

**11:20 AM**

**PANEL: Rhinology Film FESStival**

Moderator: Stephanie Joe, MD Panelists: Ray Sacks MD Brent Senior MD Martin Citardi MD

**12:00 PM**

**ATTENDEES LUNCH WITH EXHIBITORS**

Regency Ballroom P-O

**12:00-1:00 PM**

**RESIDENTS & FELLOWS IN TRAINING LUNCHEON**

Supported by Meda Pharmaceuticals

Coral Springs Room 1 & 2

***Decision in Residency, Fellowship and after that Affect your Career in Rhinology***

This luncheon program aims to help the decision-making of residents and fellows and prepare them for the path ahead.

The panelists will discuss the decisions that have affected their career in rhinology doing the residency, fellowship and beyond.

Moderator: Belachew Tessema, MD (Resident's & Fellows in Training Committee Chairman); Lori Lemoniere, Associate Professor, University of Louisiana Shreveport; Ayesha Khalid, Associate Professor; Seth Lieberman, Associate Professor, University of New York

**12:00-1:00 PM**

**MENTORSHIP PROGRAM LUNCHEON**

Regency Ballroom Q

**Conflict Management in Rhinology: Strategies for managing difficult patients, thorny colleagues, and challenging clinical situations**

Moderator: Zara Patel, MD

Panelists: Stacey Gray MD, Michael Sillers MD, James Stankiewicz MD, Michael Stewart MD, Eugenia Vining MD  
Come and learn from the collective experience and wisdom of our esteemed panelists, and arm yourself with the necessary skills to deftly maneuver through these inevitable patient and physician encounters:

- How do you manage the unhappy or hostile patient?
- How do you deal with consultants and colleagues who disagree with your patient care plan?
- How do you manage complaints about your office or care team, even if they are unjustified? ...and more!

## SATURDAY, 9/20/14 AFTERNOON SESSION Orlando Ballroom N

### 1:00 PM

Welcome: Michael Stewart, MD,  
Orlando Ballroom N Chairperson

### Session Topic: Novel Surgical Treatments

Moderators: Jean Anderson Eloy, MD,  
Luke Rudmik, MD

### 1:05 PM

Endoscopic Vidian Neurectomy: A Prospective Case  
Series  
Han Zhang, MD

### 1:12 PM

The Effect of Endoscopic Olfactory Cleft Polyp Removal  
on Olfaction  
Arjuna B. Kuperan, MD

### 1:19 PM

Prospective Randomized Trial of Sclerotherapy Verses  
Standard Treatments for HHT Related Epistaxis  
Holly C. Boyer, MD

### 1:26 PM

Nasal Septal Swell Body Ablation for Refractory Nasal  
Obstruction  
David N. Carlson, DO

### 1:33 PM Q&A

### Session Topic: Skull Base and Orbital Surgery

Moderators: Adam Zanation MD, Zoukaa Sargi, MD

### 1:40 PM

Endoscopic Resection of Sinonasal Malignancy- An  
Eighteen Year Experience  
Valerie J. Lund, MD MS

### 1:47 PM

Update on Endoscopic Endonasal Resection of Anterior  
Skull Base Meningiomas  
Jeff Brunworth, MD

### 1:54 PM

Outcomes of Purely Endoscopic Resection of Orbital  
Tumors: A Systematic Review  
Pariket M. Dubal, BA

### 2:01 PM

Endoscopic Direct Vessel Closure in Carotid Artery Injury  
Vikram Padhye, MBBS

### 2:08 PM

Coping with Catastrophe: How Vascular Injury Training  
Improves Patient Outcomes  
Vikram Padhye, MBBS

### 2:15 PM Q&A

### 2:22 PM

#### PANEL: Avoiding Complications during Endoscopic Skull Base Surgery

Moderator: Pete Batra MD  
Panelists: Peter Wormald MD & Valerie Lund MD

### 2:52 PM

**BREAK WITH EXHIBITORS - Regency Ballroom P-O**

### Session Topic: Treatment Outcomes and Quality of Life for Rhinosinusitis

Moderators: Michael Stewart, MD, Zara Patel, MD

### 3:12 PM

Investigation of Change in Cardinal Symptoms of  
Chronic Rhinosinusitis after Surgical or Ongoing Medical  
Management  
Adam S. DeConde, MD

### 3:19 PM

A Prospective Randomized Cohort Study Evaluating  
Three Weeks vs. Six Weeks of Oral Antibiotic Treatment  
in the Setting of "Maximal Medical Therapy" for Chronic  
Rhinosinusitis  
Satyan B. Sreenath, BS

### 3:26 PM

Medical Therapy versus Surgery for Recurrent Acute  
Rhinosinusitis  
Milena L. Costa, MD

### 3:33 PM

Biofilm Formation and Quality of Life Improvement After  
Sinus Surgery  
Zi Zhang, MD, MSCE

### 3:40 PM Q&A

Moderators: Vijay Ramakrishnan MD,  
Seth Lieberman MD

## PROGRAM AT A GLANCE

### 3:47 PM

SNOT-22 Quality of Life Domains Differentially Predict Treatment Modality Selection in Chronic Rhinosinusitis  
Adam S. DeConde, MD

### 3:54 PM

Sleep and Quality of Life Improvements After Endoscopic Sinus Surgery in Patients with Chronic Rhinosinusitis  
Jeremiah A. Alt, MD, PhD

### 4:01 PM

The Impact of Sinus Surgery on Sleep Outcomes  
Brian Rotenberg, MD, MPH

### 4:08 PM

The Impact of Diabetes Mellitus on Outcomes of Endoscopic Sinus Surgery: A Nested Case-Control Study  
Amal Hajjij, MD

### 4:15 PM Q&A

### 4:22 PM

## PANEL: Quality of Life after Sinus Surgery: What Should Patients Expect?

Moderator: Nathan Sautter, MD  
Panelists: Charles Ebert, MD & Zachary Soler, MD

### 4:55 PM

Closing Remarks and Meeting Adjourned

### 5:00-6:30 PM

Advances in Aerosol Therapy for Patients with Allergic Rhinitis (TEVA 4-Corners Symposium)  
Regency Ballroom Q

### 6:30-8:00 PM

ARS President's Wine & Cheese Reception and Presidential Address supported by Intersect ENT  
Regency Ballroom Foyer & Regency Ballroom R

## Exhibit Hall - Regency Ballroom P-O

## SATURDAY, 9/20/14

## AFTERNOON SESSION Orlando Ballroom M

### 1:00 PM

Welcome: Jayakar Nayak, MD,  
Orlando Ballroom M Chairperson

## Session Topic: Innate Immune Alterations in CRS

Moderators: Noam Cohen, MD, Eugene Chang, MD

### 1:05 PM

Cigarette Smoke Exposure is Associated with Vitamin D3  
Jennifer K. Mulligan, PhD

### 1:12 PM

25VD3 as a Novel Regulator of bFGf in Chronic Rhinosinusitis with Nasal Polyposis  
Eugene R. Sansoni, MD

### 1:19 PM

Characterization of IgE Plasma Cells that are Elevated in the Nasal Mucosa of Patients with Chronic Rhinosinusitis (CRS)  
Ali R. Rathan, MD, MS

### 1:26 PM

Mast Cell Deficiency Limits the Development of Chronic Rhinosinusitis in Mice  
Xiaoyang Hua, MD

### 1:33 PM

Pro-inflammatory Mediators Alter Expression of NFKappa B-Regulating Deubiquitinases in Sinonasal Epithelial Cells  
Justin H. Turner, MD, PhD

### 1:40 PM Q&A

## Session Topic: Novel Medical Treatments for CRS

Moderators: Jayakar Nayak, MD, Jeffrey Suh, MD

### 1:47 PM

Acute Inflammation Causes Acquired Defects in Transepithelial Cl<sup>-</sup> Transport  
Jessica W. Grayson, MD

### 1:54 PM

Omeprazole Strongly Inhibits IL-13-induced Eotaxin-3/CCL26 Expression in Human Sinonasal Epithelial Cells  
Jin Y. Min, MD



**2:01 PM**

Verapamil Modulates IL-5, IL-6, and TSLP Secretion in Organotypic Human Sinonasal Polyp Explants  
Benjamin S. Bleier, MD

**2:08 PM**

CFTR Potentiation Reverses Findings of Chronic Sinusitis and Modulates ASL in CF Sinus Epithelia  
Eugene H. Chang, MD

**2:15 PM Q&A****2:22 PM**

### **PANEL: Novel Medical Treatment Strategies for CRS**

Moderator: Andrew Lane, MD  
Panelists: William Bolger, MD & Benjamin Bleier, MD

**2:52 PM*****BREAK WITH EXHIBITORS***

Regency Ballroom P-O

### **Session Topic: Medical Economics**

Moderators: Pablo Stolovitzky MD, Belachew Tessema MD

**3:12 PM**

Developing a Laddered Algorithm for the Management of Intractable Epistaxis: A Risk Analysis  
Randy Leung, MD

**3:19 PM**

Radiographic Evaluation of Nasal Septal Deviation from Computed Tomography Correlates Poorly with Physical Exam Findings  
Regan W. Bergmark, MD

**3:26 PM**

Standardized and "Structured" Pathology Reports Provide Critical Prognostic Information for Chronic Rhinosinusitis Patients Undergoing Endoscopic Sinus Surgery  
Devyani Lal, MD

**3:33 PM**

Long-term Follow Up on Eustachian Tube Balloon Cilation Surgery  
Angela M. Donaldson, MD

**3:40 PM Q&A**

Moderators: Stella Lee, MD, & Seth Brown, MD

**3:47 PM**

Primary Headache Disorder Patients Presenting with "Sinus Headaches" Have Distinct Associations Between SNOT-22 Questionnaire Items and Therapeutic Response  
Devyani Lal, MD

**3:54 PM**

Attitudes on and Usage of Balloon Catheter Technology in Rhinology: A Survey of the American Rhinologic Society  
Ashleigh A. Halderman, MD

**4:01 PM**

The Use of Image-Guidance During Transsphenoidal Pituitary Surgery in the United States  
Thomas K. Chung, MD

**4:08 PM**

What Does Medicare Pay Rhinologists: An Analysis of Medicare Fee-For-Service Data  
Brandon Clair, BA

**4:15 PM Q&A****4:22 PM**

### **PANEL: Finding a Common Ground: New Technological Advancements vs Medical Economics**

Moderator: Devyani Lal, MD  
Panelists: Parul Goyal, MD & Raj Sindwani, MD

**4:55 PM**

Closing Remarks and Meeting Adjourned

**5:00-6:30 PM**

Advances in Aerosol Therapy for Patients with Allergic Rhinitis (TEVA 4-Corners Symposium)  
Orlando Ballroom Q

**6:30-8:00 PM**

**ARS President's Wine & Cheese Poster Reception and Presidential Address supported by Intersect ENT**  
Regency Foyer & Regency Ballroom R

## PROGRAM AT A GLANCE

### SATURDAY, 9/20/14 AFTERNOON SESSION Orlando Ballroom L

#### 1:00 PM

Welcome: Donald Lanza, MD,  
Orlando Ballroom L Chairperson

#### Session Topic: The Microbiome in CRS

Moderators: Lori Lemmonier, MD,  
Troy D. Woodard, MD

#### 1:05 PM

Characterization of Bacterial Microbiome in Chronic Rhinosinusitis Patients at Baseline and During Clinical Exacerbations  
Uma S. Ramaswamy, MD

#### 1:12 PM

Different Clinical Factors Associated With Staphylococcus Aureus and Pseudomonas Aeruginosa in Chronic Rhinosinusitis  
Zi Zhang, MD, MSCE

#### 1:19 PM

Small Colony Variants and Phenotype Switching of Intracellular Staphylococcus Aureus in Chronic Rhinosinusitis  
Neil Tan, MD, PhD

#### 1:26 PM

Cousins, Siblings or Copies: The Genomics of Recurrent Staphylococcus Aureus Infections in Chronic Rhinosinusitis  
Amanda J. Drilling, BBtech (Hons)

#### 1:33 PM Q&A

Moderators: Naveen Bhandarkar, MD,  
Nadeem Akbar, MD

#### 1:40 PM

Gram-Negative Bacterial Carriage in Chronic Rhinosinusitis Is Not Associated With More Severe Inflammation  
Paul Tabet, MS

#### 1:47 PM

Pseudomonas Aeruginosa, but Not Staphylococcus Aureus, Is an Independent Predictor of Neo-Osteogenesis in Patients with Chronic Rhinosinusitis  
Zhenxiao Huang, MD, PhD

#### 1:54 PM

The Effect of Antibiotics on the Microbiome in Acute Exacerbations of Chronic Rhinosinusitis  
Mark A. Merkley, MD, PhD

#### 2:01 PM

The Sinonasal Microbiome in Patients with Cystic Fibrosis  
Alyssa Kanaan, MD

#### 2:08 PM

The Role of Viruses in the Clinical Presentation of Chronic Rhinosinusitis  
Nicholas R. Rowan, MD

#### 2:15 PM Q&A

#### 2:22 PM

#### PANEL: Making Sense of the Sinonasal Microbiome

Moderator: Andy Goldberg, MD  
Panelists: Martin Desrosiers, MD & Richard Douglas, MD

#### 2:52 PM

**BREAK WITH EXHIBITORS**  
Regency Ballroom P-O

#### Session Topic: Genomics and CRS

Moderators: Ashutosh Kacker, MD, Jamie Litvack, MD

#### 3:12 PM

Genetic Variations in the Integrin A6 Gene and Reduced Itga6 Expression Suggest Hemidesmosome Dysfunction in Chronic Rhinosinusitis  
Stefania Gallo, MD

#### 3:19 PM

Familial Risk of Chronic Rhinosinusitis with and without Nasal Polyposis  
Gretchen M. Oakley, MD

#### 3:26 PM

TAS2R38 Genotype Predicts Surgical Outcome in Non-Polypoid Chronic Rhinosinusitis  
Nithin D. Adappa, MD

#### 3:33 PM Q&A

#### Session Topic: Biomaterials

Moderators: Stacey Gray, MD, Adam Folbe, MD

#### 3:40 PM

A Randomized, Controlled, Blinded, Multi-Center Study with Bioabsorbable Steroid-Eluting Sinus Implant for In-Office Treatment of Recurrent Sinonasal Polyposis: 3-Month Safety and Efficacy  
Joseph Han, MD

**3:47 PM**

Topical Colloidal Silver as an Anti Biofilm Agent in Staphylococcus Aureus Chronic Rhinosinusitis Sheep Model  
Sukanya Rajiv, MS

**3:54 PM**

The Effects of Topical Agents on Paranasal Sinus Mucosa Healing: A Rabbit Study  
Ravi Jain, MBChB

**4:01 PM**

Chitosan Does Not Interfere with Normal Wound Healing in Post-Surgical Sinus Cavities  
Mary S. Czerny, MD

**4:08 PM**

Probiotic Instillation Delays Pseudomonas Aeruginosa Induced Sinusitis and Translocation to the Lower Airways in a Murine Model.  
Emily K. Cope, PhD

**4:15 PM Q&A**

**4:22 PM**

**PANEL: Practical Considerations for Biomaterials and Genomics in CRS**

Moderator: Richard Orlandi, MD  
Panelists: Steven Pletcher, MD & David Poetker, MD

**4:55 PM**

Closing Remarks and Meeting Adjourned

**5:00-6:30 PM**

Advances in Aerosol Therapy for Patients with Allergic Rhinitis (TEVA 4-Corners Symposium)  
Orlando Ballroom Q

**6:30-8:00 PM**

**ARS President's Wine & Cheese Poster Reception and Presidential Address supported by Intersect ENT**  
Regency Foyer & Regency Ballroom R







## ORLANDO BALLROOM N

**Welcome:** Michael Stewart, MD  
Orlando Ballroom N Chairperson

### Session Topic: Novel Surgical Treatments

Moderators: Jean Anderson Eloy, MD & Luke Rudmik, MD

1:05pm

#### Endoscopic Vidian Neurectomy: A Prospective Case Series

Han Zhang, MD, Damian Micomnaco, MD, FRCSC, Peter Dziegielewski, MD, FRCSC, Ezkiel Weis, MD, FRCSC, Erin Wright, MDCM, MEd, FRCSC  
Edmonton, AB, Canada

**Objective:** Chronic refractory vasomotor rhinitis (VMR) is a debilitating condition that causes significant impairment of quality of life. The purpose of this study is to investigate the efficacy and potential side effects of endoscopic vidian neurectomy as treatment for patients with VMR

**Design:** Prospective, intent-to-follow case series.

**Methods:** Patients underwent bilateral endoscopic vidian neurectomies via a pteryomaxillary approach. Prior to surgery all patients underwent formal ophthalmologic testing by a single ophthalmologist to quantify pre-operative basal lacrimal function. Ophthalmologic testing was repeated post-operatively at approximately 3 months. Patients also completed surveys regarding rhinologic outcomes including: Sinusitis Symptom Questionnaire (SSQ) VAS and SNOT-22 at time points: Pre-op, 1 week, 4 weeks, 12 weeks, 6 months, 1-year, and 2 years post surgery. Pathological confirmation of nerve section was performed in all cases. Descriptive statistics and ANOVA analysis were undertaken.

**Results:** Eleven patients (22 sides) underwent bilateral endoscopic vidian neurectomy from 2010-2013. Average follow-up is 15.4 (4-24) months. There was statistically significant improvement on SSQ scores at 4-week ( $p=0.0018$ ), 6-months ( $p<0.0001$ ), and 1-year follow-up ( $p<0.0001$ ). SNOT-22 scores at the same follow-up intervals also had statistically significant improvement ( $p<0.05$ ). Subscores for rhinorrhea and nasal congestion were also statistically significantly improved. No incidences of permanent or measureable dry eye/impaired basal secretion rate have been reported.

**Conclusion:** The data suggests that endoscopic vidian neurectomy is an effective, safe and definitive treatment for most patients with vasomotor rhinitis refractory to medical treatment.

1:12pm

#### The Effect of Endoscopic Olfactory Cleft Polyp Removal on Olfaction

Arjuna Kuperan, MD, Deya Jourdy, MD, Seth Lieberman, MD  
Mohammad Al-Bar, MD, Bradley Goldstein, MD, PhD, Roy Casiano, MD  
Miami, FL, USA

**Introduction:** The presence of olfactory cleft polyps is well documented but the effect of endoscopic olfactory cleft polyp surgery, as compared to observation, has never been studied. This analysis assesses if microdebridement of olfactory cleft polyps yields statistically significant objective improvements in smell.

**Methods:** A randomized prospective single-blinded study was performed on patients with profound bilateral nasal polyposis excluding those under 18 or without any polyps in either olfactory cleft during surgery. Patients were given a preoperative UPSIT, SNOT-20, and VAS test, and a follow up at 6 months. Two comparative cohorts were created including a control group and surgical group each with polyps in the olfactory cleft. Complete removal of all other nasal cavity and sinus polyps outside the olfactory cleft was employed in all cases.

**Results:** There were 6 patients in the control group and 8 patients in the surgical arm. Using the Wilcoxon signed-rank test the two groups were individually analyzed for change in the preoperative UPSIT, VAS, and SNOT-20 compared to the 6 month test results. In the control group only the improvement in the VAS was statistically significant at  $p=0.05$ . In the surgical arm the improvement in the VAS, SNOT-20, and UPSIT were all statistically significant at  $p=0.05$ .

**Conclusion:** This study provides early evidence that olfactory cleft polyp surgery improves smell outcomes. More long-term data at 6 and 12 months must be collected to provide further validation of these early promising outcomes that may represent a paradigm shift in the management of olfactory cleft polyps.

1:19pm

#### Prospective Randomized Trial of Sclerotherapy Verses Standard Treatments for HHT Related Epistaxis

Holly Boyer, MD, Patricia Fernandes, DDS MS, Chap Le, PhD, Bevan Yueh, MD  
Minneapolis, MN, USA

**Introduction:** Our previous studies have demonstrated the tolerability and low side effect profile of office-based sclerotherapy with sodium tetradecyl sulfate (STS) for treatment of recurrent epistaxis due to Hereditary

Hemorrhagic Telangiectasia (HHT). The objective of this study was to determine the effectiveness of sclerotherapy compared to other standard treatments for HHT related epistaxis. In this study, standard treatment was defined as continuation of any previous treatments that the patient had undergone, such as moisturization, packing, cauterization, etc., prior to the study.

**Methods:** A prospective randomized trial was performed from 11/1/11 to 2/1/14, on 17 patients with recurrent epistaxis due to HHT. A crossover design was utilized with subjects randomized to either sclerotherapy or current standard treatment during one period of the study and the alternate treatment during the other. The primary outcome was frequency and severity of epistaxis as measured by the Epistaxis Severity Score (ESS).

**Results:** After controlling for the effect of treatment order, which was not significant, the ESS change for the sclerotherapy treatment compared to standard treatment is about one point lower (value -.9476, SE .4547). The difference in treatment effect was statistically significant, (one-sided p-value = .0273). Baseline ESS, number of lesions, moisturization practices, and history of previous blood transfusions did not significantly affect the results.

**Conclusion:** This randomized clinical trial demonstrated that compared to standard treatments, sclerotherapy with STS significantly reduced epistaxis due to HHT as measured by the ESS.

1:26pm

### **Nasal Septal Swell Body Ablation for Refractory Nasal Obstruction**

David Carlson, DO, Brendan Fennessy, MD, Usama Aboelkheir, MD, Peter Catalano, MD  
Brighton, MA, USA

**Introduction:** Anatomic etiologies of nasal obstruction (NO) include septal deviation, turbinate hypertrophy, and nasal valve collapse. We have also noted that the nasal septal swell bodies (NSB) are extremely common and can produce a significant effect on nasal resistance. The aim of our study was to explore changes in validated outcome metrics after surgical reduction of NSB.

**Methods:** Forty-one consecutive patients were enrolled after persistent nasal obstruction following septoplasty, turbinate reduction and valve repair. Clinical history and nasal endoscopy confirmed prominent NSB. Evaluation of treatment was determined by changes in the NOSE scale and a newly developed NSB grading scale before, and two months after swell body ablation in the office-setting with radiofrequency. NSB grades were based on endoscopic visualization of the middle turbinate (MT): 1 = > 50% MT

visualized; 2 = < 50% MT visualized; 3 = no MT visualized. Patient data was scored and transferred for analysis using Prism6 Graph Pad software.

**Results:** Patients (29 M:12 F) exhibited a mean age of 48 years (range 19-71) and were followed for an average 2.5 months. The mean pre-operative NOSE score was 8.32 and mean NSB grade was 3. The mean post-operative NOSE score was 3.90 with NSB grade of 1. Statistically significant improvement in NOSE scores and standardized NSB grading was noted at 2 months post coblation of NSB tissue. There was one asymptomatic septal perforation noted.

**Conclusions:** Coblation reduction of NSB is a safe and very effective new office-based treatment option for the correction of refractory nasal obstruction.

1:33pm

Q & A

## **Session Topic: Skull Base and Orbital Surgery**

Moderators: Adam Zanation, MD & Zoukaa Sargi, MD

1:40pm

### **Endoscopic Resection of Sinonasal Malignancy- An Eighteen Year Experience**

Valerie Lund, MD, MS  
London, UK

**Introduction:** Curative resection of malignant tumours of the skull base is increasingly undertaken endoscopically. Hitherto the diverse histology, rarity and long natural history have made it difficult to accrue statistically robust cohorts for comparison with conventional craniofacial resection. However, it is now possible to make such a comparison in a large personal cohort.

**Method:** Data on all cases of sinonasal malignancy undergoing endoscopic resection with intention to cure over an eighteen year period were collected prospectively and analysed for survival and prognostic factors.

**Results:** There were 140 cases, 75 men and 65 women, aged 20-92 years (mean 63 yrs). Follow-up ranged from 6-216 months (mean 86 months). Fourteen different histopathologies were represented with olfactory neuroblastoma (40), malignant melanoma (37) and adenocarcinoma (23) being the commonest. Additional radiotherapy was given in 98 cases and chemotherapy in 49. Hospital stay was a mean of 5 days with no serious post-operative complications. One hundred and fourteen patients are alive and well, 16 alive with recurrence, 8 dead of disease and 3 have died of intercurrent disease. Thirteen patients have undergone additional endoscopic surgery, 4

## ORLANDO BALLROOM N

have been converted to formal craniofacial resection. Overall crude survival is 91% at 5 years. Overall and disease-free survival at 5 years is respectively 100% and 97.5% for olfactory neuroblastoma, 84% and 72% for adenocarcinoma and 48% and 22% for malignant melanoma.

**Conclusion:** These results show that endoscopic resection is an alternative to conventional craniofacial resection in selected cases providing similar results for similar extent of disease.

1:47pm

### **Update on Endoscopic Endonasal Resection of Anterior Skull Base Meningiomas**

Joseph Brunworth, MD, Ahmed Bassiouni, MBChB, Vikram Padhye, MBBS, Simon Robinson, MBChB, FRACS, Stephen Santoreneos, MBBS, FRACS, Peter John Wormald, MBChB, FCS, FRCS, FRACS  
Woodville South, South Australia, Australia

**Objective:** To report success rates and obstacles in transnasal endoscopic resection of anterior skull base meningiomas.

**Study Design:** Case series with chart review

**Setting:** Tertiary referral centers in South Australia and New Zealand

**Subjects and Methods:** 37 consecutive patients who underwent endoscopic resection of skull base meningiomas between 2004 and 2013. Review of patient charts and operative details were performed.

**Results:** 84% of patients were women. 28 primary and 9 revision cases. Tumor locations: 14 olfactory groove/subfrontal, 12 planum/jugum sphenoidale, 7 tuberculum sellae, 3 clinoidal, and 1 clival. Most common presenting symptom was vision change. Mean tumor volume: 33.68 cm<sup>3</sup>. Mean diameter: 2.78 cm. Primary tumors larger than 60 cm<sup>3</sup> took an average of 10 hours to resect. There were no perioperative deaths. Two deaths occurred within one year of surgery. Postoperative cerebrospinal fluid leaks occurred in 13 patients. Seventy five percent of patients presenting with visual loss reported visual improvement. Gross total removal was achieved in 29 patients. Of these, one had residual disease on a postoperative MRI and another later developed radiological evidence of recurrence.

**Conclusion:** Using a two-team approach, meningiomas of the skull base are successfully removed via an intranasal endoscopic technique. Although complete resection is typically possible even with large tumors, the lengthy resection required time for tumors larger than 60 cm<sup>3</sup> (diameter = 4 cm) may obviate some of the advantages of

this approach. The rate of postoperative CSF leak decreases when a synthetic dural substitute is added but does not approach zero.

1:54pm

### **Outcomes of Purely Endoscopic Resection of Orbital Tumors: A Systematic Review**

Pariket Dubal, BA, Peter Svider, MD, Daniel Denis, BA, Adam Folbe, MD, Jean Anderson Eloy, MD  
Newark, NJ, USA

**Objectives/Hypothesis:** To evaluate outcomes in transnasal endoscopic approaches for the management of extraconal and intraconal orbital tumors.

**Methods:** A systematic review of studies on purely endoscopic orbital tumor resections was conducted using the MEDLINE database. Data extracted and analyzed from selected studies included study type, sample size, demographics, symptomatology, tumor characteristics, complications, follow-up time, and recurrence.

**Results:** Thirty-nine studies were identified and included, containing patient data for 71 cases. Mean patient age was 47 years (range 1-75 years), with 53.5% of patients being male. Primary site of the tumor was orbital in 69.0% of the cases, of which 51.0% were intraconal and 30.6% were extraconal. The most common reported histopathology was cavernous hemangioma (45.1%). Intraoperative complications were reported in 6.3% of cases. Postoperative complications were more common, reported in 32.8% of cases, the majority of which were transient (76.2%). There was no significant difference in post-operative complication rate between intraconal and extraconal primary site tumors ( $p=0.302$ ). Recurrence rate was 5.2%.

**Conclusion:** Purely endoscopic resection of orbital tumors is likely a viable alternative technique to traditional external procedures, with the inherent advantages of minimally invasive surgery. This study of 71 cases represents the largest pooled sample size to date, and the increasing use of endoscopic procedures will allow for future analyses with greater statistical power.

2:01pm

### **Endoscopic Direct Vessel Closure in Carotid Artery Injury**

Vikram Padhye, MBBS, Jae Murphy, MBBS, Peter-John Wormald, MD FRCS FRACS  
Adelaide, SA, Australia

**Background:** Internal carotid artery (ICA) injury represents one of the most challenging management scenarios for the endoscopic skull base surgeon. Current management recommendations result in swift termination of surgery and

can place critical neurovascular structures at risk. Techniques developed through use of an animal model of carotid injury, have shown direct vessel closure techniques to be effective in gaining hemostasis and preventing subsequent complications. The aim of this study was to investigate the effectiveness of the novel 'Anastoclip' Vessel Closure System in ICA injury.

**Methods:** 8 sheep underwent ICA dissection/isolation followed by the artery placement within a modified "sinus model otorhino neuro trainer" (SIMONT) model. Standardised linear injuries were made and treated endoscopically with the 'Anastoclip' device. Specific outcome measures included attainment of primary hemostasis, procedure time, blood loss, pseudoaneurysm formation and carotid patency on follow up MRI.

**Results:** Primary hemostasis was achieved in 100% of cases. No instances of secondary bleeding. Procedure times averaged 7 minutes and 6 seconds. Average blood loss was 75mL. All 8 sheep reached 3 month end point. 7 (88%) showed normal carotid flow on MRI, with 1 case of pseudoaneurysm.

**Conclusions:** Direct vessel closure is an effective endoscopic technique in ICA injury. It allows for visual confirmation of hemostasis, carotid flow and permits the surgeon to continue with surgery despite the complication. The novel design of the 'Anastoclip' can maintain normal vessel patency as well as accommodate pulsatile flow.

2:08pm

#### **Coping with Catastrophe: How Vascular Injury Training Improves Patient Outcomes**

Vikram Padhye, MBBS, Rowan Valentine, MBBS PhD, Raymond Sacks, MBBCh FCS-ORL FRACS, Marc Tewfik, MD MSc FRCS, Dehui Wang, MD, Peter-John Wormald, MD FRCS FRACS  
Adelaide, South Australia, Australia

**Background:** Inadvertent injury to the internal carotid artery (ICA) is the consequence most feared by the endoscopic skull base surgeon. If poorly managed, ICA rupture not only presents a risk of exsanguination but can also result in long-term morbidity. Through the implementation of a novel animal model of endoscopic carotid artery injury, effective techniques to manage this scenario have been developed. The vascular injury workshop has trained over 118 surgeons in these techniques. This study reviews events of major arterial hemorrhage managed by surgeons who completed vascular injury workshop training.

**Methods:** Retrospective multi-center case series of patients who required endoscopic management of major arterial hemorrhage

**Results:** 9 cases reported in total: 3 Male, 6 Female. Age range 18-82 years. 1 basilar artery, 8 ICA injuries. Each managed successfully with intraoperative muscle patch application. No deaths, 1 case of pseudoaneurysm with successful endovascular treatment, 1 case of impaired carotid flow. No permanent neurological sequelae or other permanent morbidity.

**Conclusion:** The vascular injury workshop arms surgeons with a structured approach to managing the surgical field and provides effective hemostatic techniques in the face of impending catastrophe. Existing literature reports 89 cases of ICA rupture, with mortality rate of 15%, permanent neurological sequelae in 40% and permanent morbidity rate of 26%. In comparison, our results show trained surgeons achieve vastly superior outcomes for their patients.

2:15pm

Q&A

2:22pm

#### **Panel: Avoiding Complications during Endoscopic Skull Base Surgery**

Moderator: Pete Batra, MD

Panelists: Peter John Wormald, MD & Valerie Lund, MD

2:52pm

**Break with Exhibitors**

Regency Ballroom P-O

#### **Session Topic: Treatment Outcomes and Quality of Life for Rhinosinusitis**

Moderators: Michael Stewart, MD & Zara Patel, MD

3:12pm

#### **Investigation of Change in Cardinal Symptoms of Chronic Rhinosinusitis After Surgical or Ongoing Medical Management**

Adam DeConde, MD, Jess Mace, MPH, Jeremiah Alt, MD, PhD, Zachary Soler, MD, MSc, Richard Orlandi, MD, Timothy Smith, MD, MPH  
Portland, Oregon, USA

**Introduction:** Chronic rhinosinusitis (CRS) has been defined as inflammation of the paranasal sinuses lasting at least 12-weeks with corresponding two or more "cardinal symptoms" that includes: 1) nasal obstruction, 2) thick nasal discharge, 3) facial pain/pressure, and 4) reduction or loss of sense of smell. Although prior studies have investigated symptoms of CRS after sinus surgery, none have compared the outcomes of these specific symptoms to ongoing medical therapy.



## ORLANDO BALLROOM N

**Methods:** Patients with CRS were prospectively enrolled into a multi-institutional comparative effectiveness cohort study. Subjects elected either continued medical management or endoscopic sinus surgery (ESS). Baseline characteristics and objective clinical findings were collected. Cardinal symptoms of CRS were operationalized by four questions on the 22-item SinoNasal Outcome Test (SNOT-22). Symptom improvement was evaluated in subjects with at least 6-month follow-up.

**Results:** A total of 342 subjects were enrolled with 69(20.2%) electing continued medical management while 273(79.8%) elected ESS. Subjects electing surgical therapy were more likely to have a higher baseline aggregate SNOT-22 score (44.3(18.9) vs. 53.6(18.8);  $p<0.001$ ). All subjects improved across all cardinal symptoms; however, subjects undergoing ESS were significantly more likely ( $p<0.013$ ) to experience improvement in thick nasal discharge (OR=4.36), facial pain/pressure (OR=3.56), and blockage/congestion of nose (OR=2.76). Subjects with nasal polyposis were significantly more likely to report complete resolution of smell/taste following ESS compare to medical management (23.8% vs. 4.0%;  $p=0.026$ ).

**Conclusions:** Across a large population, surgical management is more effective at resolving the cardinal symptoms of CRS than ongoing medical management with the exception of sense of smell/taste.

3:19pm

### **A Prospective Randomized Cohort Study Evaluating Three Weeks vs. Six Weeks of Oral Antibiotic Treatment in the Setting of “Maximal Medical Therapy” for Chronic Rhinosinusitis**

*Presented by: Adam Zanation, MD*

Satyan Sreenath, BS, Robert Taylor, MD, Justin Miller, MD, Charles Ebert, MD, MPH, Brent Senior, MD, Adam Zanation, MD  
Chapel Hill, NC, USA

**Introduction:** Surprisingly, little literature exists evaluating the optimal duration of antibiotic treatment in “maximal medical therapy” for chronic rhinosinusitis (CRS). As such, we investigated whether 3 weeks versus 6 weeks of antibiotic therapy resulted in significant differences in clinical response.

**Methods:** A prospective, randomized cohort study was performed with patients assigned to 3 or 6-week cohorts. Our primary outcome was failure of “maximal medical therapy” and surgical recommendation. Secondary outcomes included changes in pre- and post-therapy scores for the Rhinosinusitis Disability Index (RSDI), Chronic Sinusitis Survey (CSS), and CT-based Lund-Mackay (LM) evaluation. Analysis was sub-stratified based on presence of

nasal polyps and severity of LM scores.

**Results:** 40 patients were randomized to the 3 or 6-week treatment cohorts, with 100% follow-up achieved. No significant difference was found between the proportion of patients who failed medical therapy and deemed surgical candidates (71% vs. 68%,  $p=1.000$ ). No significant difference was found in the change of RSDI or CSS scores in comparing the cohorts (RSDI-  $9.62 \pm 19$  vs.  $1.53 \pm 17$ ,  $p=0.868$ ) (CSS-  $5.75 \pm 20$  vs.  $9.65 \pm 23$ ,  $p=0.573$ ). Lastly, no significant difference was found in the change of Lund-Mackay scores ( $3.35 \pm 5.07$  vs  $1.53 \pm 3.52$ ,  $p=0.829$ ).

**Conclusions:** Based on this data, we conclude that there is no difference in clinical outcomes between 3 weeks versus 6 weeks of antibiotic treatment as part of “maximal medical therapy” for CRS. Increased duration of antibiotic treatment theoretically increases risk from side effects and creates higher healthcare costs.

3:26pm

### **Medical Therapy versus Surgery for Recurrent Acute Rhinosinusitis**

Milena Costa, MD, Alkis Psaltis, MD PhD, Jayakar Nayak, MD PhD, Peter Hwang, MD  
Stanford, CA, USA

**Background:** Treatment indications for recurrent acute rhinosinusitis (RARS) remain poorly defined. We studied outcomes of medical versus surgical treatment of RARS; anatomic variants associated with RARS; and factors predicting crossover from medical to surgical treatment.

**Methods:** 220 RARS patients treated between 2006-2014 were retrospectively divided into three cohorts: primary medical (PM), primary surgical (PS), or medical crossing over into surgical (CROSS). SNOT-22 scores, modified Lund-Kennedy endoscopy scores, and prevalence of anatomic variants by CT were compared. 220 CT scans obtained for non-sinus indications served as controls. A logistic regression model was used for analysis.

**Results:** The mean baseline SNOT-22 scores for all cohorts were similar (PM=48, PS=49, CROSS=45,  $p<0.001$ ). The primary surgical cohort showed greater reduction of SNOT-22 scores than the primary medical cohort at 3, 6 and 12 months follow-up ( $p<0.00001$ ). The crossover cohort converted to surgery after escalation of SNOT-22 score by a mean of 15 points ( $p<0.03$ ), and showed significant reduction of SNOT-22 scores postoperatively ( $p<0.001$ ). Haller cell (OR:8.9;  $p<0.0001$ ), concha bullosa (OR:6;  $p<0.003$ ) and accessory ostium (OR:4;  $p<0.01$ ) were more common in the entire RARS group vs controls; however, there were no inter-cohort differences in prevalence.



Conclusion:

RARS patients experience greater symptomatic improvement from surgical treatment compared to medical treatment.

Patients cross over from medical to surgical treatment when SNOT-22 scores escalate by a mean of 15 points while on medical therapy. Haller cell, concha bullosa, and accessory ostium are associated with RARS but are equally common in medical, surgical, and crossover cohorts.

3:33pm

### **Biofilm Formation and Quality of Life Improvement after Sinus Surgery**

Zi Zhang, MD, MSCE, Nithin Adappa, MD, Alexander Chiu, MD, Laurel Doghramji, RN, BSN, Noam Cohen, MD, PhD, James Palmer, MD  
Philadelphia, PA, USA

Objective: Bacterial biofilms have been associated with unfavorable outcomes after endoscopic sinus surgery (ESS). However, it remains unclear how much these patients can benefit from ESS. We aimed to evaluate whether biofilm-formation was associated with quality of life (QOL) improvement after ESS.

Methods: This retrospective cohort study included adult CRS patients who underwent ESS between 2008 and 2011. Sinus samples were taken to evaluate for biofilm-formation in vitro using a modified Calgary Biofilm Detection Assay. QOL was measured before ESS, and 1-, 3- and 6-month after ESS using SNOT-22 scores. Patients' characteristics and medication use were collected. Clinical significant change of QOL was defined as difference of at least  $\frac{1}{2}$ SD of baseline SNOT-22 score in the reference group.

Results: 156 patients had complete data, and 15% had biofilm-formation (n=24). Patients with biofilm-formation had significantly worse preoperative SNOT-22 scores compared to patients without biofilm-formation ( $48 \pm 20$  vs.  $38 \pm 23$ ,  $p=0.048$ ), but both groups had clinically significant QOL improvement after ESS, and the differences in their 1-month ( $23 \pm 19$  vs.  $17 \pm 20$ ,  $p=0.231$ ) and 3-month ( $27 \pm 18$  vs.  $18 \pm 19$ ,  $p=0.102$ ) post-ESS SNOT-22 scores were not significant. Although QOL improvement from baseline to 6-month post-ESS was still clinically significant in both groups, patients with biofilm-formation demonstrated significantly worsening QOL compared to patient without biofilm-formation at 6-month post-ESS ( $35 \pm 25$  vs  $14 \pm 15$ ,  $p=0.001$ ).

Conclusion: CRS patients with biofilm-formation demonstrate clinically significant improvement of QOL following ESS, but the degree of improvement is reduced over time versus those patients without biofilms, who demonstrate stable QOL improvement.

3:40pm Q&A

Moderators: Vijay Ramakrishnan, MD & Seth Lieberman, MD

3:47pm

### **SNOT-22 Quality of Life Domains Differentially Predict Treatment Modality Selection in Chronic Rhinosinusitis**

Adam DeConde, MD, Jess Mace, MPH, CCRP, Peter Hwang, MD, Luke Rudmik, MD, Zachary Soler, MD, MSc, Timothy Smith, MD, MPH  
San Diego, CA, USA

Introduction: Prior study has demonstrated baseline Sinonasal Outcomes Test-22 (SNOT-22) aggregate score predicts patient-selection of surgical versus medical therapy. Factor analysis of the SNOT-22 has identified five distinct domains that are differentially impacted by surgical therapy. The present study seeks to investigate the SNOT-22 domains in patients electing surgical or medical management and the interval change in these domains post-intervention.

Methods: Patients with chronic rhinosinusitis (CRS) were prospectively enrolled into a multi-institutional, observational cohort study. Subjects elected continued medical management or endoscopic sinus surgery (ESS). SNOT-22 domain scores at baseline were compared between treatment cohorts. Post-treatment domain score change was evaluated in subjects with at least 6-month follow-up.

Results: 363 subjects were enrolled with 72(19.8%) electing continued medical management while 291(80.2%) elected ESS. Baseline SNOT-22 domains were comparable between treatment cohorts in disease-specific domains (rhinologic, extra-nasal rhinologic, and ear/facial symptoms,  $p>0.050$ ); however, the surgical cohort reported higher baseline psychological ( $16.0(8.4)$  vs.  $12.0(7.1)$ ;  $p<0.001$ ) and sleep dysfunction ( $13.7(6.8)$  vs.  $10.5(6.2)$ ;  $p<0.001$ ) than the medical cohort. ESS effect sizes varied across the domains with rhinologic and extra-nasal rhinologic symptoms experiencing the greatest gains (1.067 and 0.997, respectively) and psychological and sleep dysfunction experiencing the smallest improvements (0.805 and 0.818, respectively). All domains experience greater improvements after ESS compared to the medical cohort ( $p<0.001$ ).

Conclusion: Subjects electing ESS report higher sleep and psychological dysfunction than the medical cohort but have comparable disease-specific symptoms. Subjects undergoing ESS experience greater gains than the medical cohort across all domains; however, the psychological and sleep domains experienced the smallest improvements.

## ORLANDO BALLROOM N

3:54pm

### **Sleep and Quality of Life Improvements after Endoscopic Sinus Surgery in Patients with Chronic Rhinosinusitis**

Jeremiah Alt, MD, PhD, Timothy Smith, MD, MPH, Rodney Schlosser, MD, Jess Mace, MPH, CCRP, Zachary Soler, MD, MSc  
Salt Lake City, UT, USA

**Introduction:** Recent investigation has demonstrated that approximately 75% of patients with medically refractory chronic rhinosinusitis (CRS) report abnormal sleep quality, with strong correlation between worse sleep quality and more severe CRS disease severity. It remains unknown whether the treatment effect of endoscopic sinus surgery (ESS) for CRS results in appreciable sleep quality improvements.

**Methods:** Adult patients (aged >18 years) with a current diagnosis of recalcitrant chronic rhinosinusitis (CRS), who voluntarily elected ESS as the next treatment modality (n=301), were prospectively evaluated within four academic, tertiary care centers using treatment outcome instruments: the Rhinosinusitis Disability Index, the 22-item Sinonasal Outcome Test, the 2-item Patient Health Questionnaire, and the Pittsburgh Sleep Quality Index (PSQI) both before and after ESS.

**Results:** 72% of patients with CRS were found to have poor sleep (>5) at baseline with a mean global PSQI score of 9.4(4.6). Surgery improved overall mean global PSQI scores (2.2 points), and all 7 subdomain scores of the PSQI. Similarly, the odds of good sleep quality (PSQI =5) in patients treated with sinus surgery increased significantly (OR: 5.94, 95% CI: 3.06, 11.53; p<0.001). Stepwise multivariate linear regression found that ASA intolerance ( $\beta = -1.94(0.93)$ ; 95% CI: -3.77, -0.11; p=0.038), history of prior sinus surgery ( $\beta = 1.10(0.54)$ ; 95% CI: 0.03, 2.16; p=0.044), and frontal sinusotomy ( $\beta = -1.03(0.62)$ ; 95% CI: -2.26, 0.20; p=0.099) were found to significantly associate with improvement in PSQI sleep scores.

**Conclusions:** Among patients with CRS, reduced sleep quality, poor disease-specific quality of life, and greater disease severity were improved following ESS.

4:01pm

### **The Impact of Sinus Surgery on Sleep Outcomes**

Brian Rotenberg, MD MPH, Kenny Pang, MD  
London, ON, Canada

**Objective:** Endoscopic sinus surgery is the standard of care procedure for patients who fail medical management of chronic sinusitis (CRS). The beneficial impact of surgery on CRS outcomes is well known. Anecdotally patients note that their sleep is improved after sinus surgery, even without simultaneous correction of nasal obstruction. Sleep

outcomes after ESS are understudied. In the current project we characterized patient sleep quality following sinus surgery.

**Methods:** A prospectively performed study from two sites (Western University [Canada] and the Asia Sleep Center [Singapore]). Patients meeting diagnostic criteria for CRSsNP underwent surgery. Cases with obstructive polyposis and those who needed a septoplasty were excluded so as to purely analyze the impact of sinus surgery on sleep. Sleep outcomes recorded at baseline just prior to surgery and 3-months after surgery were the Epworth Sleepiness Scale (ESS) and Pittsburgh Sleep Quality Index (PSQI). We recorded SNOT-22 scores and NOSE scores as well. Comparisons were made with paired t-tests.

**Results:** 53 consecutive patients met inclusion/exclusion criteria. Sleep outcomes showed a clinically and statistically significant improvement (ESSpre = 14.7, ESSpost = 9.2, p<0.01; PSQIpre = 10.9, PSQIpost = 5.3, p<0.01). CRS specific outcomes were improved as well. Nasal obstruction scores did not change significantly.

**Conclusion:** Endoscopic sinus surgery was able to improve sleep outcomes for the patients in our study. This was independent of correction of nasal obstruction. Sinus surgery has a beneficial impact on sleep; this novel information can be used during patient counseling and for justification to third party payers.

4:08pm

### **The Impact of Diabetes Mellitus on Outcomes of Endoscopic Sinus Surgery: A Nested Case-control Study**

Amal Hajjij, MD, Jess Mace, MPH, CCRP, Zachary Soler, MD, MSc, Michelle Barton, BA, Timothy Smith, MD, MPH, Peter Hwang, MD  
Stanford, CA, USA

**Introduction:** Given the immune impairment associated with diabetes mellitus (DM), the impact of DM on chronic rhinosinusitis (CRS) is a potentially relevant concern, yet it has not been well-studied. A single retrospective study reported worse post-operative quality of life outcomes in CRS patients with DM. Our study evaluated the effect of comorbid DM on outcomes of endoscopic sinus surgery (ESS) using a prospective study design.

**Methods:** Using a multi-centered, prospective cohort study of patients (n=437) undergoing ESS for recalcitrant CRS between 2011-2014, a nested case-control comparison was performed between 20 DM adult patients (cases) and 20 non-diabetic patients (controls), matched 1:1 for age and Lund-Mackay CT scores. Outcome measures included 22-item Sinonasal Outcome Test (SNOT-22), Rhinosinusitis Disability Index (RSDI), Patient Health Questionnaire (PHQ-2), and Brief Smell Identification Test (BSIT).

Results: Mean post-operative follow-up was similar between cases (12.6(6.0) months) and controls (12.9(5.9) months;  $p=0.862$ ). Pre-surgical scores for all outcomes instruments were statistically equivalent between DM and non-DM cohorts. Both cohorts showed significant post-ESS improvement in SNOT-22 ( $p=0.001$ ) and RSDI scores ( $p<0.001$ ), and no significant change in PHQ-2 or BSIT scores. The magnitude of post-operative score changes was statistically equivalent between DM and non-DM cohorts for all outcome measures. There were no differences in post-operative score changes between insulin-dependent diabetics and those managed by oral hypoglycemics or dietary restriction ( $p>0.444$ ).

Conclusion: Diabetic patients with CRS experience similar degrees of symptomatic benefit from ESS compared to matched non-diabetic patients. Among diabetic patients, insulin dependence does not appear to adversely affect surgical outcome.

4:15pm  
Q&A

4:22pm

## **Panel: Quality of Life after Sinus Surgery: What Should Patients Expect?**

Moderator: Nathan Sautter, MD

Panelists: Charles Ebert, MD & Zachary Soler, MD

4:55pm

### **Closing Remarks & Meeting Adjourned**

5:00pm

### **Advances in Aerosol Therapy for Patients with Allergic Rhinitis (TEVA 4-Corners Symposium)**

Regency Ballroom Q

Food & Beverage Served

6:30pm

### **ARS President's Wine & Cheese Poster Reception and Presidential Address (Supported by Intersect ENT)**

Regency Foyer & Regency Ballroom R







## ORLANDO BALLROOM M

1:00pm

**Welcome:** Jayakar Nayak, MD  
Orlando Ballroom M Chairperson

### **Session Topic: Innate Immune Alterations in CRS**

Moderators: Noam Cohen, MD & Eugene Chang, MD

1:05pm

#### **Cigarette Smoke Exposure is Associated with Vitamin D3**

Jennifer Mulligan, PhD, Whitney Nagel, BS, Brendan O'Connell, MD, Jennifer Wentzel, BS, Carl Atkinson, PhD, Rodney Schlosser, MD  
Charleston, SC, USA

**Background:** Cigarette smoke (CS) plays a role in the exacerbation of chronic rhinosinusitis (CRS); however, the mechanism for this is unknown. We hypothesize that CS impairs human sinonasal epithelial cell (HSNEC) conversion of 25(OH) D3 (25VD3) to 1,25-dihydroxyvitamin D3 (1,25VD3).

**Objective:** We examined the effect of CS on vitamin D3 (VD3) levels, conversion, and regulation of CS-induced inflammation in control subjects and patients with CRS.

**Methods:** Blood and sinus tissue explants were collected at the time of surgery from control subjects, patients with chronic rhinosinusitis without nasal polyps, and patients with chronic sinusitis with nasal polyps (CRSwNP). Expression of VD3 metabolizing enzymes was measured using RT-PCR. Primary HSNECs were cultured from tissue explants. 25VD3 with and without cigarette smoke extract (CSE) was used to examine conversion of 25VD3 to 1,25VD3, as well as HSNEC production of proinflammatory cytokines.

**Results:** CS exposure was associated with reduced circulating and sinonasal 25VD3 levels in all groups compared with those seen in CS-naïve, disease-matched counterparts. CS exposure decreased expression of CYP27B1 and especially in patients with CRSwNP. CSE impairs control HSNEC conversion of 25VD3. HSNECs from patients with CRSwNP also demonstrate an intrinsic impairment in conversion of 25VD3 to 1,25VD3. Exogenous 1,25VD3 reduces CSE-induced cytokine production by HSNECs.

**Conclusions:** Exposure to CS is associated with reduced 25VD3 levels and an impaired ability of HSNECs to convert 25VD3 to 1,25VD3. Addition of 1,25VD3 reduces the proinflammatory effects of CS on HSNECs. Impaired VD3 conversion by CS exposure represents a novel mechanism for CS-induced proinflammatory effects.

1:12pm

#### **25VD3 as a Novel Regulator of bFGF in Chronic Rhinosinusitis with Nasal Polyposis**

Eugene Sansoni, MD, Nathan Sautter, MD, Timothy Smith, MD, MPH, Jess Mace, MPH, CCRP, Zachary Soler, MD, MSc, Jennifer Mulligan, PhD  
Portland, Oregon, USA

**Introduction:** Basic fibroblast growth factor (bFGF) plays a role in tissue remodeling in many normal and pathologic conditions; however, its role in chronic rhinosinusitis (CRS) is incompletely understood. 25hydroxyvitamin D (25VD3) has been shown to alter inflammatory mediators in other disease processes, and 25VD3 deficiency is associated with CRS with nasal polyps (CRSwNP), but it is unknown if 25VD3 levels impacts inflammation or tissue remodeling in CRS. This study investigated the correlation between plasma 25VD3 and sinonasal mucus bFGF levels in patients with CRS.

**Methods:** Study subjects undergoing endoscopic sinus surgery (ESS) for CRS were prospectively enrolled between January, 2012-January, 2014. Control subjects included patients undergoing ESS for non-inflammatory pathology. Blood and sinonasal mucus were collected at the time of ESS. Plasma 25VD3 was measured by ELISA and mucus levels of bFGF by cytometric bead array.

**Results:** 50 patients were enrolled and categorized as CRS without nasal polyps (CRSsNP; n=32), CRSwNP (n=11) and controls (n=7). bFGF was increased in CRSwNP compared to controls (p=0.040) but not CRSsNP (p=0.187). Using a Spearman's correlation, there was a negative correlation between 25VD3 and bFGF in CRSwNP patients (p=0.010); however, there was no significant correlation in CRSsNP patients. Plasma bFGF did not correlate with 25VD3.

**Conclusion:** This data suggests 25VD3 may play a role in regulation of bFGF expression in CRSwNP. This may occur through regulation of fibroblast maturation, suggesting a role for VD3 in tissue remodeling in CRS. Further investigation is warranted to better elucidate the role of bFGF and 25VD3 in CRSwNP.

1:19pm

#### **Characterization of IgE Plasma Cells that are Elevated in the Nasal Mucosa of Patients with Chronic Rhinosinusitis (CRS)**

Ali Rashan, MD, MS, Yang Yang, PhD, Leonore Herzenberg, PhD, Peter Hwang, MD, Jayakar Nayak, MD, PhD  
Stanford, CA, USA

**Introduction:** Chronic rhinosinusitis (CRS) is a complex disease where much of the underpinning mechanism has yet to be elucidated. Our previous studies suggest that B cell and

IgE plasma cell populations are increased in CRS. However, further investigation is needed to define these B cell and IgE plasma subsets. In this study, we phenotype IgE plasma cells, which are found to be elevated in the nasal tissue of CRS subjects.

**Methods:** Blood, ethmoid sinus mucosa, and nasal polyp tissue samples were analyzed from 3 cohorts: control (n=5), CRSsNP (without polyps) (n=10), and CRSwNP (with polyps) (n=5). Tissue samples were evaluated using 14-parameter hi-dimensional flow cytometry of single cell suspensions.

**Results:** A population of IgE plasma cells is significantly increased in inflamed nasal tissue when compared to normal nasal tissue and the peripheral blood,  $p < 0.05$ . This IgE plasma cell population displayed almost exclusive expression of cell surface IgLambda light chain, opposed to the usual approximate 50/50 distribution of IgKappa and IgLambda on B cells in the peripheral blood. This population of interest is positive for Ki-67+ and intracellular IgE expression, all of which are consistent with the IgE plasma cell phenotype.

**Conclusions:** Upper airway nasal mucosa from CRS patients demonstrate a significant spike in resident in situ IgE plasma cells not seen in control nasal tissue or blood from same patient. This plasma cell population with signature expression of lambda expression points towards a potential signature B Cell present in CRS which may hold therapeutic significance.

1:26pm

### **Mast Cell Deficiency Limits the Development of Chronic Rhinosinusitis in Mice**

Xiaoyang Hua, MD, Stephen Tilley, MD, Brent Senior, MD  
Iowa City, IA, USA

**Background:** Chronic rhinosinusitis is a common chronic disease affecting the sinonasal mucosa. It has become a major factor that adversely affects quality of life. Its pathogenesis is yet to be determined.

**Methods:** C57BL/6 mice were immunized by intraperitoneal (i.p.) injection and subsequent chronic low dose intranasal (i.n.) challenges. The sinonasal phenotypes were then evaluated by using radiologic, histologic and immunologic methods. C57BL/6 KitW-sh/W-sh mast cell-deficient mice were used to evaluate the role of mast cells in the pathophysiology.

**Results:** By using a chronic low dose antigen challenge protocol, wild type mice developed significant mucosal thickening in the middle turbinates and lateral sinuses, pseudocyst structure and intraepithelial gland in the nasal mucosa, and multiple polypoid structures in the maxillary and

lateral sinuses. In contrast, neither C57BL/6 KitW-sh/W-sh mice treated with antigen nor wild type mice treated with saline developed these pathological features. In addition, mast cell deficiency significantly limited the development of goblet cell hyperplasia, eosinophilia and epithelial cell hypertrophy in the lateral sinuses.

**Conclusions:** In this study, we report a mouse model of CRS that has recapitulated many features of human CRS including polypoid changes, mucus hypersecretion, goblet cell hyperplasia, epithelial cell hypertrophy and hyperplasia, and mucosal edema in the lateral sinuses and middle turbinates. In addition, mast cell deficiency significantly limited the development of many pathological features in this CRS model, suggesting a critical role for mast cells in CRS pathophysiology.

1:33pm

### **Pro-inflammatory Mediators Alter Expression of NF-Kappa B-Regulating Deubiquitinases in Sinonasal Epithelial Cells**

Justin Turner, MD PhD, Ying Wang, MD, Ping Li, MD  
Nashville, TN, USA

**Introduction:** NF-Kappa B is a vital transcription factor that is activated by numerous inflammatory stimuli. Its activity is tightly regulated by a family of deubiquitinating enzymes (A20, Cezanne, CYLD) that function in a negative-feedback loop, a process that prevents chronic and systemic inflammation. This study seeks to characterize the expression and functional role of NF-Kappa B-regulating deubiquitinases in the sinonasal epithelium.

**Methods:** Expression of A20, Cezanne, and CYLD was assessed in normal sinonasal tissue using immunohistochemistry and western blot. Cultured sinonasal epithelial cells were stimulated with pro-inflammatory cytokines (TNF-alpha, IL-4, IL-13) or LPS and changes in deubiquitinase expression were assessed using quantitative real-time PCR.

**Results:** A20, Cezanne, and CYLD were all expressed in sinonasal tissue, primarily along the apical surface of the epithelium. A20, Cezanne, and CYLD were rapidly upregulated by TNF-alpha. LPS increased expression of A20, but not Cezanne or CYLD. IL-4 and IL-13 did not significantly alter the expression of any deubiquitinases.

**Conclusions:** The NF-Kappa B-regulating deubiquitinases A20, Cezanne, and CYLD are expressed in sinonasal tissue. Their expression at the surface of the epithelium suggests that they may be constitutively expressed in order to regulate inflammatory signals produced by extracellular pathogens. The expression of A20, Cezanne and CYLD can also be

## ORLANDO BALLROOM M

differentially induced by pro-inflammatory cytokines and microbial antigens. These results suggest an important role for NF-Kappa B-regulating deubiquitinases in mucosal immunity and homeostasis.

1:40pm  
Q&A

### Session Topic: Novel Medical Treatments for CRS

Moderators: Bruce Tan, MD & Jeffrey Suh, MD

1:47pm

#### Acute Inflammation causes Acquired Defects in Transepithelial Cl- Transport

Jessica Grayson, MD, Shaoyan Zhang, BS, Daniel Skinner, BS, James Fortenberry, BS, Eric Sorscher, MD, Bradford Woodworth, MD  
Birmingham, AL, USA

**Objectives:** The objectives of the present study were to test models of acute inflammation for their contribution to acquired defects in transepithelial Cl<sup>-</sup> secretion.

**Methods:** Primary murine nasal septal epithelial (MNSE) cultures were exposed to lipopolysaccharide (LPS) or *Pseudomonas aeruginosa* (PAO1; bacteria-free preparation from 20 hour log-phase growth) ultrafiltrate. Basal media was collected from airway cell monolayers and analyzed for murine CXCL1/KC (human IL-8 analogue) by ELISA to confirm activation of NFκB mediated inflammatory signaling. Monolayers were tested in Ussing chambers by short-circuit current measurement. Wild type mice were administered LPS through both nostrils for 1 week and transepithelial Cl<sup>-</sup> transport monitored by the nasal potential difference assay. Acute inflammation was evaluated by histopathology.

**Results:** MNSE cultures incubated with PAO1 filtrate or LPS (100 nM) for 24 hours produced significantly elevated CXCL1/KC (PAO1, 1267.4±/54.3 pg/ml and LPS, 1774±/159.4 pg/ml) when compared to controls (660±/139.5 pg/ml) (p<0.05). CFTR-mediated Cl<sup>-</sup> transport [change in short-circuit current, ?ISC(μA/cm<sup>2</sup>)] measured using forskolin (20 μ?) was significantly decreased compared to controls (PAO1, 9.7±/0.5; LPS, 9.6±/1.6; control, 13.8±/0.9, p<0.05). Quantitative PCR showed significant inhibition of CFTR mRNA expression when cultures were incubated with PAO1 (0.76±/0.03) and LPS (0.69±/0.19) versus no treatment (1±/0.19) (p < 0.05). Transepithelial Cl<sup>-</sup> secretion by NPD was significantly reduced in mice exposed to LPS (-0.14±/7.7 vs. control; -6.98±/7.15, p<0.05).

**Conclusions:** Exposure to LPS or PAO1 extract in primary airway epithelial cells led to acquired defects in transepithelial

Cl<sup>-</sup> transport. These findings indicate that acute inflammation or infection in sinonasal epithelia may confer significant defects in CFTR activity, reduce MCC, and establish a localized cystic fibrosis-like phenotype in vivo.

1:54pm

#### Omeprazole Strongly Inhibits IL-13-induced Eotaxin-3/CCL26 Expression in Human Sinonasal Epithelial Cells

Jin Min, MD, Robert Kern, MD, David Conley, MD, Robert Schleimer, PhD, Julia Hwang, BS, Bruce Tan, MD  
Chicago, IL, USA

**Introduction:** Chronic rhinosinusitis with nasal polyps (CRSwNP) is frequently characterized by an eosinophilic mucosal infiltrate. Elevated levels of eotaxin-3/CCL26 and Th2 cytokines (e.g. IL-13) are found in nasal polyp tissue while research in asthma suggests that eotaxin-3 has potent eosinophil chemoattractive properties. While proton pump inhibitors (PPIs) are best known for gastric acid inhibitory effects, they are increasingly found to have anti-inflammatory properties relevant to eosinophilic disorders like asthma and eosinophilic esophagitis.

**Objective:** To characterize the effects of medications (glucocorticoids and PPI) on Th2-cytokine induced eotaxin-3 expression in human sinonasal epithelial cells (SNEC) and the bronchial epithelial cell-line BEAS-2B.

**Methods:** BEAS-2B (n=3), and SNEC from inferior turbinate (IT) scrapings from control (n=4) and IT and polyp scrapings of CRSwNP patients (n=9), were cultured with Th2 cytokines (IL-4 1ng/ml or IL-13 5ng/ml) for 48 hours in the presence or absence of dexamethasone and/or omeprazole. Eotaxin-3 mRNA expression was measured by real-time PCR and protein secretion by ELISA.

**Results:** IL-4 and IL-13, but particularly IL-13, strongly stimulated eotaxin-3 expression in BEAS-2B and SNEC. In SNEC, both dexamethasone (1μM) and omeprazole (1μM) significantly suppressed IL-13-stimulated epithelial Eotaxin-3 mRNA relative expression (Dexamethasone treated/untreated 0.62±0.14 vs 1.02±0.2; p<0.05, Omeprazole treated/untreated 0.72±0.2 vs 1.12±0.5; p<0.01) and protein secretion (Dexamethasone treated/untreated: 1.8±0.8 vs 4.1±0.9 ng/ml, Omeprazole treated/untreated 2.7±1.9 vs 4.9±2.8 ng/ml; p<0.05).

**Conclusion:** Th2 cytokines potently stimulate eotaxin-3 production in SNEC and this is strongly inhibited by both dexamethasone and omeprazole at concentrations achievable in vivo using conventional oral dosing. These findings suggest that these drugs may modulate epithelial-derived chemotactic factors providing novel opportunities for future treatment of CRSwNP.

2:01pm

**Verapamil Modulates IL-5, IL-6, and TSLP Secretion in Organotypic Human Sinonasal Polyp Explants**

Benjamin Bleier, MD, Armine Kocharyan, MD, Amy Singleton, BS  
Boston, MA, USA

Background: Verapamil is an L-type calcium channel blocker (CCB) which has been shown to have immunomodulatory properties in a variety of tissues. The goal of this study is determine whether Verapamil is capable of regulating cytokine secretion in sinonasal polyps and to compare this effect to dexamethasone, an established immunosuppressive corticosteroid.

Methods: IRB approved study in sinonasal polyp explants derived from 8 patients with Chronic Rhinosinusitis with Nasal Polyps (CRSwNP). Polyps were incubated with Dexamethasone or Verapamil for 24 hours followed by an additional 24 hours with Staphylococcal enterotoxin B (SEB). Concentrations of secreted cytokines over each exposure period were determined by ELISA and expressed as a percent. Results were compared using a 2-tailed Student's t-test.

Results: The percent of SEB stimulated IL-5 secretion (mean $\pm$ SD, 339.94 $\pm$ 315.48%) between the second and first treatment periods was significantly reduced following exposure to Dexamethasone (74.08 $\pm$ 26.77%,  $p < 0.05$ ) and Verapamil (119.99 $\pm$ 69.32%,  $p < 0.05$ ). The percent of SEB stimulated IL-6 secretion (217.53 $\pm$ 89.51%) was also significantly reduced following exposure to Verapamil (148.82 $\pm$ 79.15%,  $p < 0.05$ ) but not Dexamethasone (148.86 $\pm$ 145.24%). Finally, the percent of SEB stimulated TSLP secretion (37.86 $\pm$ 18.88%) demonstrated a non-significant trend towards reduction with both Dexamethasone (31.15 $\pm$ 35.28%) and Verapamil (20.14 $\pm$ 12.10%).

Conclusions: While the mechanism has yet to be fully understood, L-type CCBs are capable of reducing inflammation in multiple tissues. Verapamil was specifically found to reduce airway goblet cell hyperplasia and eosinophilic infiltration in a murine asthma model. Our data support these findings suggesting that Verapamil can modulate Th2 associated cytokine secretion in sinonasal polyp explants. This data points to a possible therapeutic role for CCBs in the management of CRSwNP.

2:08pm

**CFTR Potentiation Reverses Findings of Chronic Sinusitis and Modulates ASL in CF Sinus Epithelia**

Eugene Chang, MD  
Iowa City, IA, USA

Objective: Chronic sinusitis is universal in cystic fibrosis (CF). Current treatments do not prevent the progression of disease. We initiated ivacaftor therapy in a CF patient directed at the molecular defect of G551D-CFTR. We then investigated the effect of ivacaftor on ASL pH and ASL viscosity in airway cultures grown from a biopsy of the patient.

Methods: Study subject: adult patient with long-standing chronic sinus disease and a new diagnosis of CF based on sweat chloride value, nasal potential difference testing, and CFTR genotyping positive for a mild mutation (P205S) and a severe mutation (G551D) that was amenable to treatment with ivacaftor.

In vivo testing: Nasal potential difference testing, sinus CT scan, and nasal pH values before and after treatment with ivacaftor.

In vitro testing: Development of primary sinonasal epithelial cell cultures from a biopsy of the patient. Testing of ASL pH and ASL viscosity to ivacaftor treatment.

Results: Ivacaftor treatment reversed CT findings of CF sinus disease, increased nasal voltage and pH and resolved sinus symptoms after ten months of therapy. Ivacaftor significantly increased ASL pH and decreased ASL viscosity in primary airway cultures.

Conclusion: This is the first report of reversal of CF sinus disease. These studies suggest that CFTR modulation may be effective in treating CF and perhaps non-CF sinusitis.

2:15pm

Q&amp;A

2:22pm

**Panel: Novel Medical Treatment Strategies for CRS**

Moderator: Andrew Lane, MD

Panelists: William Bolger MD & Benjamin Bleier, MD

2:52pm

**Break with Exhibitors**

Regency Ballroom P-O



## ORLANDO BALLROOM M

### Session Topic: Medical Economics

Moderators: Pablo Stolovitzky, MD & Belachew Tessema, MD

3:12pm

#### Developing a Laddered Algorithm for the Management of Intractable Epistaxis: A Risk Analysis

Randy Leung, MD, Timothy Smith, MD MPH, Luke Rudmik, MD MSc  
Barrie, Ontario, Canada

**Background:** Cost-effectiveness analyses have advocated movement away from prolonged posterior packing in the management of intractable epistaxis, and towards the early adoption of transnasal endoscopic sphenopalatine artery ligation (TESPAL) or endovascular embolization once patients have been stabilized. Although cost-effectiveness provides physicians with recommendations for a responsible use of resources, it is not patient centered. To facilitate a patient-centered decision making process, there needs to be an understanding of the risks involved. This study aims to identify an effective, low-risk laddered algorithm for the management of intractable epistaxis.

**Method:** A risk analysis was performed using literature reported probabilities of treatment failure, adverse event likelihoods. Severities of consequences were modeled based on EPA modeling recommendations and quality of life conversions based on willingness-to-pay.

**Results:** Packing First, TESPAL First, and Embolization First strategies were found to have total risks of \$3,123.47 (Range 2,314.83- 6,568.64), \$4,413.83 (Range 3,333.60-9,159.02), \$16,294.33 (Range 8,020.42- 36,603.77), respectively.

**Conclusion:** Based on risk minimization and cost effectiveness, we recommend a laddered approach to intractable epistaxis comprised of TESPAL, followed by embolization, then prolonged posterior packing.

3:19pm

#### Radiographic Evaluation of Nasal Septal Deviation from Computed Tomography Correlates Poorly with Physical Exam Findings

Regan Bergmark, MD, Ahmad Sedaghat, MD, PhD, David Kieff, MD, Mary Cunnane, MD, Nicolas Busaba, MD  
Boston, MA, USA

**Introduction:** Performance of septoplasty is dependent on objective evidence of nasal septal deviation. Although physical examination including anterior rhinoscopy and endoscopic examination is the gold standard for evaluation of septal deviation, third-party payors' reviews of septoplasty claims are often made on computed tomography (CT) findings. However, the correlation between radiographic

evaluation of septal deviation with physical examination findings is unknown.

**Study Design and Methods:** Blinded, independent evaluation of septal deviation in 39 consecutive patients from physical examination, including anterior rhinoscopy and endoscopic examination, by an otolaryngologist and radiographic evaluation of sinus CT scan by a neuroradiologist. Four distinct septal locations (nasal valve, cartilaginous, inferior/maxillary crest and osseous septum) were evaluated on a four-point scale representing 1) 0-25%, 2) >25-50%, 3) >50-75% and 4) >75% obstruction. Correlation between physical examination and radiographic evaluations was made by Pearson's correlation and quantitative agreement assessed by Krippendorff's alpha.

**Results:** Statistically significant correlation was detected between physical examination including nasal endoscopy and radiographic assessment of septal deviation only at the osseous septum ( $P=0.007$ ,  $r=0.425$ ) with low quantitative agreement ( $\alpha=0.290$ ). No significant correlation was detected at the cartilaginous septum ( $P=0.286$ ,  $r=0.175$ ), inferior septum ( $P=0.117$ ,  $r=0.255$ ) or nasal valve ( $P=0.174$ ,  $r=0.222$ ). Quantitative agreement at the nasal valve suggested a bias in CT to underestimate physical exam findings ( $\alpha=-0.490$ ).

**Conclusions:** CT is a poor substitute for physical examination, the gold standard, in assessment of septal deviation. Clinical decisions about pursuit of septoplasty or third-party payors' decisions to approve septoplasty should not be made on radiographic evidence.

3:26pm

#### Standardized and "Structured" Pathology Reports Provide Critical Prognostic Information for Chronic Rhinosinusitis Patients Undergoing Endoscopic Sinus Surgery

Devyani Lal, MD, Matthew Rank, MD, Alexis Rounds, BS  
Yu-Hui Chang, Ph.D, Matthew Zarka, MD  
Phoenix, AZ, USA

**Objectives:** Assess "structured" surgical-pathology (SSP) reportage in predicting patient-reported outcomes from endoscopic sinus surgery (ESS) for chronic rhinosinusitis (CRS).

**Methods:** An IRB-approved retrospective review of patients undergoing ESS for CRS was conducted (2011-2013). The ability of SSP reports in predicting outcomes from ESS (change in total SNOT-22 score) at 3 months was studied. "Traditional" surgical-pathology reports were audited for comprehensiveness.

**Results:** Of 312 patients, SSP reports were available in 104.

Using the effect-size of 0.8 (“significant clinical benefit”) on SNOT-22 scores, the SSP was not helpful in discriminating “poorer” outcomes since all patients had significant response from ESS. A higher effect-size was therefore chosen (22.7 point change in total SNOT-22 score; effect-size 1.07). With this cut-off, the following SSP items predicted “poorer” outcome: worse “overall degree of inflammation” (mild/moderate/ severe;  $p=0.01$ ); more “eosinophils/HPF” ( $< 5$  vs.  $5-10$  vs.  $>10$ ;  $p= 0.03$ ); “eosinophil  $>10/HPF$ ” ( $p=0.023$ ); “eosinophilic inflammatory predominance” ( $p= 0.01$ ) and “sub-epithelial edema” ( $p=0.03$ ). In the 208 “traditional” pathology reports, information missing included overall degree of inflammation (23.35%), eosinophilic aggregates (94.41%), fungal elements (81.2%) and the key predictors noted above.

Conclusions: “Structured” reporting for ESS specimens has been proposed recently. We provide the first, independent validation of this multiple-item “synoptic” report in predicting patient-reported outcomes. The overall degree of inflammation, degree of tissue eosinophilia, eosinophilic inflammatory predominance and sub-epithelial edema are significant predictors of “poorer” outcomes after ESS. These items are not always incorporated in “traditional” reportage, losing important prognostic information, and the opportunity to direct more intensive therapy clinically.

3:33pm

#### **Long-term Follow Up on Eustachian Tube Balloon Dilation Surgery**

Angela Donaldson, MD, Edward McCoul, MD, MPH, Sahana Somasegar, BS, Vijay Anand, MD  
New York, NY, USA

Objective: Since the initial feasibility and safety publication of 2011, eustachian tube balloon dilation surgery has gained recognition as a viable option for surgical management of eustachian tube dysfunction (ETD). This surgical methodology has been added to the milieu of treatment options for the adult (ETD). Few studies have reported their long-term findings using this technique. We present our long-term data using a validated disease- specific symptom score.

Study Methods: Consecutive patients undergoing balloon dilation of eustachian tube were prospectively enrolled from an otolaryngology practice in a tertiary medical center from 2010 to 2013. Inclusion criteria included patients greater than 18 years of age with ETD based on history and ETDQ-7 score. Repeat questionnaires were completed at 3, 6, 12 weeks, 6 months, 1, 2, and 3 years. Long-term follow up data was characterized as early and late based on last ETDQ-7 value.

Results: There was a total of 90 patients enrolled in the

study. Seventy-seven (85%) patients had documented preoperative ETDQ-7 questionnaires. Fifty-five patients were placed into the early category with follow up between 6-12 months. They had a mean ETDQ-7 of 3.3. The late category included patients with data between 18-36 months. This had a total of 35 patients with a mean ETDQ-7 of 3.5. At last follow up, both categories had ETDQ-7 values significant for clinical change.

Conclusion: The long-term follow up for improvement in clinical symptoms in our series showed improvement with stability in results at both early and late follow up times.

3:40pm

Q&A

Moderators: Stella Lee, MD & Seth Brown, MD

3:47pm

#### **Primary Headache Disorder Patients Presenting with “Sinus Headaches” Have Distinct Associations Between SNOT-22 Questionnaire Items and Therapeutic Response**

Devyani Lal, MD, Alexis Rounds, BS, Hirohito Kita, MD, PhD  
Matthew Rank, MD, Rohit Divekar, MBBS, PhD  
Phoenix, AZ, USA

Objectives: Study patient-characteristics, SNOT-22 symptoms and therapeutic responsiveness in “sinus-headache” patients with primary headache disorders (PHD).

Methods: Retrospective review of “sinus-headache” patients managed in the Rhinology Clinic was conducted. Included study-patients had sinusitis excluded (negative endoscopy/ CT) and neurologist-confirmed PHD. Multi-variable cluster and network analysis of SNOT-22 scores and patient-characteristics was conducted. True CRS patients (103) were analyzed as controls.

Results: Forty-six “sinus-headache” patients met study-inclusion criteria (PHD-positive sinusitis-negative). All had facial pressure/pain with variable rhinologic symptoms. Past history was positive for neurological diagnoses (60%), rhinologic disease (39%; CRS, rhinitis, recurrent acute sinusitis), sinonasal surgery (41%), asthma (28%) and allergen-sensitivity (26%). Median SNOT-22 score was 54 [40-63 IQR; CRS-controls 45 (28-61)]. Cluster and network analysis showed two distinct associations between SNOT-22 items and PHD patient-characteristics. Psychosocial-symptoms grouped closely with “facial pain/pressure” and linked to a 31-patient cluster (67.39%; Cluster-1). Sinonasal-symptoms grouped together and linked to another 15-patient cluster (32.6%; Cluster-2). In contrast to Cluster-2, Cluster-1 patients were predominantly female ( $p=0.03$ ), had higher ( $p=0.0001$ ) median SNOT-22 scores [60 vs. 34; IQR 53-67



## ORLANDO BALLROOM M

vs. 17-42], were uniquely “sad” ( $p=0.0001$ ) or “embarrassed” ( $p=0.006$ ), and were unresponsive to rhinologic therapy ( $p=0.09$ ). Clusters were otherwise similar in response to neurological intervention, past rhinologic diagnoses, subtypes of PHD/migraines, endoscopy findings and CT scores. CRS-controls showed equivalent associations with sinonasal/psychosocial-symptoms.

Conclusions: “Sinus-headaches” due to PHD have associated rhinologic symptoms in the absence of sinusitis. While all patients responded to neurological intervention, those reporting higher total SNOT-22 scores/psychosocial-symptoms, who were “sad” or “embarrassed” did not respond to rhinologic therapy.

3:54pm

### **Attitudes on and Usage of Balloon Catheter Technology in Rhinology: A Survey of the American Rhinologic Society**

Ashleigh Halderman, MD, Timothy Smith, MD, MPH,  
Raj Sindwani, MD  
Cleveland, OH, USA

Introduction: Use of balloon catheter technology (BCT) in the management of CRS remains controversial. In an effort to gain some clarity on its evolving role, we surveyed members of the American Rhinologic Society(ARS).

Method: On-line survey

Results: Members were emailed an invitation to participate in an on-line, anonymous 23-item survey. 231 participants completed the survey for an overall response rate of 23%. There was an even split between types of practices (academic vs private). BCT played no role in the practices of 1/3 of academics and 1/4 of private practitioners. Of those that did use BCT, over 50% performed only 1-4 cases/month on average. This did not differ significantly with practice type ( $p > 0.05$ ). The overall use of BCT differed between types of practices with those in private practice reporting greater use of the technology for maxillary and sphenoid sinuses ( $p=0.0002$  and  $p=0.004$  respectively). Participants in private practice appeared significantly more impressed with the results of BCT when compared to those in academia (mean scores 3.80 and 3.23 respectively,  $p=0.0002$ ), and also felt that patients were more satisfied (mean score 3.9 and 3.4 respectively,  $p<0.0001$ ). Opinions towards the strength of available evidence also differed significantly between the two groups ( $p=0.0003$ ). Twenty percent of respondents had experienced a complication with BCT, although the majority of these did not require any intervention.

Conclusions: Currently, ARS members utilize BCT very infrequently in their practices. Attitudes on the role of this

technology in the management of CRS differ widely between academic and private practitioners.

4:01pm

### **The Use of Image-Guidance during Transsphenoidal Pituitary Surgery in the United States**

Thomas K. Chung, MD, Kristen O. Riley, MD, Bradford A. Woodworth, MD

Introduction: Intraoperative image-guidance is a useful modality for transsphenoidal pituitary surgery. However, the impact of this technology on pituitary surgical outcomes has not been systematically evaluated.

Methods: A retrospective analysis of the Nationwide Inpatient Sample was performed from 2007 to 2011. Transsphenoidal pituitary resections for adenomas were identified by ICD-9-CM code. The impact of image-guidance on CSF leak complications and cost-benefit was analyzed. Results: A total of 48,848 trans-sphenoidal pituitary resections were identified, of which 77.5% were partial resections and 22.5% were complete. Pathologic indications included benign (89.3%), malignant primary (0.6%), and malignant secondary (0.4%). Complications included same-stay death (0.4%), CSF leak (8.8%), postoperative CSF rhinorrhea (1.9%), diabetes insipidus (12.4%), and meningitis (0.4%). Image guidance was employed in 7% ( $n=3,401$ ) of all cases. When analyzed by modality, CT-assisted procedures had lower CSF rhinorrhea rates (1.1%) compared to cases with no image guidance (1.9%), while MR-assisted procedures and combined-modality procedures had the highest rates (2.7% and 7.6% respectively,  $\chi^2 P<0.001$ ). Rates of CSF leak demonstrated a similar pattern (CT 6.4%, No Image Guidance 8.9%, MR 9.2%, combined-modality 12.8%,  $\chi^2 P<0.001$ ). CT-assisted surgery had significantly shorter length of stay (2.9 days) versus no image guidance (3.7 days,  $p<0.001$ ), lower total charges (\$41,709 vs. \$52,839,  $p<0.001$ ), and lower total cost (\$14,920 vs. \$17,327,  $p<0.001$ ).

Conclusions: CT-assisted surgery is associated with a lower rate of CSF leak, shorter length of stay, and lower cost compared to patients without image guidance. Further studies that control for severity of disease are warranted to confirm this finding.

4:08pm

### **What Does Medicare Pay Rhinologists: An Analysis of Medicare Fee-For-Service Data**

Brandon Clair, BA, Parul Goyal, MD, MBA  
Syracuse, NY, USA

Information about charges and payments for physician services continues to be scrutinized. Recently, CMS

released data regarding Medicare charges and payments to all physicians for calendar year 2012. The purpose of this study was to investigate the variability and patterns in Medicare charges and payments among a large sample of Rhinologists.

Charge and payment data were obtained from CMS data. Data were available for 8,318 practicing Otolaryngologists. Data for Otolaryngologists and Rhinology subsets were extracted. Charges, payments, fee multiplier, and total submitted claims were compared. Unequal variance Two-tailed T-tests were used for analysis.

Mean submitted charges for Rhinologists were \$291,464 compared to \$211,209 for all Otolaryngologists ( $p=.0014$ ). Mean payments to Rhinologists were \$70,172 compared to \$77,275 for all Otolaryngologists ( $p=.24$ ). Fees for services ranged from 1.33 to 14.29 times Medicare reimbursement rates (mean = 4.47). For example, nasal endoscopy charges varied from \$144 to \$1,193. Level 3 outpatient visit charges varied from \$85 to \$524. The fee multiplier was significantly higher for surgical codes compared to office based codes (9.43 vs 3.44,  $p<.001$ ). Academic Rhinologists submitted fewer claims with higher fee multipliers than private Rhinologists ( $p<.001$ ).

The wide availability of Medicare payment information makes it important for physicians to understand how their individual data compares to that of their colleagues. Medicare payments to Rhinologists were comparable to Otolaryngologists as a whole. Charges for services commonly performed by Rhinologists vary widely. Academic Rhinologists submitted fewer claims than their private colleagues, but overall charges and payments were comparable between the two groups.

4:15pm  
Q&A

4:22pm

**Panel: Finding a Common Ground:  
New Technological Advancements vs.  
Medical Economics**

Moderator: Devyani Lal, MD

Panelists: Parul Goyal, MD & Raj Sindwani, MD

4:55pm

**Closing Remarks & Meeting Adjourned**

5:00pm

**Advances in Aerosol Therapy for Patients with Allergic Rhinitis (TEVA 4-Corners Symposium)**

Regency Ballroom Q

Food & Beverage Served

6:30pm

**ARS President's Wine & Cheese Poster Reception and Presidential Address (Supported by Intersect ENT)**

Regency Foyer & Regency Ballroom R





## ORLANDO BALLROOM L

1:00pm

**Welcome:** Donald Lanza, MD  
Orlando Ballroom L Chairperson

### Session Topic: The Microbiome in CRS

Moderators: Lori Lemmonier, MD & Troy Woodard, MD

1:05pm

#### Characterization of Bacterial Microbiome in Chronic Rhinosinusitis Patients at Baseline and During Clinical Exacerbations

Uma Ramaswamy, MD, Nadim Ajami, PhD, Jennifer White, MS, MB(ASCP)CM, Martin Citardi, MD, Amber Luong, MD, PhD, Samer Fakhri, MD  
Houston, TX, USA

Objectives:

1. To characterize bacterial microbiome in patients with chronic rhinosinusitis at baseline and during acute exacerbations using 16S rRNA gene profiling on sinonasal secretions.
2. To identify organismal differences between the previously stated groups.

**Methods:** Asymptomatic patients underwent endoscopic mucosal swab of the middle meatus or open sinus cavity and served as the baseline group. Patients having acute exacerbations underwent endoscopic swab in areas of maximal secretion or mucosal edema. DNA extraction, 16S rRNA gene amplification, and MiSeq-Illumina platform sequencing methods were used for analysis of sinonasal secretions. Taxonomic classification of isolated specimen was achieved using Quantitative Insights Into Microbial Ecology (QIIME) software package and reads were mapped to the SILVA database after quality filtering with USEARCH. Alpha diversity analysis included indices such as Chao, Simpson, and Shannon. Beta diversity analysis was achieved by the UniFrac method. Taxa summary tables were generated for each sample allowing bacterial relative abundance calculations at taxonomic levels of genus and above.

**Results:** A total of 63 samples (baseline, n=29; exacerbation, n=34) were included in the analysis. The diversity of the bacterial community in exacerbation samples was found to be lower when compared to baseline samples ( $p=0.02$ ). *Haemophilus* spp., *Streptococcus* spp., and *Pseudomonas* spp. showed an increase in abundance in exacerbation samples compared to baseline.

**Conclusions:** Our results suggest that the microbiome of CRS patients is significantly different from baseline during exacerbations. CRS exacerbations are associated with bacterial organisms typically implicated with acute bacterial rhinosinusitis.

1:12pm

#### Different Clinical Factors Associated with *Staphylococcus Aureus* and *Pseudomonas Aeruginosa* in Chronic Rhinosinusitis

Zi Zhang, MD, MSCE, Nithin Adappa, MD, Laurel Doghramji, RN, BSN, Alexander Chiu, MD, Noam Cohen, MD, PhD  
James Palmer, MD  
Philadelphia, PA, USA

**Objective:** *Staphylococcus aureus* and *Pseudomonas aeruginosa* are common culture isolates in chronic rhinosinusitis (CRS). It is unclear whether their roles in CRS are different. We aimed to determine whether they were associated with different clinical factors of CRS.

**Methods:** Adult CRS patients who underwent FESS between 10/1/2007 to 12/31/2011 were recruited. Patient demographics, Lund-Mackay CT scores, SNOT-22 scores, disease characteristics, and medication use were collected prior to FESS. Intraoperative culture was obtained in standard manner. We first compared patients with isolates of *S. aureus* to patients with other culture results, and then compared patients with isolates of *P. aeruginosa* to patients with other culture results.

**Results:** 376 patients met criteria. 104 patients (28%) had *S. aureus*, and 32 (9%) had *P. aeruginosa*. Compared to patients with other positive culture, patients with *S. aureus* were significantly more likely to have prior FESS (71% versus 57%,  $p=0.012$ ), nasal polyps (70% versus 56%,  $p=0.014$ ), and had significantly worse Lund-Mackay CT scores (13.76 versus 12.20,  $p=0.036$ ). While patients with *P. aeruginosa* were significantly more likely to have prior FESS (91% versus 58%,  $p<0.001$ ), and diabetes (16% versus 4%,  $p=0.004$ ) as compared to patients with other positive culture. None of the other associations were statistically significant.

**Conclusion:** Although both *S. aureus* and *P. aeruginosa* were associated with high prior FESS rate, *S. aureus* was more common in CRS patients with nasal polyps, while *P. aeruginosa* were more common in CRS patients with diabetes. Empiric antibiotic therapy in patients with these conditions should target different bacteria.

1:19pm

#### Small Colony Variants and Phenotype Switching of Intracellular *Staphylococcus aureus* in Chronic Rhinosinusitis

Neil Tan, MD, PhD, Clare Cooksley, PhD, Amanda Drilling, PhD, Richard Douglas, MD, Peter-John Wormald, MD, Sarah Vreugde, MD, PhD  
Woodville South, South Australia, Australia

**Background:** Chronic rhinosinusitis (CRS) has been linked

to the gram-positive bacteria *Staphylococcus aureus* (*S. aureus*) in its biofilm or intracellular forms. Recent evidence suggests that *S. aureus* also exists in a small colony variant (SCV) form as a mechanism of altering its virulence capabilities. The aim of this study was to investigate the presence of SCVs in sinonasal mucosa of CRS patients and whether the phenomenon of phenotype switching can be applied to intracellular epithelial infections.

**Methods:** Sinonasal specimens were examined for the presence of intramucosal *S. aureus* and characterised to the strain level. An airway epithelial cell culture infection model was utilised to investigate whether bacteria were capable of alterations in virulence phenotype.

**Results:** Intramucosal organisms harvested from sinonasal biopsies demonstrate phenotypic growth patterns and lack of coagulase activity consistent with SCVs. Intracellular infection of airway epithelial cell cultures with *S. aureus* led to decreased secretion of enterotoxins and phenotypic growth alterations consistent with SCVs.

**Conclusions:** Regulation of *S. aureus* virulence factors is a dynamic process and exposure to the intracellular environment appears to provide the necessary conditions to enable these alterations in an attempt for the bacterium to survive and persist within host tissues. Further work is required to ascertain whether SCVs in CRS hold a clinically relevant pathogenic role in recalcitrant disease.

**Key Words:** Chronic rhinosinusitis, Intracellular infection, Phenotype switching, Small colony variant, *Staphylococcus aureus*.

1:26pm

#### **Cousins, Siblings or Copies: the Genomics of Recurrent *Staphylococcus Aureus* Infections in Chronic Rhinosinusitis**

Amanda Drilling, BBtech (Hons), Geoffrey Coombs, PhD, Samuel Boase, BMBS (Hons), PhD, Alkis Psaltis, BMBS (Hons), PhD, Sarah Vreugde, MD, PhD, Peter-John Wormald, MD FRACS  
Woodville, South Australia, Australia

**Background:** *Staphylococcus aureus* infection is known to play a role in recalcitrant chronic rhinosinusitis (CRS). It is currently unknown how persistent infections of *S. aureus* are related. Furthermore, it is unknown whether patient factors (eg. demographics) influence the relation of these persistent infections. This study will therefore investigate and compare the genomics of recurrent *S. aureus* infections in CRS.

**Methods:** Samples were collected from patients with CRS from July 2011 to August 2012. *S. aureus* isolates were obtained either by swabbing the middle meatus of a patient, or isolating *S. aureus* from biofilm present on tissue taken at

the time of surgery. PFGE was used to compare *S. aureus* isolates taken from the same patient.

**Results:** 34 patients were included in the study. 76% showed persistence of the same *S. aureus* strain in their paranasal sinuses ( $p = 0.001$  H1 ? 50%). Furthermore a significantly high frequency of patients with known biofilm status were positive for *S. aureus* biofilm ( $p = 0.002$  H1 ? 50%). When patients were stratified according to disease evolution post-surgery, certain strains appeared to be more commonly associated with symptom persistence.

**Conclusion:** The same *S. aureus* strain appears to persist in the paranasal sinuses of CRS patients despite multiple courses of culture-directed antibiotic. This suggests that conventional antimicrobial therapies in patients with CRS reduce the load of *S. aureus* rather than eliminate it completely. This may be partly explained by the high frequency of *S. aureus* biofilms present in patients colonized with *S. aureus*.

1:33pm

Q&A

Moderators: Naveen Bhandarkar, MD & Nadeem Akbar, MD

1:40pm

#### **Gram-negative Bacterial Carriage in Chronic Rhinosinusitis is not Associated with More Severe Inflammation**

Paul Tabet, Medical Student, Leandra Endam, MSc, Pierre Boisvert, MD, Louis-Philippe Boulet, MD, Martin Desrosiers, MD  
Montreal, Quebec, Canada

**Background:** We have previously demonstrated that failure of functional endoscopic sinus surgery for chronic rhinosinusitis (CRS) is associated with gram-negative bacterial carriage. The mechanisms for this remains unknown. We thus wished to determine whether gram-negative carriage in a nasal population is associated with a more severe inflammatory phenomenon.

**Method:** 337 patients with CRS and nasal polyposis previously phenotyped for genetic association studies including endoscopically-obtained swab cultures were studied. These were separated according to the presence (wGram-) or absence (woGram-) of gram-negative bacterial carriage; demographic parameters and available serum biomarkers (complete blood count, total IgE) were then evaluated. Sub-group analysis for *P. aeruginosa* and non-pseudomonas gram-negative bacteria (Gram-woPseudo) was performed in order to explore potential roles of these subtypes. Student T-test and Fisher's exact test for unpaired samples were used to compare differences between groups.



## ORLANDO BALLROOM L

Results: Gram-negative bacterial carriage was not associated with a difference in demographic parameters or serum biomarkers. However, *P. aeruginosa* carriage was associated with a higher self-reported incidence of asthma (*P. aeruginosa*: 79%, woGram-: 57%;  $p=0.048$ ). Interestingly, serum IgE was increased in the Gram-negative population when *Pseudomonas* species were excluded (Gram-woPseudo: 338 IU/mL, woGram-: 195 IU/mL;  $p=0.026$ ).

Conclusions: Gram-negative bacterial carriage is not associated with higher markers of inflammation. This may be a reflection of a recently described polarization of TLR4 responses to a Th2 phenotype via IL-33 production. Differences in phenotype associated with *Pseudomonas* species carriage suggest a different behavior than other Gram-negative bacteria, supporting the importance of bacteria as disease modifiers in CRS.

1:47pm

### ***Pseudomonas Aeruginosa*, but not *Staphylococcus Aureus*, is an Independent Predictor of Neo-osteogenesis in Patients with Chronic Rhinosinusitis**

Zhenxiao Huang, MD, PhD, Amal Hajjij, MD, Gang Li, MD, PhD, Bing Zhou, MD, Jayakar Nayak, MD, PhD, Peter Hwang, MD  
Stanford, CA, USA

Background: Neo-osteogenesis of the paranasal sinuses is a radiologic finding of unclear clinical significance. Whereas current evidence suggests that these bony changes represent an inflammatory response rather than an infectious osteitis, bacteria associated with the sinonasal mucosa may induce inflammatory mediators as a mechanism of neo-osteogenesis. The objective of this study is to analyze the association between bacteria isolated on sinus culture and neo-osteogenesis on CT scan.

Methods: 90 patients undergoing sinus surgery for medically refractory CRS were recruited. Radiologic evidence of neo-osteogenesis was assessed by the global osteitis scale score (GOSS) and mucosal disease severity was assessed by the Lund Mackay score (LMS). Bacterial culture was obtained endoscopically at the preoperative office visit or during surgery. Multiple and logistic regression models were used to evaluate the association between the number and type of bacterial species isolated, number of previous surgeries, and severity of neo-osteogenesis.

Results: The number of bacterial species identified on culture was significantly associated with neo-osteogenesis ( $p<0.01$ ). *Pseudomonas aeruginosa* was significantly associated with neo-osteogenesis [OR, 3.8, (1.15-12.67)], whereas *Staphylococcus aureus* was not. The number of previous surgeries, especially more than 2, was also associated with

the extent of neo-osteogenesis [OR, 3.48 (1.15-10.54)]. The LMS was also significantly associated with the extent of neo-osteogenesis.

Conclusion: The presence of *Pseudomonas aeruginosa* in the sinuses is an independent predictor of neo-osteogenesis, while *Staphylococcus aureus* is not. The number of bacterial species, the number of previous surgeries, and the LMS are also independently associated with the severity of neo-osteogenesis.

1:54pm

### **The Effect of Antibiotics on the Microbiome in Acute Exacerbations of Chronic Rhinosinusitis**

Mark Merkley, MD, PhD, Alexis Strohl, MD, Tristan Bice, BA, Alex Grier, MS, Steven Gill, PhD, Li Man, MD, MPA  
Rochester, NY, USA

Background: Current treatment of acute exacerbations of chronic rhinosinusitis (CRS) is driven by identification of predominant bacteria by culture-based methods and determination of antibiotic sensitivities. The objective of this study was to evaluate the response of the microbiome to antibiotic therapy in the setting of an acute exacerbation of CRS.

Methods: Aspirate and swab samples for culture and DNA analysis were collected bilaterally from five CRS patients presenting with acute exacerbations. Patients were started on a two-week course of a culture-directed antibiotic after sensitivities were determined. Repeat samples were taken immediately on the completion of treatment. DNA was extracted from each sample, amplified using bacterial 16S primers, and sequenced. Diversity metrics of the microbiota between pre- and post-treatment samples were calculated.

Results: There was significantly more  $\alpha$ -diversity in the post-treatment group than in the pre-treatment group ( $p < 0.05$  in each comparison). The predominant organism identified by 16S sequencing correlated with the culture-identified bacteria genus in each patient. The average relative abundance of the most prevalent bacteria genus identified was higher in the pre-treatment than the post-treatment group (83% to 50%, respectively,  $p < 0.01$ ).

Conclusion: Significant differences exist in the diversity of bacteria populations during acute exacerbations of CRS and after anti-microbial treatment. After therapy, the increase in diversity is accompanied by a decrease in the total of abundance of the bacterial population.

2:01pm

### **The Sinonasal Microbiome in Patients with Cystic Fibrosis**

Alyssa Kanaan, MD, BJ Ferguson, MD, Nivedita Sahu, MD, Nicholas Rowan, MD, Eric Wang, MD, Stella Lee, MD

Pittsburgh, PA, USA

**Introduction:** Cystic fibrosis (CF) patients frequently suffer from refractory and therapeutically challenging chronic rhinosinusitis (CRS). Although *Pseudomonas aeruginosa* and *Staphylococcus aureus* are commonly identified pathogens other microorganisms, not readily cultured, may influence CRS in CF. Molecular identification of microbes presents an alternative, non-growth dependent technique to comprehensively study the flora of the sinuses. Our hypothesis was that evaluation of the sinonasal microbiome in these patients would provide useful information on the bacterial pathogens present which could potentially direct appropriate therapy.

**Methods:** 18 patients with CF were prospectively enrolled in this study. Samples were obtained from the ethmoid sinuses and the microbiome analyzed by pyrosequencing of bacterial 16s ribosomal RNA. Another swab was obtained simultaneously for traditional cultures. Symptom severity was assessed with a validated questionnaire (SNOT 22).

**Results:** Analysis of the sinonasal microbiome by molecular sequencing detected an average of 3 more bacterial species per patient than traditional culture. *Staphylococcus lugdunensis* was identified in 44% of patients. There are no prior reports of this species of bacteria in the sinuses. Patients without mucopurulence (2/4) and corresponding lower SNOT-22 scores had an increased number of bacterial species on sequencing analysis, which may indicate that increased diversity is associated with a protective effect.

**Conclusion:** Molecular sequencing can provide rapid and comprehensive information with the potential to identify new pathogens as well as fluctuations within the microbiome that may play a role in the disease process. Increased diversity was associated with improved endoscopic score and symptom severity.

2:08pm

### **The Role of Viruses in the Clinical Presentation of Chronic Rhinosinusitis**

Nicholas Rowan, MD, Stella Lee, MD, Nivedita Sahu, MD, Alissa Kanaan, MD, Eric Wang, MD  
Pittsburgh, PA, USA

**Introduction:** The role of viruses in chronic rhinosinusitis (CRS) is poorly understood. In part, this is secondary to difficulty in isolating viruses. However, viral screening using molecular sequencing is now both rapid and feasible. This study characterizes the viruses present in the paranasal sinuses of CRS patients and correlates viral presence with clinical indicators.

**Methods:** In this prospective study, 6 patients with CRS with nasal polyposis (CRSwNP) and 5 patients with CRS without NP (CRSSNP) were enrolled. Paranasal sinus swabs underwent molecular screening for viral DNA. Typical symptoms of CRS, the sinonasal questionnaire (SNQ) and objective measures of CRS including the modified Lund-Mackay (mLM) and modified Lund-Kennedy (mLK) scoring systems were obtained.

**Results:** Viruses were found in 27% of CRS patients. All were found in patients with CRSSNP. SNQ scores were higher and the frequency of facial pain and pressure was increased when virus was detected ( $p=0.39$  and  $0.24$  respectively). Despite worse symptoms, both mLM and mLK scores tended to be lower in viral presence ( $p=0.15$  and  $0.84$  respectively).

**Conclusions:** Advances in molecular sequencing allow detection of viruses in the sinonasal tract of CRS patients. Based on these results, viral infection may play a greater role in symptom exacerbation in CRSSNP than in CRSwNP. Viral presence may be associated with worse CRS symptomatology, but less severe objective measures of disease. These findings warrant further investigation into the role of viruses in CRS patients.

2:15pm

Q&A

2:22pm

### **Panel: Making Sense of the Sinonasal Microbiome**

Moderator: Andy Goldberg, MD

Panelists: Martin Citardi, MD & Richard Douglas, MD

2:52pm

### **Break with Exhibitors**

Regency Ballroom R

### **Session Topic: Genomics and CRS**

Moderators: Ashutosh Kacker, MD & Jamie Litvack, MD

3:12pm

### **Genetic Variations in the Integrin A6 Gene and Reduced ITGA6 Expression Suggest Hemidesmosome Dysfunction in Chronic Rhinosinusitis**

Stefania Gallo, MD, Leandra Mfuna-Endam, MSc, Simon Rousseau, PhD, Yohan Bosse, PhD, Emmanuelle Brochiero, PhD, Martin Desrosiers, MD  
Varese, VA, Italy

**Introduction:** Epithelial dysfunction has been postulated as a

## ORLANDO BALLROOM L

mechanism of chronic rhinosinusitis (CRS) and may reflect impairment of epithelial cells, the underlying extracellular matrix (ECM), or the elaborate proteins network responsible for adhesion and signalling between them. Among these, the hemidesmosome unit assures adhesion of epithelial cells to the basement membrane. Gene dysfunctions in components of the hemidesmosome are associated with epithelial dysfunction in KO mice and in humans. We wished to use genomic and transcriptomic tools to assess a potential role of hemidesmosome dysfunction in CRS.

**Methods:** We reviewed existing genome-wide association data from a CRS population for evidence of genetic variations in hemidesmosome constitutive integrins ( $\alpha 6\beta 4$ ) and associated molecules. Support for a functional role for identified candidate genes was verified in primary epithelial cell cultures from CRS and control patients screened using gene expression profiling.

**Results:** The genetic polymorphism rs6714597 in the integrin subunit  $\alpha 6$  gene (ITGA6) showed significant association with CRS (MAF: CRS: 0.3518, Control: 0.2679; OR: 1.483;  $p=0.01463$ ). Gene expression for ITGA6 was significantly reduced in CRS epithelial cells (Fold Change: -2.91,  $p$ -adjusted: 0.00000034). This was more pronounced within a subgroup with epithelial dysfunction and high inflammation molecular signature.

**Conclusion:** There is ample evidence in recent literature that integrin signalling has crucial roles in tissue homeostasis. Dysfunction in integrin-mediated adhesion structures such as hemidesmosomes may represent novel mechanisms for CRS pathogenesis and identify potential new targets for therapeutic intervention. Further studies are required to verify the possible contribution of hemidesmosome dysfunction to CRS pathogenesis.

3:19pm

### **Familial Risk of Chronic Rhinosinusitis With and Without Nasal Polyposis**

Gretchen Oakley, MD, Quinn Orb, BA, Karen Curtin, PhD, Carole Schaefer, BACS, Richard Orlandi, MD, Jeremiah Alt, MD, PhD  
Salt Lake City, UT, USA

**Introduction:** Chronic rhinosinusitis (CRS) is a highly prevalent inflammatory disease, with significant effects on morbidity and quality of life, yet surprisingly little has been accomplished to delineate its pathogenesis. Preliminary evidence suggests there is a heritable component to the multifactorial etiology of CRS; however, our understanding of this genetic susceptibility is limited.

**Methods:** Using an extensive genealogical database linked to medical records, the risk of CRS with nasal polyps

(CRSwNP) and without polyps (CRSsNP) was calculated for relatives and spouses of adult probands (7,500 CRSwNP and 18,254 CRSsNP patients diagnosed 1996-2011) compared to random population controls matched 10:1 on sex and birth year from Cox regression models.

**Results:** First-degree (FDRs) and second-degree relatives (SDRs), as well as more extended relatives, of probands demonstrated a significant increased risk of carrying the same diagnosis compared to controls. FDRs of CRSwNP patients were at 5-fold increased risk ( $P<10^{-15}$ ), while SDRs were at 2.2-fold increased risk ( $P<10^{-15}$ ). In CRSsNP patients, FDRs were at 2.2-fold increased risk ( $P<10^{-15}$ ), while SDRs were at 1.4-fold risk ( $P<10^{-15}$ ). More extended relatives (third- through fifth-degree) had a slight 1.1-fold increased risk ( $P<10^{-2}$ ). Spouses of probands, who likely share environmentally, also exhibited increased risk.

**Conclusions:** In the largest population study to date, a significant familial risk is confirmed in CRSwNP and CRSsNP, which appear to have a genetic and environmental component. Further understanding of the genetic basis of CRS and its interplay with environment factors could clarify the etiology and lead to more effective targeted treatments.

3:26pm

### **TAS2R38 Genotype Predicts Surgical Outcome in Non-polyposid Chronic Rhinosinusitis**

Nithin Adappa, MD, Doug Farquhar, BA, James Palmer, MD, David Kennedy, MD, Doghramji L, NP, Noam Cohen, MD, PhD  
Philadelphia, PA, USA

**Introduction:** The bitter taste receptor T2R38 regulates upper airway innate defenses through nitric oxide production in response to microbial quorum sensing molecules yielding direct bactericidal activity as well as stimulating mucociliary clearance. Previous investigations demonstrated that the robustness of defensive responses is modulated by polymorphisms within the TAS2R38 gene. TAS2R38 also governs taste perception of the compound phenylthiocarbamide (PTC). Based on taste perception, individuals are broadly divided into supertasters, tasters and non-tasters with supertasters having the strongest innate defense response.

**Objective:** Determine whether TAS2R38 genotype is predictive of functional endoscopic sinus surgery (FESS) outcomes.

**Methods:** A prospective study of patients who were genotyped for TAS2R38 at the time of surgery and followed for 6 months after FESS. Post-operative outcomes were determined by the sinonasal outcomes test 22 (SNOT-22), and necessity of oral antibiotics.

Results: 123 patients with chronic rhinosinusitis (CRS) were enrolled in the study. Eighty-two patients demonstrated nasal polyps (CRSwNP) and 41 patients were without nasal polyps (CRSSNP). Six months following surgery, the overall SNOT-22 improvement was 25 points ( $\pm 23$ ): CRSwNP = 30( $\pm 21$ ) and CRSSNP = 16( $\pm 24$ ). Genotype was found to significantly correlate with surgical outcomes in non-polyp patients; supertasters (n=7) had a mean improvement of 38( $\pm 21$ ) while non-supertasters (n=34) had a mean change of 12( $\pm 22$ ) ( $p = 0.006$ ).

Conclusion: This investigation of 123 consecutive surgical patients demonstrates that in CRSSNP, but not in CRSwNP patients, TAS2R38 genotype predicts FESS outcomes as measured by quality of life improvement at 6 months.

3:33pm  
Q&A

## Session Topic: Biomaterials

Moderators: Stacey Gray, MD & Adam Folbe, MD

3:40pm

### **A Randomized, Controlled, Blinded, Multi-Center Study with Bioabsorbable Steroid-Eluting Sinus Implant for In-Office Treatment of Recurrent Sinonasal Polyposis: 3-Month Safety and Efficacy**

Joseph Han, MD, Keith Forwith, PhD, MD, William Brown, MD, Steven Miller, MD, Randall Ow, MD, David Poetker, MD  
Virginia Beach, VA, USA

Introduction: Patients with recurrent sinonasal polyposis after endoscopic sinus surgery (ESS) have limited treatment options. This study evaluated the safety and efficacy of a bioabsorbable steroid-eluting implant to dilate obstructed ethmoid sinuses, reduce polyposis and re-establish sinus patency.

Methods: A randomized, controlled, blinded, multi-center study with 100 ESS patients with CRSwNP refractory to medical therapy. The implant eluted 1350ug of mometasone furoate over 3 months. Follow up included endoscopic grading by clinicians, nasal obstruction/congestion score, ocular exams and need for revision ESS.

Results: Treated patients [n=53, 47.8 (SD 12.6) years of age, 55% male] underwent bilateral in-office placement. Control patients [n=47, 51.6 (13.1) years, 66% male] underwent a sham procedure. Implant delivery was 100% successful. At 3 months treated patients experienced a significant reduction in bilateral polyp grade ( $p=0.0269$ ) and ethmoid sinus obstruction (0.0001) compared to control. Treated patients also experienced a two-fold improvement in the mean nasal obstruction/congestion score [-1.33 (1.47) vs. -0.67 (1.45),

$p=0.1365$ ]. At 3 months 52.8% of treated patients vs. 23.4% of controls were no longer indicated for repeat ESS. There were no serious adverse events nor increase in intraocular pressure or cataracts.

Conclusion: The symptomatic improvement and statistically and clinically significant reduction in both polyp grade and ethmoid sinus obstruction supported the efficacy of a steroid-eluting implant for in-office treatment of CRS patients with recurrent polyposis after ESS. The safety and efficacy results obtained suggest that steroid-eluting implants represent a clinically meaningful alternative to oral steroids and revision surgery for this patient population.

3:47pm

### **Topical Colloidal Silver as an Anti Biofilm Agent in Staphylococcus Aureus Chronic Rhinosinusitis Sheep Model**

Sukanya Rajiv, MS, Amanda Drilling, BBTech(Hons), Ahmed Bassiouni, MBBCh, Peter-John Wormald, MD  
Adelaide, South Australia, Australia

Background: Treatment of chronic rhinosinusitis (CRS) is a challenge with increasing antibiotic resistance, leading to re-emergence of topical silver as an alternative agent. Aim of this study was to assess safety and efficacy of topical colloidal silver solution for treatment of Staphylococcus aureus biofilms in a sheep model of CRS.

Methods: In the safety study, normal saline and 30ppm colloidal silver solution was used to flush the frontal sinuses for 14 days in the control and test arm respectively (four sheep each). In the efficacy study, following inoculation with Staphylococcus aureus, sheep were treated with either control saline or topical silver solution of varying concentrations (30ppm/20ppm/10ppm/5ppm) for five days, with four sheep in each group. Blood silver level, full blood counts and biochemical parameters were analyzed in both safety and efficacy studies. Further, sinus tissue was harvested for histological examination and ciliary structure analysis in safety and for biofilm biomass quantification by FISH technique and COMSTAT 2 software in the efficacy study.

Results: Sheep treated with silver showed a significant decrease in biofilm biomass compared to saline control across all concentrations ( $p<0.001$ ). Though, average blood silver levels were higher in the treated groups ( $p<0.05$ ), blood counts and biochemical parameters were within normal limits in all. Further, histology and ciliary structure analysis did not show any difference between control and treatment groups.

Conclusion: Topical colloidal silver solution has effective anti-biofilm activity in Staphylococcus aureus CRS in a sheep model and appears safe and non-toxic.



## ORLANDO BALLROOM L

3:54pm

### **The Effects of Topical Agents on Paranasal Sinus Mucosa Healing: A Rabbit Study**

Ravi Jain, MBChB, Raymond Kim, MBChB, Sharon Waldvogel-Thurlow, Cert. MLT, Peter Hwang, MD, Jillian Cornish, PhD, Richard Douglas, MD  
Auckland, Auckland, New Zealand

**Background:** Numerous topical agents are used intra-operatively to improve postoperative mucosal healing. However, the histological effects of these treatments have not been well characterized. We have investigated the impact of topical mometasone, acitretin, lactoferrin and Silastic on sinus mucosa healing in a rabbit model.

**Methods:** Forty-eight New Zealand white rabbits underwent defined, localized stripping of a bilateral region of maxillary sinus mucosa. One of six treatments was placed in one maxillary sinus, and the treatment carrier applied contralaterally (0.1% mometasone, 0.25% and 0.5% acitretin, lactoferrin, Silastic and no treatment, n=8 each group). Rabbits were euthanized after two weeks and examined with light microscopy to determine mucosal thickness, epithelial thickness, density of collagen, number of goblet cells and ciliary recovery.

**Results:** Rabbit sinuses treated with acitretin 0.25% and 0.5% had significantly improved ciliary recovery over the contralateral placebo ( $p < 0.01$  and  $p < 0.05$  respectively). Rabbits treated with 0.25% acitretin were found to have significantly less collagen in healing mucosa ( $p < 0.05$ ). Conversely, rabbits treated with mometasone were more likely to have reduced ciliary and goblet cell recovery. The mometasone group had more regions of denuded bone than any other group. Inter group comparisons demonstrated a significant improvement in ciliary recovery with both acitretin doses over 0.1% mometasone ( $p < 0.05$ ) and less collagen deposition in rabbits treated with placebo gel over Silastic ( $p < 0.05$ ).

**Conclusions:** Intra-operatively used agents have the potential to significantly affect wound healing. Acitretin may improve ciliary recovery and reduce collagen deposition.

4:01pm

### **Chitosan Does Not Interfere with Normal Wound Healing in Post-Surgical Sinus Cavities**

Mary Czerny, MD, Suhael Momin, MD, Justin Antisdell, MD, John Long, DVM, Raj Sindwani, MD  
Saint Louis, MO, USA

**Introduction:** Although absorbable packing materials are commonly used following endoscopic sinus surgery (ESS), some have been shown to negatively impact mucosal healing. Chitosan is a new bioabsorbable agent that has

been shown to be effective at hemostasis, but its impact on healing sinus cavities is unknown. This study examined the effects of chitosan on mucosal healing using an established rabbit model.

**Methods:** Prospective, controlled study of 16 rabbits. Maxillary sinuses were opened surgically, a controlled mucosal lesion was created in 6 animals, and the mucosa was completely stripped in the remainder. Sinus cavities were treated with chitosan, Floseal or saline (controls). Animals were recovered and sacrificed after 1, 2, or 4 weeks. Specimens were examined and scored by a blinded pathologist using light microscopy.

**Results:** At 1 week, sinuses treated with either hemostatic agent trended toward higher levels of foreign body reaction compared to saline controls, but this reaction dissipated completely in the chitosan group by 2 weeks. Floseal-treated sinuses showed significantly greater levels of foreign material in the mucosa relative to chitosan ( $p=0.03$ ) or saline-treated sinuses ( $p=0.04$ ) at 2 weeks. There was no statistically significant difference in inflammatory changes evaluated (epithelial degeneration, ciliary loss, granulation tissue, fibrosis or foreign body reaction) between chitosan and control sinuses at 2 or 4 weeks post-procedure.

**Conclusions:** Chitosan-treated sinuses were not significantly different than those treated with saline, suggesting that chitosan is a relatively inert hemostatic agent for ESS. Chitosan placed in post-surgical sinuses does not appear to interfere with normal wound healing.

4:08pm

### **Probiotic Instillation Delays Pseudomonas Aeruginosa Induced Sinusitis and Translocation to the Lower Airways in a Murine Model**

Emily Cope, PhD, Andrew Goldberg, MD, Steven Pletcher, MD, Susan Lynch, PhD  
San Francisco, CA, USA

**Introduction:** Progressive lung disease characterized by microbial colonization and inflammation causes significant mortality in cystic fibrosis (CF) patients. Evidence suggests that *P. aeruginosa* (PA) colonizes CF sinuses, acting as a reservoir for lung infection. We sought to determine the effects of PA infection on the murine sinuses and investigate bacterial translocation to the lungs. We also hypothesized that the probiotic, *Lactobacillus sakei* (LS), could prevent sinusitis and delay bacterial translocation.

**Methods:** Fifty mice (5/group) received intranasal inoculations of PBS, PA, or PA and LS. Sinuses were stained for goblet cell enumeration. Microbiome analysis of sinuses and lungs was performed using the Illumina MiSeq.

Results: Nasal administration of PA caused goblet cell hyperplasia within the sinuses ( $p < 0.001$ ). *Pseudomonas* was enriched in the sinuses and lungs ( $p < 0.05$ ,  $q < 0.05$ ) at day-one post-infection (D1PI). Goblet cells returned to normal by day 10 (100% reduction), but *Pseudomonas* remained enriched in the sinuses and lungs ( $p < 0.05$ ,  $q < 0.05$ ). Co-instillation with LS decreased goblet cell hyperplasia by 58.4% ( $p < 0.001$ ) and prevented enrichment of *Pseudomonas* in both the sinuses and lungs at D1PI. Sinus and lung microbiota were similar in PA-infected mice at D1PI, but dissimilar in healthy mice or those co-instilled with LS ( $p < 0.05$ ). Translocation of PA occurred in all groups of infected mice after seven days.

4:15pm  
Q&A

4:22pm

### **Panel: Practical Considerations for Biomaterials and Genomics in CRS**

Moderator: Richard Orlandi, MD

Panelists: Steven Pletcher, MD & David Poetker, MD

4:55pm

Closing Remarks & Meeting Adjourned

5:00pm

### **Advances in Aerosol Therapy for Patients with Allergic Rhinitis (TEVA 4-Corners Symposium)**

Regency Ballroom Q

Food & Beverage Served

6:30pm

### **ARS President's Wine & Cheese Poster Reception and Presidential Address (Supported by Intersect ENT)**

Regency Foyer & Regency Ballroom R







## POSTERS

Poster # 001

**19 Year Experience with Acute Invasive Fungal Rhinosinusitis**

Suhael Momin, MD  
 Janalee Stokken, MD, Troy Woodard, MD  
 Raj Sindwani, MD  
 Cleveland, OH  
 USA

Objective: Acute invasive fungal rhinosinusitis (AIFR) is an aggressive disease with high mortality and morbidity. We review our institutional experience over 20 years to identify patient factors as well as interventional strategies that affect overall patient outcome.

Design: Retrospective case series.

Methods: Charts were reviewed to identify patient and intervention factors which may influence patient outcome.

Results: 27 patients were treated. 16 had an underlying hematologic malignancy, 5 had diabetes, 2 were medically immunosuppressed, 1 had a non-hematologic malignancy, 1 had CVID and 2 were leukopenic from unknown causes. The most common presenting symptoms were facial edema (70%) and facial pain (56%). The most common pathologic agents were *Aspergillus* (13 patients) and *Mucorales* species (9 patients).

All patients were treated surgically, with 55% entirely endoscopic, 41% combined endoscopic/open and 4% open exclusively. The type of intervention did not affect disease clearance. 52% of patients cleared their initial disease. The 1 year overall survival was 36.7%. Altered mental status at presentation and intracranial extension were associated with higher mortality ( $p = 0.03$ ,  $p = 0.01$ ). Patients with medical immunosuppression had higher survival ( $p = 0.03$ ). Malignancy was associated with disease-specific death (58.8% vs 30% mortality), although this was not statistically significant ( $p = 0.14$ ).

Conclusions: AIFR has high short-term mortality. Despite good initial disease clearance, there is poor 1-year all-cause survival. This reflects the overall poor health condition of AIFR patients. Reversibility of the underlying disease state may affect disease clearance and overall survival.

Poster # 002

**A Novel Imaging Tool for Staging Chronic Rhinosinusitis: Correlation with Nasal Symptoms**

Jonathan Garneau, MD  
 Jayant Pinto, MD,  
 Michael Ramirez, Medical Student,  
 Samuel Armato, PhD  
 Fuad Baroody, MD  
 Pittsford, NY  
 USA

Objectives: The Lund-MacKay (LM) scoring system does not correlate with clinical parameters, likely due to its crude scale. We developed a "Modified Lund MacKay" (MLM) system which uses a 3D, computerized method to quantify the volume of mucosal inflammation in the sinuses, and sought to determine whether the MLM would correlate with symptoms and disease specific quality of life.

Methods: We obtained Total Nasal Symptom Score (TNSS) and Sinonasal Outcomes Test (SNOT-22) data from 55 adult subjects immediately prior to sinus imaging. The volume of each sinus occupied by mucosal inflammation was measured using MATLAB algorithms created using customized, image analysis software after manual outlining of each sinus. We used linear regression to model the relationship between the MLM and SNOT-22 and TNSS. We also tested correlation between the LM and MLM using Spearman's rank.

Results: Adjusting for age, gender, and smoking, we found that higher symptom burden was associated with increased sinonasal inflammation as captured by the MLM ( $\beta=0.4529$ ,  $P<0.013$ ). As expected due to the differences in scales, the LM and MLM scores were significantly different ( $P<0.011$ ). There was no association between MLM and SNOT-22 scores.

Conclusion: The MLM is one of the first imaging scoring systems that correlates with sinus symptoms. Further development of this custom software, including full automatization and validation in larger samples, may yield a biomarker with great utility for both treatment of patients and clinical trials.

Poster #003

**A Novel Use of a Steroid-eluting Stent in the Treatment of Choanal Stenosis, a Case Report**

Joel Stanek, BA  
Holly Boyer, MD  
Minneapolis, Minnesota  
USA

Introduction: Congenital choanal atresia is an uncommon craniofacial malformation of the posterior nasal aperture resulting in airway obstruction. The treatment is surgical, but the use of postoperative stenting to maintain patency in choanal atresia repair remains controversial. We describe the case of a patient undergoing unilateral revision endoscopic choanal atresia repair with stenting of the surgical site using a steroid-eluting stent.

Methods: A case report and literature review.

Results: The patient is a 42-year-old female who underwent transpalatal repair of a right-sided choanal atresia in childhood with revision at age 39. She again experienced recurrent nasal obstruction and was referred to our facility for definitive management of a 75% circumferential stenosis. Following revision surgery, a steroid-eluting stent was deployed within the right choana. At 3 months, postoperative visualization revealed excellent patency of the right choana and at 9 months the patient verbalizes no symptoms of ipsilateral obstruction.

Conclusion: This case report presents the novel application of steroid-eluting stents as a potential adjunct for the otolaryngologist in the context of choanal atresia and stenosis repair to maintain postoperative patency.

Poster #004

**A Novel Use of Collagen Matrix Grafts for Recalcitrant Chronic Maxillary Sinusitis**

John Frederick, MD  
Christopher Thompson, MD  
Jeffrey Suh, MD  
Los Angeles, CA  
USA

Introduction: Effective sinonasal mucociliary clearance is essential to prevent stasis of secretions and the development of chronic rhinosinusitis. Many patients are predisposed to having defective mucociliary transport. Other patients can develop defective mucociliary clearance after resection, mucosal stripping, and adjuvant radiation therapy (XRT). Despite wide post-surgical anrostomies and adequate medications, patients with inherently defective mucociliary clearance may have refractory CRS.

Synthetic collagen matrix grafts are currently used successfully for reconstruction of the anterior skull base and for CSF leak repair with excellent remucosalization. We present a novel use for synthetic collagen matrix grafts in which the grafts were used to replace maxillary sinus mucosa in two patients with recalcitrant sinusitis. One patient had a medical history significant for PCD. A second patient developed chronic maxillary sinusitis after sinonasal tumor resection and XRT. Both patients' symptoms and nasal endoscopy exams significantly improved after placing synthetic collagen matrix grafts in the maxillary sinus.

Methods: A retrospective review was performed of two patients with CRS refractory to surgery and medical therapies whose maxillary sinus mucosa were stripped then replaced with synthetic collagen matrix grafts. Pre- and Post- SNOT-22 questionnaires are presented, as well as Lund-Kennedy endoscopic scores.

Results: Both patients' maxillary sinuses had near-complete resolution of edema, with complete cessation of polyps, crusting and mucopurulence at a mean of 9.5months post-operatively. Pre- and post-operative histopathological analysis will be discussed.

Conclusion: Synthetic collagen matrix grafting may be a valid treatment option for recalcitrant sinusitis in patients with a predisposition of defective ciliary transport.

## POSTERS

Poster #005

**A Systematic Review and Meta-analysis of Probiotics for the Treatment of Allergic Rhinitis**

Alexander Zajac, MD  
 Austin Adams, MD  
 Justin Turner, MD PhD  
 Nashville, TN  
 USA

**Objective:** Probiotics have proven beneficial in a number of immune-mediated and allergic diseases. Several human studies have evaluated the efficacy of probiotics in allergic rhinitis, however, evidence for their use has yet to be firmly established. The current systematic review seeks to synthesize the results of available randomized trials.  
**Study Design:** Systematic review and meta-analysis.

**Methods:** The PubMed, Google Scholar, and Cochrane databases were reviewed and randomized controlled trials were extracted based on defined inclusion criteria. The effect of probiotics on Rhinitis Quality of Life (RQLQ) scores, as well as total and antigen-specific serum IgE levels was evaluated by meta-analysis.

**Results:** A total of 24 studies with 1975 patients were identified, including 21 double-blind randomized controlled trials, one single-blind trial, and 2 randomized crossover studies. Multiple probiotic strains, study populations, and outcome measures were utilized in individual trials. Eighteen studies showed a significant clinical benefit from the use of probiotics in at least one outcome measure when compared to placebo, while 6 trials showed no benefit. Among the trials eligible for meta-analysis, the use of probiotics resulted in significantly improved RQLQ scores compared to placebo [standard mean difference (SMD) -2.23; p=0.02]. The use of probiotics did not affect total IgE [SMD 0.01; p=0.96] or antigen-specific IgE [SMD 0.12; p=0.33] levels.

**Conclusions:** Probiotics may be beneficial in improving symptoms and quality of life in patients with allergic rhinitis, however, current evidence suffers from high heterogeneity and variable study outcome measures. Additional high-quality studies are needed to establish appropriate recommendations.

Poster #006

**Accuracy of Intraoperative Margins in Endoscopic Anterior Skull Base Resection**

Ralph Abi Hachem, MD  
 Zoukaa Sargi, MD  
 Roy Casiano, MD  
 Miami, FL  
 USA

**Objectives:** To evaluate the accuracy and limitation of intraoperative margins in endoscopic anterior skull base resection and compare them to permanent margins.

**Methods:** Retrospective chart review identifying thirty-eight patients undergoing endoscopic anterior skull base resection for malignant tumors at a tertiary care medical center between January 2007 and January 2014. All intraoperative frozen and final margins were analyzed and compared. Survival was evaluated by Kaplan Meier analysis.

**Results:** The most common tumor was olfactory neuroblastoma followed by adenocarcinoma. Total number of frozen margins was 229 for 34 patients. Three (1.3 %) frozen margins were positive in 2 patients (6.06%). These were located at the sella and at the falx cerebri. Total number of permanent margins was 237. Sixteen margins (6.75%) were positive in 8 different patients (11.11%). The concordance rate between frozen and permanent margins was 93.75% (Mc Nemar's test=0.15). Kaplan Meier survival analysis showed a mean survival of 35.2 months.

**Conclusions:** Frozen margins taken during endoscopic anterior skull base resection are accurate at assessing the oncological limits of the resection for malignant tumors.

Poster #007

**Adenoid Hypertrophy: Is Helicobacter Pylori Really Present on Adenoid Tissue on Paediatric Patients?**

Eleazar Graterón, MD  
Diana Ortiz, PhD  
María Cavazza, PhD  
Sinay Ceballos, MD  
Caracas, Miranda  
Venezuela

**Objective:** To determine H. pylori presence on adenoids of paediatric patients with Adenoid Hypertrophy.

**Methods:** Adenoid tissue obtained from 28 children from paediatric otorhinolaryngology practice of "Dr. Domingo Luciani" Hospital, who underwent surgery (Adenotonsillectomy) and processed by means of polymerase chain reaction (PCR) using cagA, vacA and babA, also Giemsa stain anatomopathological examination, socioeconomic condition using the Graffar scale and associated gastrointestinal symptoms were assessed.

**Results:** No evidence of Helicobacter pylori in adenoid tissue was found using PCR and Giemsa stain, the most frequently found symptoms were: diarrhea in 17.9%, distension and abdominal pain in 10.7%, 64.3% of the patients were in working (28.6%) and low middle (35.7%) classes.

**Conclusions:** Helicobacter pylori is not present in adenoid tissue of pediatric patients, and is advisable to rule out infection in pediatric patients in the setting of recurrent distension and abdominal pain.

**Key words:** Helicobacter pylori, Adenoid Hypertrophy.

Poster #008

**An Evaluation of Invasive Fungal Sinusitis Outcomes**

Iloreta Alfred, MD  
JP Foshee, MS  
Chris Luminais, MS  
James Evans, MD  
Marc Rosen, MD  
Gurston Nyquist, MD  
Philadelphia, PA  
USA

**Objective:** Invasive fungal rhinosinusitis is an aggressive mycosis of the sinonasal cavity with frequent extension to adjacent facial and cranial structures. The most commonly implicated fungal organisms, Mucor and Aspergillus, typically occur in immunocompromised individuals, such as hematologic malignancy patients or uncontrolled diabetics. Prognosis is typically poor despite aggressive treatment, and mortality due to associated comorbid conditions is not uncommon. This study aims to examine post-operative outcomes and survival of a cohort of fungal sinusitis patients at an academic center.

**Methods:** Patient charts and departmental records were reviewed to identify potential study candidates. Chart reviews yielded patient demographics, medical and surgical treatments, pathology records, and outcomes data.

**Results:** Twenty-six patients were identified from departmental records between 2009 and 2014. Twenty presented with Mucor infections, while the remaining six patients had Aspergillus. Overall Mortality was 58% in our series. Most common presentations were facial pain and vision changes, not specific for either infection. Mortality rates between the two were comparably poor, 70% of Mucor patients died, while 50% of Aspergillus patients died. No correlation was identified between survival and negative intraoperative frozen section margin analysis. All patients were taken back for subsequent debridement(s). Mortality rate amongst the diabetic patients (n=14) and hematologic malignancy patients (n=12) were 50% and 70% respectively.

**Conclusions:** Despite aggressive surgery and negative margins on surgical resections, overall prognosis remains universally guarded for patients with acute invasive fungal sinusitis. Immunocompromised patients with rhinosinusitis and febrile neutropenia require early detection and aggressive multimodal therapy treatment.



## POSTERS

Poster #009

**Anatomic Relationship of Nasolacrimal Duct and Major Lateral Wall Landmarks: Cadaveric Study with Surgical Implications**

Alkis Psaltis, MD PhD  
 Mohammed Ali, MD  
 Jayakar Nayak, MD,PHD  
 Reza Vaezeafshar, MD  
 Gang li, MD,PHD  
 Adelaide, South Asutralia  
 Australia

**Background:** Detailed knowledge of the anatomic landmarks of the lateral nasal wall is important for safe endoscopic sinonasal surgery. We sought to determine the relationship of major landmarks to the nasolacrimal duct.

**Methods:** Twenty mid-sagittal cadaveric head sections were studied. The insertion of the alar cartilage into the maxilla was taken as a fixed point and all measurements were performed in a defined axial plane at the level of the maxillary sinus ostium. Two surgeons independently recorded each measurement three times with an average of the readings used

**Results:** The overall inter-observer agreement index was excellent ( $r=0.84$ ). At the level of maxillary ostium, the mean distance from the alar rim to the nasolacrimal duct (NLD) was  $43.05 \pm 4.76$  mm on the right and  $41.25 \pm 4.56$  mm on the left. The most anterior projection of the middle turbinate head was noted to be anterior to the NLD in 70% of specimens. The maxillary line was posterior to the NLD in 55%, whereas the bulla ethmoidalis and the free edge of uncinat process were uniformly posterior to the NLD in all the specimens.

**Conclusion:** This study provides useful anatomic and positional relationships between the nasolacrimal duct and major lateral wall landmarks. Although the maxillary line and the head of the middle turbinate are often considered useful guides to the position of the ipsilateral NLD, their spatial relationship to the NLD is not consistent. These landmarks therefore cannot be solely relied upon during surgery to avoid injury to the nasolacrimal duct.

Poster #010

**Anatomic variants of the sphenoid sinus are present more frequently in patients requiring revision sphenoid surgery**

Jose Gurrola II, MD  
 Thomas Holmes, BS  
 David Jang, MD  
 Joshua Yelverton, MD  
 Stilianos Kountakis, MD, PhD  
 Augusta, GA  
 USA

**Introduction:** Anatomic variants can complicate sinus surgery and can possibly influence surgical outcomes. This study examines the incidence of sphenoid anatomical variations in patients undergoing revision sphenoid surgery.

**Methods:** A total of 37 patients who underwent sphenoid surgery at a tertiary institution were evaluated. The incidence of anatomic variants in patients requiring revision sphenoid surgery, such as superior turbinate concha bullosa, onodi cells and intersinus sphenoid septae, were evaluated and compared to the incidence of anatomic variants in patients successfully treated with primary sphenoid surgery who did not require revision.

**Results:** Fourteen of 37 patients (37.8%) underwent primary surgery while 23 (62.2%) required revision. Anatomic variants were present in 22 of 23 (95.7%) of patients requiring revision sphenoid surgery compared to only 4 of 14 (28.6%) who did not require revision (chi-square value: 4.37, p-value: 0.036).

**Conclusion:** Anatomic variants were encountered at a statistically significant higher frequency in patients requiring revision sphenoid surgery compared to those who did not. The presence of anatomic variants may influence outcomes in patients requiring sphenoid surgery.

Poster #011

### **Anatomical Variations in The Ethmoid Sinus Roof**

Taisuke Hamasaki, MD PhD

Yasuyuki Hinohira, MD PhD

So Watanabe, MD, PhD

Yoshiyuki Kyo, MD, PhD

Isao Suzuki, MD, PhD

Yoshiyuki Kadokura, MD, PhD

Yokohama, Kanagawa

Japan

**Objectives:** Prevention of the skull base injury is significant for endoscopic endonasal sinus surgery (ESS) as same as the orbital injury. Development of the instruments including high definition camera, high resolution monitor, and image guide system has been contributing to decrease of such complications. However, it is still valuable for ESS surgeons to know anatomical variations in the skull base.

We evaluated the anatomical variations in the ethmoid sinus roof regarding the height and the relation to the septum and the frontal sinus.

**Materials & Methods:** 233 patients who underwent ESS were enrolled in this study. The height of the ethmoid sinus roof, extent of the septum deviation, and the pneumatization of the frontal sinus were measured in both sides using computed tomography (CT) before surgery. The height of the ethmoid sinus roof was classified into the three types according to Keros.

**Results:** Keros type II was frequent (79%), and type I (16.5%) and type III (4.5%) followed. The left side of the ethmoid sinus roof was higher than the right side in 39.5% of the patients although the right side was higher in 13.2%. These results had no relation to extent of the septum deviation and the pneumatization of the frontal sinus.

**Conclusion:** There are anatomical variations in the skull base because of the difference of the height of the ethmoid sinus roof. This study using CT provides valuable information for us in ESS.

Poster #012

### **Balloon Sinus Dilation vs. Medical Management for Chronic Rhinosinusitis: Interim 24-Week Results from a Prospective, Multicenter Study**

Spencer Payne, MD

JP Stolovitzky, MD

Keith Matheny, MD

Boris Karanfilov, MD

Christopher Melroy, MD

Charlottesville, VA

**Introduction:** While prior studies of balloon sinus dilation (BSD) have demonstrated safety and efficacy, data comparing BSD with continued medical management (MM) are lacking. The objective of this study was to evaluate the outcomes of BSD versus MM for patients with chronic rhinosinusitis (CRS) for whom MM has failed.

**Methods:** Adult patients with CRS failing a minimum of 3 weeks of oral antibiotics, 4 weeks of daily saline therapy and 4 weeks of daily nasal corticosteroids were included. Qualifying subjects were allowed to self-select BSD (either office or operating room setting) or continued MM. The primary outcome was the mean change in the Chronic Sinusitis Survey (CSS) score from baseline to 24 weeks. Secondary endpoints include comparisons of change for the Rhinosinusitis Disability Index (RSDI) and the Sino-nasal Outcome Test (SNOT-20).

**Results:** 166 subjects were enrolled (120 BSD and 46 MM). 70% of BSD subjects chose an office setting and dilation was successful in 468/479 sinuses (97.7%). Subjects with data available at both baseline and 24 weeks (85 BSD and 46 MM subjects), showed a significantly greater improvement in CSS for BSD versus MM (44.0 vs. 28.1,  $p < 0.01$ ). RSDI and SNOT-20 improvements for BSD vs. MM showed similar results (RSDI: 39.0 vs. 17.0,  $p < 0.001$ , SNOT-20: 1.7 vs 0.9,  $p < 0.01$ ).

**Conclusion:** Patients selecting BSD enjoy significantly greater improvements in quality of life compared to those electing continued MM. These interim results are achieved through office based procedures in the majority of patients.

## POSTERS

Poster #013

**Can Sinus Anatomy Predict Quality of Life Outcomes and Operative Times of Endoscopic Sinus Surgery?**

Adam DeConde, MD  
Michelle Barton, BA  
Jess Mace, MPH, CCRP  
Timothy Smith, MD, MPH  
San Diego, CA  
USA

**Introduction:** Endoscopic sinus surgery (ESS) can manipulate sinus anatomy, but with limitations due to skull base and orbit anatomy. These anatomical structures dictate the maximal extent of ESS in the frontal recess and may limit surgical extent or operative duration. This study investigates the impact of these anatomical constraints on operative time and quality-of-life (QOL) outcomes.

**Methods:** Patients with medically refractory chronic rhinosinusitis undergoing Draf IIa frontal ESS were prospectively enrolled. Anatomic measurements of the frontal sinus anatomy were collected during computed tomography review and included: widest distance between the frontal beak and posterior table, narrowest point in the ethmoid bed, Keros height, presence of an anterior ethmoid artery on a mesentery, and presence of inter-sinus septal cells. Primary outcomes included mean operative time and improvement in SinoNasal Outcome Test (SNOT-22) survey scores.

**Results:** 63 adult participants were enrolled and followed 13.8(5.2) months on average. The ethmoid bed mean width was 7.2(1.4)mm., the mean distance from frontal beak to the posterior table at widest was 9.0(2.7)mm., and mean Keros height 5.1(1.8)mm. 49/63(77.8%) of participants had inter-sinus septal cells and 30/63(47.6%) had anterior ethmoid arteries on a mesentery. Mean operative time was 121.5(44.0) minutes while SNOT-22 scores significantly ( $p<0.001$ ) improved 26.1(21.6) on average. Anatomic measurements were not predictive of operative time or mean QOL change ( $p>0.050$ ).

**Conclusion:** Frontal sinus surgery is an effective treatment for a range of frontal and ethmoid sinus anatomy. Further study with larger sample size and measures of more restricted anatomy might elucidate treatment limitations of ESS.

Poster #014

**Candida Krusei Fungal Sinusitis in an Immune-Competent Patient: A Case Report**

Patrick Cleveland, BS  
Jeb Justice, MD  
Gainesville, Florida  
USA

**Introduction:** *Candida krusei* is a rare resistant Candidal species that usually affects the immunocompromised, we present a case of *Candida krusei* sinusitis in a non-immunocompromised patient and provide a current literature review.

**Methods:** The current literature was systematically reviewed, and the patient's clinical course was described.

**Results:** A 43 year-old man presented with a 3 month history of nasal regurgitation and nasal pain. Endoscopy and Imaging revealed inflammation without necrosis or pus, near total septal perforation, a 1cm perforation at the hard-soft palate junction, and stenosis of the posterior soft palate to the pharyngeal walls. He initially denied recent drug use. Comprehensive metabolic panel, complete blood counts including absolute neutrophil counts, HIV testing, and auto-immune labs were normal. The only abnormality found was opiates on urine toxicology. With further questioning after surgery, the patient admitted to crushing and snorting hydrocodone in the recent past. Full bilateral FESS and biopsies were performed, revealing inflammation, but no lymphoma, granulomas, vasculitis, or invasive fungus. Post operative course was complicated by a thick, white, chalky, exudate in the nose and sinuses that was repeatedly culture positive for *Candida krusei* despite topical and systemic culture directed therapies.

**Conclusions:** *Candida krusei* is a rare fungal infection that is resistant to oral anti-fungal agents. It may require aggressive and often serial debridement, and targeted anti-fungal management. *Candida krusei* sinusitis has been reported in the literature twice and only in immune compromised patients. Clinicians should be aware of it and speculate it on cultures to improve management.

Poster #015

**Case-Control Analysis of Survival in Sinonasal Carcinosarcoma**

Tapan Patel, BS  
Max Piitt, BS  
Kartik Dandu, MD  
Alejandro Vazquez, MD  
Jean Eloy, MD  
Newark, NJ  
USA

**Background:** Carcinosarcoma is a rare malignant tumor of mixed epithelial and mesenchymal origin. In the head and neck, carcinosarcoma most commonly affects the salivary glands. Primary sinonasal carcinosarcoma (SN-CS) is exceedingly rare.

**Methods:** Retrospective analysis of 15 cases of SN-CS obtained from the Surveillance, Epidemiology and End Results (SEER) database from 1973-2010. A case-matched cohort of salivary gland CS was used for comparison.

**Results:** Women made up 60% of the cohort and whites 73%. Tumors originated in the nasal cavity in 46.7% of cases, and from the maxillary sinus in 33.3%. In 66.7% of cases, tumors were poorly differentiated (grades III-IV). Surgery and radiation therapy was the primary treatment modality in 46.7% of cases. Five-year disease-specific survival was 48.46% for SN-CS, compared to 65.46% for salivary CS with the case-matched cohort; however, this difference was not statistically significant ( $p=0.4471$ ).

**Conclusion:** SN-CS is a rare tumor. Here we present the largest known cohort of sinonasal carcinosarcoma and report on its demographic, clinicopathologic and survival features.

Poster #016

**Causes of Failure Identified in a Case Series of Revision Endoscopic Sinus Surgery**

Francesco Egro, MBChB, MRCS, MSc  
Bewick Jessica, MRCS DOHNS  
Masterson Liam, MD, MRCS, DOHNS  
Philpott Carl, FRCS  
Gorleston, Norfolk  
United Kingdom

**Background:** The national Sinonasal Audit demonstrated that up to 20% of patients undergoing endoscopic nasal polypectomy with or without sinus surgery, underwent revision surgery within 5 years. This presents a burden of revision surgery to the health care system.

**Aims:** The aim of this study was to reflect on the common findings and causes of failure in patients with CRSwNPs undergoing revision endoscopic sinus surgery at a tertiary centre.

**Methods:** A retrospective review of all patients who underwent revision ESS between January 2011 and December 2013 was performed.

**Results:** A total of 75 patients underwent revision endoscopic sinus surgery using image guidance. Common findings at the time of revision surgery included 64% ( $n=48$ ) with residual uncinata process(es), 47% ( $n=35$ ) had a maxillary antrostomy that was not based on the natural ostium of the maxillary sinus, 29% ( $n=22$ ) had an oversized antrostomy, 35% ( $n=26$ ) had middle turbinates resected, 15% ( $n=11$ ) had middle meatal stenosis, 29% ( $n=22$ ) had synechiae, 13% ( $n=10$ ) had osteitic bone requiring drilling, and 17% ( $n=13$ ) had septal perforation and only one of the patients had had a frontal sinusotomy in the presence of frontal sinus disease. The percentage of revision cases of all sinus surgery performed in our unit was 28% (75 out of 272).

**Conclusions:** This study demonstrated a number of frequent errors encountered in revision surgery and may suggest a need for improvement in training in ESS as well as highlighting the burden that surgical failures present to the health care system.

## POSTERS

Poster #017

**Cemento-ossifying Fibroma of the Orbit**

Christopher Le, MD  
 Brad Strong, MD  
 Sacramento, CA  
 USA

Cemento- Ossifying Fibroma (COF) is a benign fibro-osseous-tumor that the WHO classifies as a fibro-osseous neoplasm derived from mesenchymal blast cells of the periodontal ligament consisting of fibrous tissue, cement, and bone. These lesions can arise from any part of the craniofacial skeleton, although the majority of the cases occur in the maxilla and mandible. However, there are case reports of tumors in the ethmoid, temporal, frontal or even long bones of the body. They are slow growing, have a female predominance, and present in the third and fourth decade, and asymptomatic until progression leads to facial asymmetry or mass effect. They are treated with complete surgical resection. We encountered a patient with an unusual location of COF isolated to the orbit. He was a 20 year old man who presented with a 1 year history of left sided proptosis without visual defects. CT and MRI scans revealed a 4 cm well circumscribed thinly calcified mass arising from the diploe of the roof of the left orbit without bony erosion or intracranial invasion. He was brought to the operating by ENT and Neurosurgery for a frontal craniotomy approach for resection of orbital roof/skull base tumor and reconstruction with titanium mesh and peri-cranial flap. The final pathology showed COF. The 6 month post-op CT/MRI scans revealed no recurrence. He had good post op cosmesis and no visual defects. This clinical case demonstrated a unique location of COF isolated to the orbit without paranasal origin/ involvement appropriately managed with complete surgical resection.

Poster #018

**Chronic Rhinosinusitis and Olfactory Dysfunction: Investigating the Role of Superior Airflow Patterns**

Aniruddha Patki, MD  
 Jarrod Keeler, MD  
 David Jang, MD  
 Dennis Frank-Ito, PhD  
 Durham, NC  
 USA

Background: Chronic rhinosinusitis (CRS) is frequently associated with olfactory dysfunction (OD). In CRS with nasal polyposis, airflow through the olfactory cleft is reduced by mechanical obstruction. In CRS without polyps, inflamed nasal mucosa has been hypothesized as the cause of OD. It is unclear if diminished olfactory cleft airflow is present in CRS without polyps as well. Determining the root cause of OD in CRS could help direct therapy.

Methods: This is a retrospective study utilizing CFD to determine olfactory cleft airflow in three categories of subjects: normal healthy, CRS with OD, and CRS without OD. CFD analysis was conducted in the sinonasal cavities in six subjects (2 subjects per category), and superior airflow in the vicinity of the olfactory cleft was quantified in three cross-sections: anterior, middle and posterior.

Results: Bilaterally, superior airflow in L/min and average airflow velocity in all three cross-sections was similar for all groups. Nonetheless, CFD results showed that relative change in superior airflow from anterior to middle (AM) and from middle to posterior (MP) cross-sections increases in both normal healthy (AM=4.5%, MP=8.5%) and CRS without OD (AM=3.9%, MP=5.8%) subjects, but decreases in the CRS with OD subjects (AM=-3.9%, MP=-1.6%).

Discussion: The results obtained in this pilot study showed that as airflow travels posteriorly, the amount of flow in the superior nasal cavity is reduced in subjects with CRS and OD, and increased in both normal healthy and CRS without OD subjects. Altered patterns of airflow may play a role in OD for CRS patients.

Poster #019

**Comparative Study of Postoperative Steroid Usage after Endoscopic Sinus Surgery in Patients with and without Steroid-Eluting Stent Placement**

Luke Donatelli, MD  
Thomas Heineman, BA  
Angela Donaldson, MD  
Vijay Anand, MD  
New York, NY  
USA

**Objective:**

The purpose of this study is to compare post-operative steroid use among patients undergoing endoscopic sinus surgery (ESS) who received the steroid-eluting Propel sinus stent, versus those who did not.

**Study Design:** Retrospective review

**Setting:** Single surgeon rhinology practice

**Subjects and Methods:**

Medical charts of patients who underwent ESS between January 2012 and August 2013 were reviewed. Patients were grouped based on placement of the stent during surgery or not. Charts were reviewed to identify the time to initiation of oral or nasal steroids, the medication prescribed, and the duration of use. Steroids given for acute sinusitis, allergic rhinitis, or fungal exudates were excluded.

**Results:**

One hundred and thirty two patients underwent ESS during the study period. Thirty-three patients in the stent group, and 39 patients in the non-stent group met criteria for inclusion. Post-operative steroids were initiated in 8 patients (24%) in the stent group and 22 patients (56%) in the non-stent group ( $p=0.008$ ). The median time to initiation of steroid was 26 days (range 0 to 36) in the stent group and 24 days (range 4 to 38) in the non-stent group ( $p=0.01$ ). The median duration of steroid use was 0 days (range 0 to 30) in the stent group, versus 6 days (range 0 to 94) in the non-stent group ( $p=0.002$ ).

**Conclusion:**

This study represents a single surgeon's experience and shows a significant increase in time to steroid initiation, and a decrease in duration of post-operative steroid usage among patients receiving the Propel stent.

Poster #020

**Comparing the Utilization, Cost and Operating Time of Open versus Endoscopic Orbital Decompression: Data from the State Ambulatory Surgery Database**

Elisabeth Ference, MD, MPH  
Raj Sindwani, MD  
Rakesh Chandra, MD  
Bruce Tan, MD  
David Conley, MD  
Stephanie Shintani Smith, MD, MS  
Chicago, IL  
USA

**Objectives:** To study the utilization of open versus endoscopic orbital decompression

**Methods:** Cases identified by CPT codes were extracted from the California, Florida, Maryland and New York State Ambulatory Surgery Databases 2011, Healthcare Cost and Utilization Project, Agency for Healthcare Research and Quality. Patient demographics, diagnoses, surgical center and surgeon volume, mean charge and OR time were compared.

**Results:** 333 patients underwent orbital decompression (238 open, 83 endoscopic) in the included states in 2011; 92.5% of cases involved the medial wall only. 24.9% of medial decompressions were performed endoscopically, 71.5% open, and 3.6% via combined approach. 74.1% of patients had hyperthyroidism; 10.6% had non-endocrine exophthalmos. Only 20.2% of cases involved concomitant sinusotomies. Analyses adjusted for gender, age, race, state, hyperthyroidism and infection found that surgeries for infection were more likely to be performed endoscopically compared to procedures for other diagnoses [OR 5.27 (1.65-16.95),  $p=0.005$ ]. Patients in Florida and New York were more likely to undergo endoscopic decompression compared to patients in California [FL 3.11 (1.52-6.34), NY 3.23 (1.50-6.95)]. There was no significant difference in median charge for endoscopic (\$13,012) versus open (\$11,255, Wilcoxon Rank Sum  $p=0.058$ ) procedures or in median operating room time (endoscopic 129 minutes, open 114.5 minutes,  $p=0.53$ ).

**Conclusions:** In the study sample, endoscopic orbital decompression was performed in 28.5% of cases. There was significant variation in surgical technique based on geography and indication. Procedures using endoscopic compared to open decompression techniques had no significant difference in charge or operating room time. Further analysis is necessary to determine if endoscopic techniques are underutilized for orbital decompression.



## POSTERS

Poster #021

**Comparison of Sinus Sampling Techniques by 16S Sequencing**

Mark Merkley, MD, PhD  
 Tristan Bice, BA  
 Alex Grier, MS  
 Li Man, MD  
 Steven Gill, PhD  
 Rochester, NY  
 USA

**Background:** New molecular technologies allow for the study of low-abundance or unculturable bacteria in the setting of chronic rhinosinusitis. In performing these studies the importance of sampling technique, including aspiration, swab, or tissue biopsy has not been previously addressed.

**Methods:** Three samples were collected bilaterally from the maxillary sinuses of nine chronic rhinosinusitis patients undergoing first-time sinus surgery. The maxillary sinuses were aspirated, or in the absence of purulence, irrigated and then aspirated. A maxillary antrostomy was then performed and portions of the medial wall mucosa were collected. After the antrostomy, a swab was brushed along the posterior wall of the maxillary sinus. DNA was extracted from each sample, amplified using bacterial 16S primers, and sequenced.  $\alpha$ - and  $\beta$ -diversity of the microbiota within and between sampling techniques was calculated.

**Results:** There was comparable  $\alpha$ -diversity between the tissue samples and the swab samples ( $p < 0.39$ ), but lower average diversity in aspirate samples versus both tissue samples ( $p < 0.04$ ) and swab samples ( $p < 0.07$ ). Bray-Curtis analysis of  $\beta$ -diversity demonstrated greater homology within sampling techniques than between sampling techniques. A comparison of  $\alpha$ - and  $\beta$ -diversity in paired left and right maxillary sinuses failed to show a significant difference in diversity. The phyla Actinobacteria and Firmicutes were identified more frequently by swab, while a larger amount of the phylum Proteobacteria were identified by aspiration.

**Conclusion:** Significant differences exist in the diversity and phyla of microbiota obtained by aspiration, swab, or tissue biopsy.

Poster #022

**Comparison of the Efficacy of Steroid Nasal Spray with Steroid Nasal Douching in the Management of Allergic Fungal Rhinosinusitis**

Ramandeep Virk, MD  
 Amit Babel, MD  
 Ashok Gupta, MD  
 Sandeep Bansal, MD  
 Samir Malhotra, MD  
 Chandigarh  
 India

**Aims and objectives:** comparison of the efficacy of steroid nasal spray with steroid nasal douching in the management of allergic fungal rhinosinusitis

**Material and Methods:** Prospective study

**Study group :** Total 75 patients.  
 Group A - Those who received Saline Nasal Douching.  
 Group B - Those who received Steroids Nasal Spray.  
 Group C - Those who received Steroid Nasal Douching.

**Inclusion Criteria:**Patients of age group 14-70 years with AFRS both males and females. Patients with proven Allergic fungal rhino sinusitis according to Bent and Kuhn's criteria

**Results:** Steroid Nasal Douching is significantly better in controlling the cavity post surgery.

Poster #023

**Concha Bullosa of the Inferior Turbinate: an Incidental Finding on an Epistaxis Studying Protocol**

Eleazar Graterón, MD  
Sinay Ceballos, MD  
Juan Chiossone, MD  
Caracas, Miranda  
Venezuela

Objectives:

1. To recognize a very unusual anatomic variant of the lateral nasal structures and review the related literature.
2. To describe the details of the clinical presentation, physical examination, radiological and endoscopic findings and management of a patient with this diagnosis.

Methods: Medical charts and scientific literature were reviewed

Case: A 36 year old otherwise healthy male patient presented with a 1- month history of intermittent epistaxis with no other accompanying symptom or medical history prior to it. The patient was evaluated in three opportunities with no evidence of bleeding origin on rhinoscopic and endoscopic examination, until the patient turn into the emergency room and admitted requiring an anterior nasal packing for 5 days and monitoring. Once the nasal packing was removed, a fourth nasal endoscopy was practiced showing a slightly dilated vessel over the left Woodruff plexus, which was cauterized. The CT-scan previously ordered show a complete pneumatization of the right inferior turbinate that communicated completely with the maxillary sinus with no mucosal affection, or any other alteration.

Conclusions: Although the pneumatization of an inferior turbinate is a rare anatomical variant, it must always be taken into account when making differential diagnosis.

Poster #024

**Concha Bullosa: A Shield Against Allergens?**

Douglas Worrall, BS  
Raewyn Campbell, MD  
Nithin Adappa, MD  
Philadelphia, PA  
USA

Introduction: Concha bullosa (CB) is a pneumatization of the nasal turbinates, which alters intranasal anatomy and influences the inflammatory microenvironment central to chronic rhinosinusitis (CRS) and allergic rhinitis pathophysiology. However, it remains unclear whether CB is part of an adaptive process, serving as a buffer against inhaled allergens, or a pathologic one, impairing sinus drainage and predisposing to inflammation. Investigating the link between allergies and CB can illuminate a theoretical benefit of this enigmatic anatomic variant, which has implications on the extent of resection in endoscopic sinus surgery.

Methods: A retrospective review of adults with chronic sinonasal symptoms evaluated by intradermal allergy testing and maxillofacial computed tomography (CT) scan between 2010 and March 2014 was performed. Allergy status was blinded prior to CT scan analysis by two independent reviewers. The relationship between CB and allergy was examined utilizing chi-squared analysis.

Results: Forty-three adults were divided into thirty positive cases and thirteen pan-negative allergy controls. No difference in CB prevalence was observed between those with positive (70%) and negative (69.2%) allergies ( $p=0.93$ ). Overall, 83.3% of CB were located in the middle turbinate, 16.7% in the superior turbinate, and 20% were bilateral.

Conclusions: Although an enlarged pneumatized turbinate could function as an improved physical barrier to inhaled allergens, allergies appear to play no role in CB formation. Thus, CB provides no clear physiologic benefit, and its high frequency among patients with chronic sinonasal symptoms suggests it causes harm, impairing sinus drainage and supporting surgical management for CRS patients that fail medical management.

## POSTERS

Poster #025

**Concordance of Clinical Culture Results and Sequencing-Derived Microbial Analysis of the Paranasal Sinus Microbiome**

Saqib Ahmed, MD  
 Steven Fletcher, MD  
 Emily Cope, PhD  
 Andrew Goldberg, MD  
 Susan Lynch, PhD  
 San Francisco, CA  
 USA

**Introduction:** Culture-independent methods of bacterial analysis demonstrate complex bacterial communities in both healthy and diseased sinuses. The goal for this study is to determine the concordance of culture-independent bacterial identification with clinical culture results.

**Methods:** A retrospective review was performed of 27 CRS patients undergoing endoscopic sinus surgery. Mucosal brush samples for sequencing analysis were taken from the sinus mucosa using a sheathed brush. Cultures were obtained from patients with abnormal appearing mucus either at the time of surgery or in the perioperative period. Clinical cultures were performed on standard media using unsheathed swabs through the nasal vestibule under endoscopic guidance.

**Results:** Culture results were non-specific in 8 of 27 patients demonstrating "oronasal" or "skin" flora. While five patients had *Staphylococcus epidermidis* in their cultures, only one had evidence of *Staphylococcus* upon sequencing analysis suggesting contamination from the nasal vestibule. Of the remaining 14 patients, cultured organisms were also detected in the sequence-based microbiota analysis of 13 subjects (93%); 8 (57%) as the dominant and 5 (36%) as a lower abundance community member. The remaining patient had follow-up cultures which yielded the dominant organism from her sequencing results (*Pseudomonas*).

**Conclusion:** *S. epidermidis* may represent a contaminant of clinical culture samples. Bacteria identified in clinical cultures can be detected by sequencing. While the majority of cultured bacteria represent the dominant species in sequenced-based microbiota data, 36% of the subjects failed to have their dominant organism cultured. In the latter group, lower abundance species in the microbiome were the only bacteria cultured.

Poster #026

**Contralateral Trephine Approach for Surgical Access to the Frontal Sinus Floor: A Cadaver Study**

David Healy, MD  
 Giant Lin, MD  
 Nipun Chhabra, MD  
 Rodolfo Manosalva, MD  
 Benjamin Bleier, MD  
 Portsmouth, VA  
 USA

**Introduction:** Endoscopic visualization and instrumentation of the frontal sinus floor is limited, even via a modified Lothrop approach, necessitating the use of external approaches to access this surface. A contralateral trephine approach is postulated to provide complete access to the lateral aspect of the frontal sinus floor for visualization, instrumentation, and drilling.

**Methods:** Twelve frontal sinus floors (the surface shared with the superior orbital wall) from 6 cadaver specimens were imaged and surgically analyzed. Measurement of the reach of a curved endoscopic drill (Reach of Drill) along the frontal sinus floor from the frontal os was taken after Draf IIa, IIb, and III approaches were completed. The Reach of Drill via a contralateral trephine approach was then measured.

**Results:** Following Draf IIa, IIb, and III approaches, the Reach of Drill along the frontal sinus floor was respectively 11.5 mm (range 7.5-15.8 mm, n=6), 14.5 mm (range 11.5-18.1 mm, n=6), and 16.9 mm (range 11.6-24.4 mm, n=12). None of the frontal sinus floors were fully accessed via these endoscopic approaches. In all specimens, a contralateral trephine approach provided full visualization and ability to drill the lateral aspect of both frontal sinus floors.

**Conclusion:** In this cadaver study, a contralateral trephine approach provided complete access to the frontal sinus floor in all specimens, while all endoscopic approaches failed to fully access this surface. This approach may be a useful adjunct along with the Draf III approach when drilling along the lateral aspect of the frontal sinus floor is needed.

Poster #027

**Correction of the Deviated Septum: From Ancient Egypt to the Endoscopic Era**

Nicole Aaronson, MD  
Eugenia Vining, MD  
New Haven, CT  
USA

**Introduction:** Obstructed nasal breathing can occur due to deviation of the nasal septum. When the external nose appears grossly normal and cosmesis is not the focus, septoplasty has been the procedure used to straighten the septum with the goal of improving nasal airflow. The techniques and procedures of septoplasty have evolved over time. The purpose of this study is to evaluate the advancements in septoplasty from a historical perspective.

**Methods:** This is a historical review of the literature evaluating primary source articles from the pioneers of septoplasty in order to understand how this surgery has evolved over time.

**Results:** Early techniques involved forcible fractures and splinting. Submucous resection was the first major advancement in surgical technique. Once the complications resulting from this technique were observed, it was subsequently revised with attempts to better address the caudal septal deviation. Attention was then turned to better incorporating the role of surrounding support structures, such as the upper lateral cartilages. The premaxilla-maxilla approach attempted to address the overall nasal structure to best improve nasal breathing. The advent of endoscopic technique has improved visualization allowing for targeted septoplasty and reoperation on complicated cases. These advancements in techniques have also led to the advent of endonasal approaches to the skull base and septal flaps for repair of defects.

**Conclusions:** Septoplasty, one of the oldest and most common otolaryngologic surgeries, has changed drastically over time from the forcible septal fracture of the Ancient Egyptians to the targeted septoplasties and transseptal skull base approaches of modern rhinologists.

Poster #028

**Deadly Sphenoid Fungus: Isolated Sphenoid Invasive Fungal Rhinosinusitis**

Jason Gilde, MD  
Jonathan Liang, MD  
Victoria Epstein, MD  
Oakland, CA  
USA

**Background:** Acute invasive fungal rhinosinusitis (AIFRS) is a potentially fatal infection commonly affecting immunocompromised patients. Isolated sphenoid sinus involvement is particularly rare, and has been reported in only a few cases. We discuss the clinical characteristics, histopathological features, differential diagnosis of AIFRS of the sphenoid sinus.

**Methods/Study Design:** Case report and review of literature.

**Results:** A 57-year-old man with a history of refractory non-Hodgkin's lymphoma and neutropenia presented with 1 week of left-sided headache and cheek paresthesia. Endoscopy showed mucoid drainage from the sphenoidal recess. MRI demonstrated left sphenoid mucosal thickening and enhancement along the adjacent skull base. He underwent endoscopic sinus surgery with extended sphenoidotomy and debridement. The lateral wall and recess of the left sphenoid sinus demonstrated pale-colored mucosa and fungal debris. Pathology demonstrated necrotic tissue and fungal hyphae with angioinvasion. Microbiology isolated *Aspergillus fumigatus*. The right maxillary sinus contained a synchronous fungal ball, which was removed at the time of surgery; there was no evidence of tissue necrosis or invasive fungus in the maxillary sinus. He was treated with long-term voriconazole therapy, and 6-month follow-up showed disease resolution.

**Conclusions:** AIFRS should be considered in the differential diagnosis of immunocompromised patients with non-specific sinonasal symptomatology. AIFRS is usually diffuse with multiple sinus involvement; however, isolated sphenoid AIFRS can occur. This is one of the few cases of AIFRS demonstrating isolated sphenoid involvement, and the first case showing a synchronous non-invasive fungal ball of another sinus cavity. Prompt recognition and surgical treatment may be curative and life-saving.

## POSTERS

Poster #029

**Decreased Rate of Influenza Vaccination is associated with Increased Subjective Olfactory Dysfunction**

Carrie Flanagan, MD  
 Sarah Wise, MD, MSCR  
 John DelGaudio, MD  
 Zara Patel, MD  
 Atlanta, GA  
 USA

**Background:** Seasonal influenza causes significant morbidity and mortality, with cardiovascular and respiratory complications the most common among susceptible individuals. Upper respiratory tract infections (URI) are known to precede olfactory dysfunction in some patients. There has been no study assessing the possible relationship between influenza vaccination status and olfactory dysfunction. The purpose of this study was to compare vaccination status between a group of patients with subjective olfactory dysfunction to a group of controls.

**Methods:** Retrospective chart review and telephone survey in a matched case-control study. Forty-two patients were identified via diagnosis codes and SNOT-22 responses, who presented to a tertiary care rhinologic center with subjective smell dysfunction over the course of one year, only including post-URI and idiopathic etiologies. Forty-two age, gender and race matched control patients were also selected. Demographic data, influenza vaccination and smoking status were reviewed. Chi-square testing was used.

**Results:** We were able to obtain vaccination data on 36/42 patients in the olfactory dysfunction group, and 38/42 in the control group. 7 out of 36 (19%) in the olfactory dysfunction group received the vaccine in the year prior to presentation, compared to 16 out of 38 (42%) in the control group. Chi-square testing showed a statistically significant difference ( $p=0.035$ ).

**Conclusions:** Influenza vaccination appears to be associated with a decreased rate of subjective olfactory dysfunction. Further studies may elucidate whether the vaccine is conferring a protective benefit to the olfactory epithelium in these patients and may be another indication for encouraging vaccine use in susceptible individuals.

Poster #030

**Demographic and Socioeconomic Differences Between Chronic Rhinosinusitis and Allergic Fungal Rhinosinusitis Patients**

Yemeng Lu, BS  
 Allison Deal, MS  
 Justin Miller, MD  
 Stanley McClurg, MD  
 Brent Senior, MD  
 Charles Ebert, MD  
 Chapel Hill, NC  
 USA

**Introduction:** There is a paucity of data comparing differences in socioeconomic, demographic and disease severity factors between chronic rhinosinusitis (CRS) and allergic fungal rhinosinusitis (AFRS) patients.

**Methods:** A retrospective cohort analysis was performed on patients with CRS and AFRS from 2000-2013. CRS patients were stratified by presence or absence of polyps. County specific socioeconomic and demographic data representative of health care access was obtained from The North Carolina State Data Center. Indicators of disease severity were measured by Lund-Mackay score, serum IgE, allergen and mold sensitivity, concurrent diagnosis of asthma, allergic rhinitis, the number of surgical procedures and CT scans performed. Associations between the variables were analyzed with Fisher's Exact, Wilcoxon Rank-Sum, and Pearson's correlations tests.

**Results:** Compared to the AFRS patients, the CRS patients ( $n=93$ ) were predominantly Caucasian (59.3% vs 15.4%;  $P<0.0001$ ), older (44 years old at diagnoses vs. 29 years old;  $P<0.0001$ ), had higher county based income per capita ( $P=0.004$ ), more access to primary care practitioners per capita ( $P=0.03$ ), lower IgE level ( $P<0.001$ ), less diagnosis of allergic rhinitis ( $P<0.001$ ), and lower Lund-Mackey scores ( $P<0.0001$ ). No associations between components of disease severity and socioeconomic status and health care access were found within the CRS groups with or without polyps. CRSwNP patients had higher Lund-Mackey scores and IgE level compared to CRSsNP patients ( $P<0.0001$ ).

**Conclusion:** CRS patients when compared to AFRS patients have higher income, more access to primary care, and lower markers of disease severity.

Poster #031

**Dexmedetomidine Improves Quality of the Operative Field for Sinonasal Surgery: a Systematic Review and Meta-analysis**

Kornkiat Snidvongs, MD, PhD  
Bangkok, Bangkok  
Thailand

**Introduction:** Intraoperative bleeding diminishes visualization during sinonasal surgery and brings unfavorable outcomes. Dexmedetomidine is a potent alpha-2 agonist. Its sympatholytic effect decreases blood pressure and heart rate so it has been used in sinonasal surgery for controlled hypotensive anesthesia. This study aims to assess whether dexmedetomidine decreases intraoperative bleeding and improves quality of the operative field.

**Methods:** All randomized trials assessing the effectiveness of dexmedetomidine in providing good operative fields for sinonasal surgery were identified from Medline and Embase. When studies were sufficiently homogeneous, data were pooled for meta-analysis. The outcomes were the quality of the operative field, the operative time and adverse events.

**Results:** Nine studies (454 patients) met the inclusion criteria. Five studies compared dexmedetomidine versus saline. One study compared dexmedetomidine assisting sevoflurane versus sevoflurane alone while three studies compared dexmedetomidine versus other anesthetic drugs. When compared to placebo, dexmedetomidine decreased intraoperative bleeding and improved quality of the operative field (standardized mean difference -1.68; 95%CI -2.10 to -1.25). The operative time was similar between groups (mean difference -13.82; 95%CI -33.89 to 6.24). When compared to other drugs, dexmedetomidine was as effective as esmolol and remifentanyl but more effective than midazolam regarding surgical field conditions. There were no adverse incidents related to anesthesia reported.

**Conclusions:** Dexmedetomidine is beneficial and safe in providing good visibility during sinonasal surgery. Controlled hypotensive anesthesia with this medicine decreases intraoperative bleeding and enhances quality of the surgical field.

Poster #032

**Effect of Crushed Skeletal Muscle Extract on Haemostatic Parameters**

Sukanya Rajiv, MS  
Susan Rodgers, PhD  
Ahmed Bassiouni, MBCh  
Peter-John Wormald, MD  
Adelaide, South Australia  
Australia

**Introduction:** Use of muscle grafts for haemostasis during surgery has re-emerged with recent animal model studies showing effective bleeding control with their use. However, its mechanism of action is unknown. The aim of this study is to evaluate the action of muscle extracts on the coagulation pathways and platelet aggregation.

**Methods:** Muscle extracts were prepared by dissolving crushed snap-frozen muscle tissue (0.04mg-0.8mg) in 1ml saline. Saline was used as control. Prothrombin time, activated partial thromboplastin time (APTT), thrombin time and platelet aggregation studies were performed on both muscle extract and saline. Prothrombin time and APTT were repeated using Factor VII deficient plasma, Factor X deficient plasma, Lupus plasma and contact pathway inhibited plasma.

**Results:** Mean readings for the muscle group and saline group were compared using non-parametric Mann-Whitney U test (Wilcoxon ranked sum test with continuity correction). Amongst the various coagulation parameters, there was no significant difference between saline and muscle ( $p > 0.05$ ), except for the APTT using factor X deficient plasma (mean APTT 133.85s and 185.10s for muscle and saline respectively;  $p < 0.0001$ ). Higher concentrations of the muscle extract ( $>0.5\text{mg/ml}$ ) increased platelet aggregation from 23.5% to 55% ( $p=0.0001$ ).

**Conclusion:** Platelet aggregation plays a role in the haemostatic efficacy of muscle grafts. Action on the coagulation pathway via APTT though statistically significant, clinical significance may be low.



## POSTERS

Poster #033

**Emergency Department Presentation for Uncomplicated Acute Rhinosinusitis is Associated with Poor Access to Health Care**

George Scangas, MD  
 Stacey Ishman, MD, MPH  
 Michael Cunningham, MD  
 Ahmad Sedaghat, MD, PHD  
 Boston, MA  
 USA

**Introduction:** Uncomplicated acute rhinosinusitis (ARS) affects millions of individuals. Although most appropriately managed in an outpatient clinic setting, some ARS patients nonetheless present to emergency departments (EDs) for care. We investigate factors associated with ARS presentation to EDs versus outpatient settings.

**Study Design and Methods:** Cross-sectional study of 17,122,551 pediatric and adult patients from the 2009 and 2010 National Ambulatory Medical Care and National Hospital Ambulatory Medical Care Surveys diagnosed with ARS. Patients with ARS complications were excluded. Univariate and multivariate associations identified demographic and socioeconomic characteristics of ARS patients independently associated with presentation to EDs. ARS severity was indirectly controlled for by using temperature >100°F.

**Results:** Patients with Medicaid (OR=10.82, P<0.001) or no insurance (OR=9.14, P<0.001) more likely presented to EDs when compared to patients with private insurance or Medicare. Independently, black patients (OR=6.01, P<0.001) more likely presented to EDs when compared to white or Hispanic patients. No significant association was seen with metropolitan status or socioeconomic status based upon the patients' home zip code.

**Conclusions:** Presentation of ARS patients to EDs is associated with health insurance status and patient race independent of socioeconomic status. Health care access appears to be a primary determinant of whether patients present to an ED or outpatient setting for this common health problem. The association between race and ED presentation suggests cultural underpinnings requiring further characterization. Reducing barriers to care, for example through broader health insurance coverage, may enhance access to outpatient care providers and decrease costs associated with unnecessary ED presentation.

Poster #034

**Endonasal Resection of a Glomangiopericytoma**

Aditi Bhuskute, MD  
 Toby Steele, MD  
 E. Bradley Strong, MD  
 Sacramento, California  
 USA

**Background:** Glomangiopericytoma, or sinonasal type hemangiopericytoma, is a rare sinonasal tumor of low malignant potential. This tumor is thought to originate from the pericytes surrounding capillaries. It was first reported with its cohorts of soft tissue hemangiopericytomas, but recent literature has demonstrated its histologic characteristics that make it more glomus like in nature and may be a separate entity. This tumor is slowly evolving away from its original classification, its characteristics have become of an increasing area of research.

**Methods:** We present the clinical, radiologic, and pathologic findings of a sinonasal glomangiopericytoma in a 66 year old woman with a six month history of recurrent epistaxis and unilateral nasal obstruction.

**Results:** The tumor was successfully resected with clear margins using an endonasal approach. Pathology confirmed the diagnosis of glomangiopericytoma.

**Discussion:** Glomangiopericytoma is a rare sinonasal tumor, accounting for less than 0.5% of all sinonasal neoplasms. Traditionally, these tumors have been approached externally, most frequently through a lateral rhinotomy incision. With the expansion of endonasal and skull base surgery, recent literature has focused on endonasal approaches for resection of these tumors. We seek to add to the literature supporting endonasal approaches, while reviewing this tumor's interesting characteristics, including presenting symptoms, histopathology, imaging characteristics, and clinical course.

Poster #035

### **Endoscopic Excision of a Nasal Septum Pleomorphic Adenoma**

Luis Tarrats, MD-JD  
Carlos Torre, MD  
Juan Portela, MD  
San Juan, PR  
USA

Pleomorphic adenoma is the most common benign neoplasm of the salivary glands. This tumor rarely presents in the nasal cavity. Although most of the minor salivary glands are located in the lateral nasal wall, the nasal septum is the primary site for this lesion. Pleomorphic adenoma is a mixed tumor composed of myoepithelial cells on a mesenchymal stroma. Histologically, cellularity is higher in a pleomorphic adenoma arising from the nasal septum than in those arising in the major salivary glands. The treatment of this tumor is surgical resection with free margins due the risk of malignant transformation and metastasis. Lateral rhinotomy have been the principal surgical approach for removal of these lesions but endoscopic procedures have recently been successfully documented.

This article presents the endoscopic excision of a large nasal septum pleomorphic adenoma. A 60 year old female with no history of trauma complained of progressive right side nasal obstruction and one episode of epistaxis. Nasal endoscopy showed a bilateral, round, smooth-surfaced, submucosal mass with prominent vessels of approximately 2 cm. The lesion appeared to be expanding rather than invading the nasal septum. Computed Tomography scan revealed a homogenous submucosal solid mass with no tissue invasion. Magnetic Resonance Image showed a low signal intensity on T1 and a heterogeneous, intermediate signal intensity on T2. Patient was taken to OR under general anesthesia and using endoscopic instrumentation an en bloc resection with 1 cm margins and partial septectomy was performed.

Poster #036

### **Endoscopic Repair of Multiple Encephaloceles: A Unique Case and Review of the Literature**

Nathan Eivaz, BS  
Jeb Justice, MD  
Gainesville, FL  
USA

**Introduction:** A 48-year-old man presented to the Emergency Room with bilateral decreased visual acuity, headache, and obtundation. Imaging showed a 6.8x6.8x6.3 cm intracranial mass centered in the left frontal lobe concerning for a meningioma as well as several skull base defects concerning for encephaloceles.

**Purpose:** To present a case of endoscopic repair of multiple encephaloceles and review the pertinent literature.

**Methods:** Case report with review of the pertinent literature

**Results:** The mass resulted in left lateral ventricle entrapment, 2.2 cm right-to-left subfalcine herniation, and downward transtentorial herniation. Urgent craniotomy and tumor removal was performed by the Neurosurgical service and pathology was consistent with meningioma. Post-operatively, the patient experienced CSF leak. CSF diversion via lumbar drain for 3 days did not improve the leak. Otolaryngology was consulted for consideration of endoscopic repair. Intra-operatively, 7 encephaloceles (2 in each ethmoid roof, 3 in the sphenoid skull base) were identified, ablated, and the defects repaired with multi-layered closures, including a left nasoseptal flap for the 3 defects in the sphenoid sinus. The patient demonstrated no leak post-operatively for 3 months. In the 4th month post-op, the patient began leaking, and intra-operative fluorescein via lumbar drain demonstrated a leak in the right lateral sphenoid (at the distal aspect of the nasoseptal flap), which was revised with a multilayered closure. The patient is doing well and shows no evidence of CSF leak 9 months after repair.

**Conclusion:** Endoscopic repair of multiple encephaloceles is safe and feasible, and literature review is provided.

## POSTERS

Poster #037

**Endoscopic Ventral Skull Base Surgery: Is Early Postoperative Imaging Warranted?**

Lucia Diaz, AB

Zachary Mendelson, BS

Leila Mady, MD, PhD, MPH

James Liu, MD

Jean Anderson Eloy, MD, FACS

Newark, NJ

USA

**Introduction:** Following endoscopic ventral skull base surgery (EVSBS), it is common practice to obtain early postoperative imaging. The role of postoperative CT and MRI scans in these patients remains unclear. This study aims to determine the clinical utility of early postoperative CT and MRI scans after EVSBS.

**Methods:** A retrospective chart analysis of 218 patients who underwent purely EVSBS between 2009 and 2014. Data were collected regarding postoperative CT and MR imaging as well as hospital course. Interpretations of postoperative imaging were separated into two groups: 1) using radiologist's interpretation alone, 2) surgeon knowledge of the case in tandem with imaging.

**Results:** Postoperative imaging was obtained in 206 cases (197 CT, 163 MRI) within 48 hours of surgery. Interpretation by radiologist yielded a significantly higher rate of false positives (FP) on CT (15/197) and MRI (18/163) ( $P=0.0004$  and  $P=0.0365$ ) when compared to surgeon interpretation (CT FP= 1/197 and MR FP= 1/163), as well as a significantly lower rate of true negatives (TN) on CT (164/197 vs 178/197) ( $P=0.0500$ ) while MRI data had a similar rate of TN (142/163 vs 149/163) ( $P=0.2830$ ). The rate of postoperative complications was 6.0%. In all cases of postoperative complications that required intervention, patients exhibited clinical symptoms.

**Conclusion:** Based on our findings, the benefit of early postoperative imaging to detect complications after EVSBS may be limited. When positive imaging findings were encountered, their value were somewhat negated by preceding clinical symptoms.

Poster #038

**Establishment & Characterization of a Novel Cell Line Derived from Inverted Papilloma-Associated Squamous Cell Carcinoma**

Wade Swenson, MD

Beverly Wuertz, BA

Frank Ondrey, MD, PhD

Minneapolis, MN

USA

**Introduction:** The frequency of carcinoma in patients with sinonasal inverted papilloma (IP) is estimated to be 3–24% and is predominantly squamous cell carcinoma (SSC). In two thirds of cases, carcinoma occurs synchronously with IP. The remainder is metachronous, occurring after previous resection of IP. To better understand the biologic features of IP-associated sinonasal SCC and assist in development of new and improved therapies for the disease, we established the first reported IP-associated sinonasal SCC cell line and characterized its molecular properties.

**Methods:** Cell lines were established from a patient with a T4aN0M0 IP-associated SCC of the maxillary sinus who was treated with surgical resection at our center. Tumor colonies were harvested, the tissues mechanically dissociated and sequentially replated onto larger plates as the cells divided. The cell line was characterized with molecular, biomarker, and histologic analyses.

**Results:** Short tandem repeat genotyping revealed the cell line is isogenic to the parental tumor and discrete from any previously authenticated cell lines. Further analysis via G-banding and Spectral Karyotyping (SKY) identified chromosomal translocations consistent with patient and disease characteristics. The cell line was also analyzed via immunohistochemistry for expression of epithelial markers cytokeratin 7 and 19, EGFR, p53, p21, and cyclin D1.

**Conclusions:** This is the first report of the establishment of a stable human-derived IP-associated sinonasal SCC cell line. This cell line should serve as a useful tool for the future study of IP-associated SCC tumor biology and the development and testing of novel therapies for this deadly disease.

Poster #039

**Ethmoid Pneumocele Presenting with Exophthalmos 15 Years After Endoscopic Sinus Surgery**

Michelle Song, DO  
 Jamie Ahn, MD  
 Douglas Reh, MD  
 Josef Shargorodsky, MD, MPH  
 Dupont, WA  
 USA

**Introduction:** A pneumocele is an abnormal dilation of an air-containing sinus beyond the normal margins of bone, with associated bony thinning. A delayed ethmoid pneumocele following sinus surgery has not previously been reported.

**Methods:** A case report of a patient with a delayed ethmoid pneumocele following sinus surgery. The diagnostic workup, operative approach, and postoperative results were evaluated.

**Results:** Fifty seven year old female with a history of endoscopic sinus surgery 15 years prior, presented with right eye proptosis and severe orbital and facial pressure. A maxillofacial CT showed a markedly expanded air-filled right anterior ethmoid space with a dehiscent lamina papyracea, consistent with a pneumocele. Marsupialization of the pneumocele as well as a revision ethmoidectomy were performed, with a visible return of the orbital contents to a more natural position. The patient experienced worsened diplopia immediately postoperatively that resolved within two weeks.

**Conclusions:** This case demonstrates that a pneumocele can present even years after endoscopic sinus surgery, and acute but temporary development or worsening of diplopia can result from surgical decompression of the pneumocele as the eye returns to its natural position.

Poster #040

**Excision of Frontal Osteoma With Endoscopic Brow Lift Technique**

Irfan Syed, FRCS (ORL-HNS)  
 Rahul Jayaram, MRCS  
 Jimmy Uddin, FRCOphth  
 Mehmet Manisali, FRCS  
 London,  
 England

**Objectives:** We describe a technique to excise an osteoma from the frontal bone by an endoscopic brow lift approach for maximal aesthetic benefit

**Method:** Report of a case of endoscopic brow lift approach for the removal of frontal osteoma with stepwise approach described using high resolution intra-operative photographs

**Results**

Frontal osteoma removed in toto and good contouring of the resulting defect with the described approach

**Conclusion:** Endoscopic brow lift approach provides excellent access for removal of frontal osteoma lesions with no facial scarring. We also advocate the use of nasal rhinoplasty instruments for contouring of the irregular margin following removal of the lesion to optimise the cosmetic result.

## POSTERS

Poster #041

**Exhaled Breath Condensate in Nasal and Mouth Breathing in Patients with Seasonal Allergic Rhinitis**

Masato Miwa, MD PhD  
 Mayumi Miwa, MD PhD  
 Katsuhisa Ikeda, MD PhD  
 Tokyo,  
 Japan

**Aim:** Analyses of Exhaled breath condensate (EBC) could provide useful information for possible clinical applications. In contrast, nasal exhaled breath condensate (nEBC) has not been studied. We attempted to evaluate nEBC for clinical investigation as well as mouth exhaled breath condensate (mEBC).

**Methods:** 10 healthy subjects and 43 patients with Japanese cedar pollinosis took part in the study after providing informed consent. Using a condenser, R-tube (UK) by mouth and nasal breathing, collected EBC. pH was measured with a pH meter (Horiba, Japan). 27 cytokines and chemokines were measured by microarray beads with various antibodies using Multiplex (Bio-Rad, USA). In addition, antihistamines were administered to Japanese cedar pollinosis patients before and after the start of the dispersion season and continued for 4 to 8 weeks.

**Results:** Elevation of pH in nEBC was detected in post treatment group significantly compared with pretreatment. On the other hand, pH in mEBC was not altered after treatment. Selective down regulation of several molecules in EBC from both groups was detectable on the microarray membranes. The array analyses indicated that some cytokines including IL-4, IL-8 were the molecules in mEBC with significantly down regulated expression in patients with pollinosis after treatment compared with those of pretreatment. In nEBC, some cytokines including TNF- $\alpha$ , RANTES, IFN- $\gamma$  decreased significantly after treatment compared with pretreatment.

**Conclusion:** Analysis with nEBC might be a promising approach to assess the efficacy of pharmacologic intervention and to investigate the pathophysiology of allergic rhinitis.

Poster #042

**Exhaled Nitric Oxide in Upper Airway Disease**

Agnetha Wohlfahrt, MD  
 Anders Cervin, MD, PhD  
 Helsingborg, NA  
 Sweden

**Introduction:** In a descriptive study we have measured exhaled nitric oxide (FeNO) in patients presenting with chronic rhinosinusitis or rhinitis like symptoms at an ENT outpatient clinic in a Swedish public hospital. The aim of the investigation was to estimate the prevalence of patients with un-diagnosed or under-treated eosinophilic inflammation of the lower airway.

**Material and Methods:** 118 patients presenting with chronic rhinitis or rhinosinusitis like symptoms were measured. Patients were divided according to their diagnosis after a relevant workup including CT of the sinuses, skin prick testing or RAST panel. NO analyser was NIOX and NIOX mini by Aerocrine. Cut off value for expiratory NO was set at 25 ppb.

**Results:** CRSwNP, n=39, 59 % had elevated FeNO and 20 % lacked treatment of the lower airway. In CRSsNP, n=18, 35 % had elevated FeNO and 20 % were untreated. In patients diagnosed with allergic rhinitis, n=20, 44 % had elevated FeNO and 11% had no lower airway treatment. In non-allergic rhinitis, n=41, 15 % had elevated FeNO. Controls, n=19, 19 % with elevated FeNO. CRSwNP had the highest FeNO mean 43 ppb, allergic rhinitis 42 ppb, whereas CRSsNP, non-allergic rhinitis and controls were 22, 20 and 19 ppb respectively.

**Conclusion:** In conclusion the majority of CRSwNP patients in an ENT outpatient clinic have an elevated FeNO, suggesting that this group of patients are either undiagnosed or not adequately treated. This could impact outcomes in CRS. ENT doctors need to be vigilant regarding inflammation in the lower airways.

Poster #043

**Extra-Maxillary Sinus Mucoceles: An Inside-Out Phenomenon**

Vibhav Sekhsaria, MD  
 Anthony Sheyn, MD  
 Peter Svider, MD  
 Adam Folbe, MD  
 Detroit, MI  
 USA

**Introduction:** Mucoceles are well-described lesions related to ostial obstruction causing the accumulation of mucous secretions. They are usually found within the paranasal sinuses where their presence is well-documented. This case report describes the rare and unique formation of a mucocele external to the paranasal sinuses.

**Case Report:** A 37 year old male with a history of orbital trauma in 1997 was referred 15 years later for evaluation of a submucosal mass. A CT sinus was remarkable for an expansile right maxillary mass involving the floor of the maxilla and masticator space. The patient was taken to the OR for FESS, during which the maxillary sinus was noted to be closed down and reduced in size with the tumor located lateral to the sinus. The lateral wall of the maxillary sinus was taken down to expose the mass which was entered releasing a rush of mucopurulent drainage consistent with mucocele formation.

**Discussion:** Although mucoceles commonly arise from ostial obstruction, it would seem theoretically plausible that maxillary sinus epithelial elements found outside of the maxillary sinus, without a drainage pattern, could also develop into expansile mucoceles. Our patient's remote history of trauma and subsequent extra-maxillary sinus mucocele supports this theory.

**Conclusion:** Extra-paranasal sinus mucoceles are exceedingly rare and literature regarding their presentation is exceptionally sparse. It would seem that patients suffering trauma violating the maxillary sinus creates a potential situation where such mucoceles could arise. Such factors may require more consideration when effecting repairs during mid-face trauma repairs.

Poster #044

**Factors Affecting Group 2 Innate Lymphoid Cells in Chronic Rhinosinusitis**

Dijana Miljkovic, Bsc  
 Ahmed Bassiouni, MBBCh  
 Clare Cooksley, PhD  
 Ehud Hauben, PhD  
 Peter-John Wormald, MD, FRACS  
 Sarah Vreugde, MD, PhD  
 Woodville South, SA  
 Australia

**Background:** Group 2 Innate Lymphoid cells (ILC2s) were shown to be involved in the initiation and coordination of Th2-type immune responses in allergic disease animal models. Recently, ILC2s enrichment was noted in Chronic Rhinosinusitis (CRS), however, its association with factors of clinical importance in CRS (such as asthma, or allergy) has not been reported yet. We characterize the ILC2 compartment in CRS by investigating the correlations between ILC2s, Th2 cells, Th2 cytokines and various clinical variables in CRS patients.

**Methods:** We used flow cytometric analysis of sinonasal mucosal tissues of 29 CRS patients and 5 controls to quantify ILC2s and Th2 cells. Messenger RNA expression levels of IL-5, IL-13, IL-25, IL-33, TSLP and GATA3 were determined using qRT-PCR.

**Results:** ILC2s were significantly enriched in nasal polyps (CRSwNP) patients. Multivariate linear regression showed a significant positive association of ILC2 numbers with CRSwNP and allergic CRS and a negative association with the number of previous endoscopic sinus surgeries. ILC2 numbers significantly correlated with Th2 cell frequencies. Messenger RNA expression levels of IL-5 and IL-13 were increased in CRSwNP compared to controls, while mRNA levels of IL-25 and GATA3 were significantly reduced.

**Conclusions:** Our results characterize the complex interactions between ILC2s and other Th2 response elements in the context of CRS and suggest that ILC2 enrichment occurs in CRSwNP and in allergic CRS patients.



## POSTERS

Poster #045

**Frontal Mucocele Associated with Asymptomatic Maxillary Fungal Ball: A Case Report**

Benjamin Macias, MD  
 Ana Karla Guzman Romero, MD  
 Rina A. Escalona Riera, MD  
 Mexico City,  
 Mexico

**Introduction:** Aspergillus mycetoma, is the most frequent type of noninvasive mycotic infection. It is more frequently seen in the maxillary sinus. There are two different clinical features: symptomatic and asymptomatic (13.2-20%). This entity can be eradicated with surgical treatment. Endoscopic sinus surgery is the approach of choice.

Mucoceles are epithelium-lined mucus-containing sacs that fill a paranasal sinus. Mostly develop in the frontal sinus. The two most frequent causes of frontal sinus mucoceles are: inflammatory, posttraumatic and iatrogenic obstruction of the frontal recess caused by scarred tissue; however, in some cases the etiology remains unclear. Surgical intervention represents the treatment. The surgical approach depends on the localization and extension of the mucocele.

**Methods:** We present a frontal sinus mucocele secondary to asymptomatic maxillary mycetoma. And review of the literature.

**Results:** We present a clinical case of a 62 years old female patient with a frontal sinus mucocele extended to the orbit, secondary to asymptomatic maxillary mycetoma that causes osteitis of the frontal recess. The clinical manifestation was headache, diplopia, blurred vision and ocular pain.

**Conclusions:** It is described that the mucoceles are caused by inflammatory obstruction of the ostium, or secondary to fibrosis and surgical manipulation; however there is not previous reports that mentions the fungus ball as a direct cause of frontal sinus mucocele. This is an uncommon clinical case. It is important to suspect in patients with postsurgical changes suggestive images, without history of nasal surgery.

Poster #046

**Frontal Ostium Neo-osteogenesis and Patency after Draf III Procedure: a Computer-assisted Study**

Ting Ye, MD  
 Peter Hwang, MD  
 Zhenxiao Huang, MD, PhD  
 Qian Huang, MD  
 Junfang Xian, MD  
 Bing Zhou, MD  
 Beijing  
 China

**Introduction:** Stenosis of the frontal neo-ostium after Draf III procedure has been associated with inflammatory risk factors. However, the degree to which neo-osteogenesis contributes to post-surgical stenosis of the frontal neo-ostium is unclear.

**Methods:** Twenty-five patients with chronic frontal sinusitis who underwent Draf III procedure and had been followed up at least 12 months were included. Paranasal sinus CT scans were performed seven days and one year post-op. The frontal neo-ostium cross-sectional area and the amount of frontal neo-osteogenesis were measured by a standardized protocol using triplanar radiologic viewing software.

Association between the severity of frontal neo-osteogenesis and the patency of neo-ostium was analyzed, as was the correlation between the extent of neo-osteogenesis and the preoperative Global Osteitis Scoring Scale (GOSS), Lund-Mackay score (LMS), Lund-Kennedy score (LKS), serum eosinophil count and history of previous surgery.

**Results:** At one year postop, significant inverse correlation was found between the size of frontal neo-ostium and the extent of neo-osteogenesis. According to a multiple linear regression model, the severity of neo-osteogenesis was positively correlated with preoperative GOSS and negatively correlated with asthma ( $P < 0.05$ ). Additionally, there was no association between extent of neo-osteogenesis and preoperative LMS, LKS, serum eosinophil count, or previous surgery.

**Conclusions:** Neo-osteogenesis has a significant impact on the patency of the frontal neo-ostium but appears unrelated to inflammatory factors. Patients with a higher risk for developing neo-osteogenesis can be identified preoperatively based on GOSS; these patients may benefit from closer monitoring during the follow-up period.

Poster #047

**Frontal Sinus Fracture with Associated Encephalocele in a Child**

Luis Tarrats, MD-JD  
 Carlos Torre, MD  
 Juan Portela, MD  
 San Juan, PR  
 USA

In children maxillofacial fractures occurs mostly related to the nasal bones and mandible. Orbital and maxillary injuries are infrequent and frontal sinus fractures are a rare entity. It is theorized that the craniofacial pattern of frontal sinus development accounts for this reality. The frontal sinus begins to develop during the fourth month of gestation and reaches final size during late adolescence. This under-pneumatization of the frontal sinus results in a major transfer of force to the base of skull and intracranial structures during traumatic events. Still, the anterior table of the frontal sinus is the hardest bone in the face requiring at least 800 ft-kb of pressure to fracture. The management objective in frontal sinus fracture is to avoid complications while attempting to restore adequate cosmesis and functionality. Early complications include sinusitis, intracranial contents damage, CSF leak and meningitis. However, acute traumatic encephalocele is not a consistent reported finding even on cases in which the posterior table is involved. This is a case report of a 9 year old male who fell from a second floor and suffered a frontal sinus fracture with a frontal lobe encephalocele. Computed Tomography scan showed a right frontal sinus fracture involving both tables but brain tissue was only detected after Magnetic Resonant Imaging. Patient developed severe meningitis which resulted in bilateral profound sensori-neural hearing loss. A combined (endoscopic-open) approach to encephalocele resection and posterior table repair with cartilage graft was performed.

Poster #048

**Graft Thickness and Inferior Frontal Lobe Sagging after Endoscopic Anterior Skull Base Resection and Repair with Acellular Allograft**

Mohammad Al-Bar, MD  
 Ralph Abi Hachem, MD  
 Charif Sidani, MD  
 Mallory Raymond, MD  
 Zoukaa Sargi, MD  
 Roy Casiano, MD  
 Miami, FL  
 USA

**Objectives/Hypothesis:** To determine the degree of the final healed anterior skull base thickness, degree of inferior frontal lobe sagging, and complications, after a single layer, free graft technique, to repair large anterior skull base defects.

**Study Design:** Retrospective analysis.

**Methods:** The MRI's and CT's of 44 patients, from September 2006 to March 2014, were reviewed. The degree of skull base thickness, as well as inferior brain sagging, was measured postoperatively on day one, as well as several months, after final wound healing and remucosalization. Postoperative complications, and "normal" postoperative radiologic intracranial changes to the meninges and adjacent brain parenchyma was also recorded.

**Conclusions:** Anterior skull base repair with a single layer acellular allograft appears to be an effective alternative to flap repair, resulting in a thick and firm barrier, with only slight inferior herniation in most of the cases, and with no significant long-term sequelae, except for some prolonged crusting. The surgical technique will be reviewed in detail.

## POSTERS

Poster #049

**How did that get there? A Population-Based Analysis of Nasal Foreign Bodies**

Peter Svider, MD  
 Anthony Sheyn, MD  
 Vibhav Sekhsaria, MD  
 Giancarlo Zuliani, MD  
 Jean Anderson Eloy, MD  
 Adam Folbe, MD  
 Detroit, MI  
 USA

**Background:** To calculate nationwide incidence of Emergency Department (ED) visits for nasal foreign bodies (NFB), identify the most frequently encountered consumer products, and evaluate outcomes and demographic trends.

**Methods:** The Nationwide Electronic Injury Surveillance System (NEISS) was evaluated for ED visits related to NFB for the most recent five-year-span available. Nationwide incidence was calculated, and the most frequent foreign bodies were identified and organized by demographics including age and gender.

**Results:** 6,418 entries extrapolated to an estimated 198,566 ED visits nationwide were found. Out of individual case entries evaluated, median patient age was 3 years, and 42.7% of patients were male. 96.4% of patients were released after examination/treatment. Jewelry-beads comprised a plurality of NFB, followed by paper products and toys. NFB patients involving toys, building sets, pens/pencils, batteries, coins, and nails/screws were predominantly male, while female NFB-patients harbored jewelry, paper-products, and buttons. Jewelry was the most common item for patients in most age groups, while age-specific differences in the composition of remaining NFBs were noted.

**Conclusions:** A variety of consumer products carry inherent risks for becoming nasal foreign bodies, with nearly 200,000 ED visits over a five-year period. Jewelry beads, paper products, and toys were the most common products noted. Speedy recognition and retrieval of these items and other objects noted is imperative for avoidance of deleterious sequelae including but not limited to aspiration, hemorrhage, and other rhinologic complaints. Demographic-specific trends noted and organized by age and gender may be an invaluable adjunct for patient history-taking and clinical examination.

Poster #050

**How to Deal with the Inferior Turbinate of Patients Suffering of Obstructive Sleep Apnea: a Clinical Note.**

Philippe Lavigne, MD  
 Veronique-Isabelle Forest, MD  
 Marcel Baltzan, md  
 Francois Lavigne, MD  
 Montreal, Québec  
 Canada

A relationship between nasal obstruction and obstructive sleep apnea(OSA)has been proposed in several previous studies. The hypothesis is that nasal obstruction elevates nasal resistance and increases the inspiratory negative pressure in the upper airway. However, nasal surgery has less influence than expected on the apnea hypopnea index (AHI). Our hypothesis is that even if there are often 3 levels of recognized obstruction in OSA, the complete control of nasal resistance should benefit to these patients.

We have evaluated 29 patients endoscopically for septal deviation and turbinate hypertrophy. Of the 29 patients with OSA, 19 had choanal obstruction of more than 2\3. Allergy was present in 16 patients, Epworth score median was 13 and median AHI was 30. Anterior obstruction localized only at the level of the nasal valve was present in 8 patients and responded adequately to intranasal corticosteroids (INCS) or radiofrequency cauterisation (RFC) of the rostral turbinate. The caudal part of the turbinate was reduced by 90%, under nasal endoscopy , with the help of debrider blade and endoscopic scissors on 73 patients with this condition. Significant benefits were achieved for sleepiness, quality of life(QOL)scores, nasal obstruction, tolerance to C-Pap and even pressure of ventilation.

The caudal part of the inferior turbinate should be specifically evaluated in patients with nasal obstruction in order to relieve snoring or help the control of OSA.

Poster #051

**Image Quality and Dose Reduction in Sinus Computed Tomography Using Iterative Reconstruction: A Cadaver Study**

Stanley McClurg, MD  
Benjamin Huang, MD  
Satyan Sreenath, BS  
Benjamin McClintock, MD  
Charles Ebert, MD, MPH  
Brent Senior, MD  
Chapel Hill, NC  
USA

**Introduction:** Concerns about radiation dose in computed tomography (CT) imaging have renewed interest in iterative reconstruction (IR), a technique which has the potential to produce low noise images at doses lower than traditional filtered back projection (FBP). This study aimed to assess whether application of IR could provide comparable quality sinus CT images to FBP at lower kilovolt (kV) and milliamp (mA) settings, and to establish optimal scan settings for sinus imaging.

**Methods:** 120 sinus CT scans were performed on 5 cadaver heads at various kVp and mAs settings. Each scan was reconstructed using FBP and 3 IR settings, yielding a total of 600 images, which were blinded and randomly reviewed by 3 rhinologists and 2 neuroradiologists. Using a 5-point Likert scale, 16 anatomical landmarks were graded with respect to image quality, including the cribriform plate, lamina papyracea, sinus cavities, and orbital contents. Data were assessed with respect to dose and IR settings via ANOVA.

**Results:** Higher kVp and mAs settings produced significantly greater quality images for structure identification across all 16 landmarks ( $p < 0.001$ ). No significant difference was found in overall image quality, when comparing the 3 different reconstruction settings at all given dose settings ( $p = 1.000$ ). Comparing dose and IR permutations, 120kV/120mAs, 120kV/60mAs, and 100kV/120mAs settings produced acceptable average image quality scores, regardless of IR settings. Average radiation dose decreased by 50.6% at 120kV/60mAs and 40.9% at 100kV/120mAs.

**Conclusions:** Identification of structures in sinus CT imaging significantly correlate with the kV and mA dose settings, but not with reconstruction technique.

Poster #052

**Implications of Fungal Balls in Development of Invasive Fungal Sinusitis**

Adam Satteson, MD  
John Clinger, MD  
Winston-Salem, NC  
USA

**Introduction:** Fungal sinusitis is classified into invasive and non-invasive forms. Invasive fungal sinusitis (IFS) is an acute invasive infection manifesting in immunocompromised patients. IFS is characterized by aggressive and often fatal fungal angioinvasion of sinus tissue. A fungal ball is a non-invasive form of fungal sinusitis presenting as a dense accumulation of fungal debris within a paranasal sinus. This report details two cases of maxillary sinus fungal balls in association with IFS, and discusses the potential implications for the etiology and treatment protocol of the disease. There are few if any similar reports in the literature.

**Methods:** Case series and literature review.

**Results:** We present two cases in which IFS was associated with a fungal ball. This association suggests four possible etiologies: (1) IFS developed directly from fungal ball organisms. (2) Coincidental IFS developed independent of the fungal ball. (3) The fungal ball and secondary impairment of mucociliary clearance predisposed to IFS. (4) The fungal ball was never truly a fungal ball, but instead chronic IFS that became acute with immunosuppression. This association raises several considerations about an appropriate IFS treatment protocol. Should patients with a history of chronic sinusitis undergo imaging prior to immunosuppression? If a fungal ball is discovered, is pre-treatment surgical removal prudent?

**Conclusions:** Further study is required before clear recommendations can be made; however, it appears that a fungal ball in the immunocompromised patient likely predisposes to IFS, although the etiology and treatment implications remain unclear.

## POSTERS

Poster #053

**Improving Quality of Life in Recurrent Acute Rhinosinusitis: Role of Endoscopic Sinus Surgery**

Kara Detwiller, MD  
 Jeremiah Alt, MD, PhD  
 Jess Mace, MPH  
 Timothy Smith, MD, MPH  
 Portland, OR  
 USA

**Introduction:** Patients with recurrent acute sinusitis (RARS) have a significant decrease in disease-specific quality of life (QOL) and represent a challenging subset of patients to treat. After failing medical management, patients are commonly offered surgical management with limited knowledge on long-term treatment outcomes. It remains unknown whether the treatment effect of endoscopic sinus surgery (ESS) for RARS results in appreciable long-term treatment outcomes.

**Methods:** A prospective study of 19 patients with RARS undergoing surgical management with an average of 14 months follow-up was performed. Pre- and post-operative disease-specific QOL indices (SNOT-22, RSDI), medication use (antibiotics, intranasal and systemic steroids, antihistamines), and productivity were evaluated.

**Results:** Patients with RARS demonstrate a significant improvement in disease-specific QOL as measured by the SNOT-22 ( $p=0.001$ ) and RSDI ( $p=0.002$ ), and a significant decrease in days missed from productive activities ( $p=0.016$ ) and antibiotic use after ESS ( $p=0.004$ ). There was no significant change in average days of intranasal steroid or antihistamine use.

**Conclusions:** Patients with RARS who do not respond to medical management demonstrate long-term improvement in disease-specific QOL, productivity, with a concomitant decrease in antibiotic use following ESS.

Poster #054

**Inferior Meatus Maxillary Antrostomy: Time to Revisit a Previously Abandoned Surgical Technique?**

Natalie Ziegler, BS  
 Jaymarc Iloreta, MD  
 Gurston Nyquist, MD  
 Marc Rosen, MD  
 Marc Otten, MD  
 Philadelphia, PA  
 USA

A small subset of patients have terminally dysfunctional maxillary sinus mucosa as a result of chronic inflammation or iatrogenic scarring. These patients require more aggressive surgical treatment to allow for gravity dependent mucous drainage, intra-operative and office debridements, and the delivery of irrigations and topical treatments. The aim of this study is to examine the use of inferior meatus maxillary antrostomy (IMMA) in this challenging patient population. IMMA is an inferior turbinate sparing technique performed in addition to the traditional maxillary antrostomy.

**Methods:** We performed a retrospective study from February, 2008 until April, 2014 with a 122 patients undergoing a total of 135 IMMA procedures. Data was gathered regarding patient demographic, prior therapy, cultures, IMMA patency, SNOT-22 scores and the presence of disease recurrence.

**Results:** 119 patients (mean age 52) underwent 130 IMMA procedures. The mean length of follow-up was 1.5 years, and 65% had previous sinus surgery, 34 operations were for recalcitrant maxillary sinus disease, 66 for recalcitrant polyp disease, 12 for maxillary fungal disease, and 18 for odontogenic infections. 53 patients completed both pre and post-operative SNOT-22 scores, and the mean scores were 39 and 15 respectively. Out of 112 patients, 107 had a patent post-operative inferior window. There were 11 accounts of recurrent surgery required for maxillary sinus disease following IMMA.

**Conclusion:** IMMA is a safe and successful inferior turbinate sparing procedure for chronic maxillary sinus pathology.

Poster #055

**In-office Use of a Steroid-Eluting Implant for Maintenance of Frontal Ostial Patency Following Revision Sinus Surgery**

Agnieszka Janisiewicz, MD  
 Jivianne Lee, MD  
 Rohit Garg, MD, MBA  
 David Keschner, MD, JD  
 Irvine, CA  
 USA

**Background:** Achieving long-term, successful outcomes with endoscopic sinus surgery (ESS) can be challenging in patients with recalcitrant chronic rhinosinusitis. Local complications, including scar formation and ostial stenosis, can lead to recurrent blockage and subsequent relapse. The frontal sinus is particularly vulnerable to surgical failure given its narrow outflow and inaccessibility to topical therapies. The advent of steroid-eluting sinus implants has enhanced ESS outcomes; with significant reductions in synechiae, inflammation, and secondary postoperative interventions when placed in the ethmoid cavity. However, use of this technology in the frontal sinus has yet to be described. The purpose of this report is to present 2 cases in which in-office frontal placement of a mometasone furoate (MF)-eluting implant facilitated maintenance of ostial patency following revision ESS.

**Method:** Case report of 2 patients. The clinical presentation, in-office intervention, and treatment outcome were examined.

**Results:** Two patients (male; 63 and 68 years of age) with a history of multiple ESS presented with recurrent unilateral frontal headache refractory to medical therapy. Nasal endoscopy/imaging revealed frontal sinus outflow obstruction. Both declined revision ESS under general anesthesia and underwent endoscopic frontal sinustomy/ostial dilation in the clinic. A MF-eluting implant was placed in the frontal sinus at the end of the procedure, with preservation of ostial patency upon last follow-up at 3 and 11 months.

**Conclusion:** In-office placement of a MF-eluting implant successfully maintained frontal ostial patency in patients with a history of multiple ESS. Additional randomized trials are necessary to determine statistical significance, cost analysis, and long-term efficacy of frontal sinus implantation.

Poster #056

**Insurance Status and Quality of Outpatient Care for Uncomplicated Acute Rhinosinusitis**

Regan Bergmark, MD  
 Stacey Ishman, MD, MPH  
 Michael Cunningham, MD  
 Ahmad Sedaghat, MD  
 Boston, MA  
 USA

**Introduction:** Previous work suggests an association between insurance status and location of presentation (emergency department versus outpatient clinic) for evaluation of uncomplicated acute rhinosinusitis (ARS). We investigate whether the quality of outpatient care for ARS likewise differs based on insurance status.

**Study Design and Methods:** Cross-sectional study of 13,680,145 pediatric and adult patients from the 2009 and 2010 National Ambulatory Medical Care Survey diagnosed with uncomplicated ARS at an outpatient care facility. Continuity of care with the patients' primary care physician (PCP) and time spent with a physician were chosen as proxies for quality of care. Associations between insurance status and these quality measures were evaluated while controlling for clinicodemographic and socioeconomic patient characteristics and outpatient practice setting.

**Results:** There was no association between insurance status and presentation of patients to their PCP. Physicians spent more time with Medicaid patients ( $P=0.008$ ) compared to patients with private insurance or Medicare, independent of other factors. Provision of health education ( $P<0.001$ ) and increasing patient age ( $P=0.005$ ) were associated with longer visits. Residence outside of large metropolitan zip codes was associated with being seen by one's own PCP. No associations were found for race or comorbidity status.

**Conclusions:** This study did not identify any quality of care issues with respect to insurance coverage and primary care encounters for patients with ARS. In contrast to expectations, patients with Medicaid had longer outpatient physician visits and were equally likely to see their own PCP compared to patients with private insurance or Medicare.



## POSTERS

Poster #057

**Levamisole-induced Vasculitis: a Destructive New Disease Entity Affecting the Nose and Sinuses in Patients using Cocaine**

Marc Tewfik, MD, MSc, FRCSC  
 Shaun Kilty, MD, FRCSC  
 Ian Witterick, MD, FRCSC  
 Luke Rudmik, MD, FRCSC  
 Randy Leung, MD, FRCSC  
 Martin Desrosiers, MD, FRCSC  
 Montreal, QC  
 Canada

**Introduction:** It is well-known that patients with a history of cocaine use can present with severe pain, inflammation and destruction of the sinonasal passages. The precise diagnosis underlying this painful and relapsing process can be elusive, with frequent false-positive ANCA tests. Recently, levamisole has been linked to a severe form of antineutrophil cytoplasmic antibody-positive (ANCA)-positive vasculitis that may involve the face and nose, or other parts of the body. Clinicians should be alerted to this emerging health threat.

**Methods:** A case description and discussion of this newly-recognized disease entity is presented. Important take home points regarding the clinical history, examination and laboratory assessment may allow for earlier diagnosis by practicing otolaryngologists.

**Results:** Levamisole is a veterinary antihelminthic agent that is commonly added to cocaine to increase weight and volume. In North America, two-thirds of cocaine is estimated to be adulterated with this agent.

**Conclusions:** Timely recognition of levamisole-induced vasculitis is critical to avoid progression and misdiagnosis. In addition, this awareness will help doctors educate current and potential cocaine users (particularly young people) of this emerging health risk.

Poster #058

**Long-Term Changes in Quality of Life after Endoscopic Resection of Sinonasal and Skull Base Tumors**

Taylor Derousseau, MSIII  
 Lakshman Manjunath, MSIII  
 Song Zhang, PhD  
 Brian Harrow, MSIV  
 Sukhpreet Batra, MD, FACS  
 Grapevine, TX  
 USA

**Introduction:** Minimally invasive endoscopic resection (MIER) has emerged as the new standard for surgical treatment of sinonasal and skull base tumors. The objective of the present study was to evaluate QOL 2 years after MIER.

**Methods:** Prospective SNOT-20 data was accrued on 104 patients over 4 years. The study cohort included 72 patients with sinonasal malignancy, while 32 patients with inverted papilloma (IP) served as control.

**Results:** The overall and rhinologic subdomain SNOT-20 scores for cancer patients did not statistically change at 2 years ( $p=0.12$ ). They had statistically significant improvement in the psychological subdomain scores at 1 year ( $p=0.03$ ) and 2 years ( $p=0.03$ ). Similarly, the sleep subdomain scores improved at 1 year ( $p=0.04$ ) and 2 years ( $p=0.03$ ). In contrast, IP patients had statistically significant improvement in overall SNOT-20 ( $p=0.01$ ), rhinologic ( $p=0.01$ ), and sleep ( $p=0.05$ ) subdomain scores 6 months, which did not achieve statistical significance at 2 years. Analysis of various factors demonstrated that history of prior smoking adversely affected QOL scores in cancer patients, with higher total SNOT-20 scores than non-smokers ( $p=0.01$ ). Smokers also had higher psychological ( $p=0.04$ ), sleep ( $p=0.01$ ), and ear/facial ( $P=0.001$ ) domain scores than smokers at 2 years.

**Conclusion:** The long-term effects of MIER for sinus cancer demonstrated improved psychological and sleep scores at both 1 year and 2 years. Unfortunately, rhinologic QOL did not statistically improve at any of the measured time points. History of smoking was noted to be the most important predictor of QOL 2 years after MIER for sinonasal malignancy.

Poster #059

**Long-Term Outcome Analysis of Low-Pressure Osmotic Dilation of the Maxillary Ostia: 12 Months Follow-Up**

Amin Javer, MD FRCSC FARS

Peter Catalano, MD FACS

James Gordon, MD

Hesham Saleh, MBBCh FRCS FRCS

Vancouver, British Columbia

Canada

**Introduction:** Sinuplasty is a common procedure to treat chronic rhinosinusitis (CRS) by opening sinus ostia, preserving mucosa and minimizing trauma to adjacent intranasal structures. A multicenter, single-arm, prospective study was conducted to assess the safety and sustained effectiveness of a new osmotically-driven, low-pressure expansion device for dilation of maxillary sinus ostia (MSO) in patients with CRS.

**Methods:** Thirty-four CRS patients with narrowed MSO (12M/22F) refractory to medical management were enrolled across 5 study centers. Twenty-nine (85%) patients underwent MSO dilation intraoperatively in conjunction with FESS and five patients (15%) underwent MSO dilation in-office under local anesthesia. Subjects were evaluated at 3, 6 and 12 months to assess ostial patency with nasal endoscopy, sinus mucosal inflammation, and device-related/procedural complications.

**Results:** Fifty-seven ostia were accessed and dilated in all patients treated. One patient withdrew after 1 month, leaving 55 ostia available for evaluation. At 3 months, 51/55 ostia were visibly patent (93%), while 4/55 (7%) could not be adequately visualized. At 6 months, 30 patients were available for follow-up and 45/49 (92%) treated ostia were visibly patent with 4/49 (8%) not visualized. Currently, 11 patients have completed follow-up to 12 months and 14/15 (93%) treated ostia were visibly patent with 1/15 (7%) not visualized. No device related or procedural complications were encountered.

**Conclusions:** Our findings suggest that a self-expanding, low-pressure dilator could be a viable treatment for CRS patients presenting with narrowed MSO. Sustained ostial patency continues to be confirmed up to one year, among cases where the MSO was endoscopically visualized.

Poster #060

**Low-grade Sinonasal Sarcoma with Neurogenic and Myogenic Features: A Case Report**

Pedram Daraei, MD

Kelly Magliocca, DDS, MPH

John DeGaudio, MD

Atlanta, GA

USA

**Introduction:** Fibrosarcomas are rare nasal tumors that can be challenging to diagnose. Although only recently defined in the literature, there have been previous case reports and series with similar characteristics - however, given the small number of low-grade sinonasal sarcomas with neurogenic and myogenic features reported, variability in immunohistochemical staining is likely. Additional cases will help elucidate this rare neoplasm and improve diagnostic capabilities of the surgeon, thus improving management and outcome.

**Methods:** Retrospective chart review and review of the literature.

**Results:** A 48 year old male presented with right nasal obstruction, purulent drainage, and facial asymmetry. The patient had had no prior sinus surgery. Nasal endoscopy revealed a fleshy, polypoid mass. CT scan showed a large sinonasal mass with erosion of the orbit. In-office biopsy revealed a spindle cell neoplasm. Immunostaining was focally positive for smooth muscle actin (SMA). FISH showed absence of chromosome t(x;18). MRI and PET/CT revealed a large sinonasal mass centered near the middle turbinate and ethmoid air cells with possible periorbital invasion but no metastasis. Endoscopic resection revealed ethmoid involvement but no periorbital invasion. Pathology showed low-grade sinonasal sarcoma with neurogenic and myogenic features, staining diffusely positive for S100, focally positive for SMA and desmin, and showed scattered labeling for muscle specific actin.

**Conclusion:** Low-grade sinonasal carcinoma with neurogenic and myogenic features is a rare entity that is slow growing and locally destructive. Histopathological analysis is critical for proper diagnosis, with immunohistochemical staining being definitive.

## POSTERS

Poster #061

**Management of Non-Invasive Rhinosinusitis in the Immunosuppressed Patient Population**

Ashley Dao, MD  
 Shruthi Reredy, BS, MSCR  
 Sarah Wise, MD, MSCR  
 John DelGaudio, MD  
 Zara Patel, MD  
 Atlanta, GA  
 USA

**Background:** Rhinologists are seeing an increasing number of immunosuppressed patients due to advances in transplant medicine, increased longevity for HIV and cancer patients, and the diabetes epidemic. Currently, no unique treatment paradigm exists for treating acute and chronic non-invasive rhinosinusitis (ARS, CRS) in this growing population. This study aims to identify patient and treatment factors that affect rhinosinusitis outcomes in this vulnerable population.

**Methods:** All immunocompromised patients treated by rhinologists at a tertiary care institution for ARS or CRS 10/2007-10/2012 were identified first by rhinosinusitis diagnostic codes, and second by codes for transplant, cancer, HIV, diabetes, and codes indicating immunosuppression in the intensive care setting. Associations between patient factors and outcome were analyzed by logistic regression. Associations between treatment and outcome were analyzed by Firth logistic regression.

**Results:** 132 subjects were identified. 90.9% had CRS while 9.1% had ARS; 12.9% were transplant patients, 47% were diabetic, 37.9% had cancer, and 16.7% were in the intensive care unit. Transplant patients (OR=22.5, p=0.001), diabetics (OR=6.4, p=0.017), cancer patients (OR=5.4, p=0.046), and patients with prior medical therapy for rhinosinusitis (OR=5.84, p<0.001) had increased disease resolution. Patients with higher ASA scores had decreased resolution of disease (OR=0.5, p=0.021). Surgical treatment plans were associated with disease resolution. Patients treated with antibiotics alone had no statistically significant difference in disease resolution compared to those receiving no treatment.

**Conclusion:** This data indicates that surgical treatment plans provide improved outcomes for immunocompromised patients. Given the limited study population, these findings may not apply to HIV-positive or ARS patients.

Poster #062

**Management of Sphenoid Sinus Inverted Papilloma**

Tetsuya Monden, MD  
 So Watanabe, MD  
 Yoshiyuki Kyo, MD  
 Isao Suzaki, MD  
 Yuichiro Sugio, MD  
 Yasuyuki Hinohira, MD  
 Kawasaki, Kanagawa  
 Japan

**Application of Endoscopic Sinus Surgery to sinonasal inverted papilloma** has become common in recent years by the progress of its techniques and instruments. Endoscopic transnasal resection of stage T3 and T4 tumors by Krouse's classification may not be often resected en bloc. Therefore, treatment for those tumors sometimes attracts controversy over residual tumors and disseminations. In this presentation, we report three cases of inverted papilloma in the sphenoid sinus in terms of operative procedures and progresses after surgeries.

**First case:** 57-year-old male was referred to our hospital because he was diagnosed as tumor of his left nasal cavity. Biopsy specimen revealed as inverted papilloma. The base of tumor was found at the sphenoid sinus ostium, and the tumor was resected trans-nasally with superior and middle turbinates. **Second case:** 68-year-old male was seen in our clinic with the complaint of chronic nasal congestion. Tumor was found in his left nasal cavity, and its pathological diagnosis was inverted papilloma. The tumor base was found at the sphenoid sinus ostium. Tumor resection was performed with superior and middle turbinates invaded by papilloma. **Third case:** 66-year-old male came to our clinic with his CT scan, which revealed soft tissue density in the right posterior ethmoid and sphenoid sinuses. Also, tumor was found in his right nasal cavity. The tumor base was on the anterior wall of the sphenoid sinus and spread out to both lateral and medial sides. Endoscopic piece-by-piece resection was performed.

In these three cases, we have found no residual tumor.

Poster #063

**Metachronic Inverted Papilloma: an Incidental Finding?**

Eleazar Graterón, MD  
Benjamín Macías, MD  
Berman Blanco, MD  
Karla Guzman, MD  
Caracas, Miranda  
Venezuela

Clinically differentiating nasal polyps from other nasal masses is very difficult, even in nasal endoscopy and imaging. Nasal polyps typically present bilaterally but can present unilaterally. Unilateral nasal masses may be benign unilateral nasal polyps (UNP) in the context of chronic rhinosinusitis (CRS), fungal or bacterial disease, mucocoeles, and benign and malignant neoplastic processes like inverted papilloma (IP). We present a 55-year old male patient who had a UNP underwent to surgical resection, reappearing several years later with IP in biopsy results.

Poster #064

**MR Cisternogram with Intrathecal Gadolinium (MRwITG) with delayed imaging for difficult to diagnose CSF leaks of anterior skull base**

John DelGaudio, MD  
Zara Patel, MD  
Sarah Wise, MD  
Patricia Hudgins, MD  
Ashley Aiken, MD  
Kristen Baugnon, MD  
Atlanta, GA  
US

Introduction: Workup of CSF leaks can be challenging. Patients with intermittent or infrequent clear rhinorrhea that cannot be collected, those with questionable or multiple skull base defects on imaging, and those with previous skull base (SB) surgery can be a diagnostic dilemma. In this patient population radiologic studies that allow repeat imaging over several hours or days can increase the diagnostic yield. We report our experience with MRwITG in this patient population.

Methods: Retrospective chart review of patients that underwent MRwITG for workup of suspected CSF leaks at a tertiary care academic center.

Results: Over the past 3 years 9 patients (8 female, 1 male; mean age 47 years, range 34 to 59) have undergone MRwITG. Seven patients had suspected spontaneous CSF leaks from intracranial hypertension and 2 had postsurgical defects. All patients had previous imaging that was indeterminate in localizing the site of leak. Only 2 patients had positive beta-2 transferrin studies, both of which had multiple potential leak sites. MRwITG confirmed absence of leak at 3 previously repaired SB defects, identified spinal leaks but no SB leaks in 2 patients, one of which had a nonleaking SB defect, and identified 5 patients with one or more SB leaks. Repeat imaging, from 30 minutes to 20 hours, was beneficial many cases, guiding further treatment. No complications occurred.

Conclusions: MRwITG is a useful diagnostic test in the workup of the difficult CSF leak patient, with delayed imaging providing additional diagnostic information.

## POSTERS

Poster #065

**Nasal Hygiene Regimens and Compliance in Hereditary Hemorrhagic Telangiectasia**

Han Zhang, MD  
 Caroline Jeffery, MD  
 Hamdy El-Hakim, MD, FRCSEd, FRCS-ORL  
 David Cote, MD, MPH, CCFP, FRCSC  
 Edmonton, Alberta  
 Canada

**Background:** Epistaxis from hereditary hemorrhagic telangiectasia (HHT) can range from mild to life threatening. The threat of recurrent nasal bleeds often brings significant anxiety and fear to affected patients. Current management algorithms for HHT are based on a foundation of good nasal hygiene and hydration to prevent epistaxis. Little is known, however about the current nasal hygiene practices adopted by patients or their compliance with these regimens.

**Objective:** The goal of this study is to characterize the nasal hygiene regimen adopted by HHT patients at the University of Alberta Hospital.

**Methods:** This is a prospective based survey with the administration of a 4-page questionnaire. Patients were included if they had a confirmed diagnosis of HHT based on Curacao Criteria and were excluded if they had recent sinonasal surgery, refusal or participation or inability to complete the English questionnaire.

**Results:** All patients used some form of nasal hygiene regimen. Saline spray (eg. Rhinaris, Salinex) and Nasal gel (eg. Scaris, Nasogel) were the most commonly used products. Most patients used multiple agents on a daily basis and found that it provided either no change or moderate improvement in their symptoms. No patients had worsening of their symptoms while on the nasal regimen. Most patients spent up to \$1000 dollars every year on their nasal hygiene regimen.

**Conclusion:** Nasal hygiene regimen is commonly used within the HHT patient population. Most patients found that their regimen provided moderate improvement. Which agents provide the best symptomatic relief remains to be elucidated.

Poster #066

**Nasal Priming of Lung Innate Immunity**

Xiaoyang Hua, MD  
 Rahul Vijay, PhD  
 Kristy Truong, MD  
 Stanley Perlman, MD PhD  
 Iowa City, IA  
 USA

**Objective:** While local immune response in the nose and sinuses contributes to the development of sino-nasal diseases, little is known on their roles in the regulation of lung immunity.

**Methods:** A mouse model of nasal viral infection was generated by intranasally treating BALB/c mice with mouse coronavirus. A very small volume (0.25 to 1 microliter/nostril) was used for the infection to prevent aspiration. Viral titers in both nasal lavage fluids and lungs, the inflammatory response in the nasal mucosa, draining lymph nodes, bronchioalveolar lavage fluid, and lungs were determined. The effects of nasal infection on both Th1 (influenza) and Th2 (OVA) responses were also studied in vivo, respectively.

**Results:** The infected mice exhibited increased expression levels of many cytokines in the nasal mucosa and cervical lymphadenitis. While this infection failed to produce any signs of viral pneumonia, we observed significantly increased infiltration of inflammatory dendritic cells in the lung parenchyma on day 2 post-infection in the absence of viral presence in the lungs. These cells not only could take up intratracheally delivered FITC-OVA and migrate to the mediastinal lymph nodes, but also significantly reduced the clinical severity and mortality of influenza pneumonia.

**Conclusions:** Our data indicate that the nose can immunologically prime the lung innate immunity via an indirect mechanism. This priming process may generate the preparedness for the possible invasion of pathogens into the lungs and on the other hand, produce immunopathology.

Poster #067

### **Nasopharyngeal Masses Arising from Embryologic Remnants of the Clivus: a Case Series**

Mirabelle Sajisevi, MD  
Jenny Hoang, MBBS  
Rose Eapen, MD  
David Jang, MD  
Durham, North Carolina  
USA

**Objectives:** (1) To discuss rare nasopharyngeal masses originating from embryologic remnants of the clivus. (2) To discuss the embryology of the clivus and understand its importance in the diagnosis and treatment of these patients.

**Methods:** This is a case series of three patients. We discuss the clinical and imaging characteristics of patients with infrasellar craniopharyngioma, intranasal chordoma, and canalis basilaris medianus. We also review the embryology of the clivus, which needs to be considered when encountering a patient with a nasopharyngeal mass that does not have obvious involvement of the clivus.

**Results:** Case 1 is a 16 year-old male with a history of craniopharyngioma resection, who presented with nasal obstruction several years later. A peripherally enhancing nasopharyngeal cystic mass was noted to be communicating with a patent craniopharyngeal canal. Histology revealed adamantinomatous craniopharyngioma. Case 2 is a 43 year-old male with nasal obstruction and headache. Imaging revealed an enhancing polypoid mass in the posterior nasal cavity abutting the clivus. Histopathological analysis revealed chondroid chordoma, which arose from the extraosseous portion of the notochord. Case 3 is a 4 year-old female with a recurrent nasopharyngeal polyp. CT cisternogram showed a bony defect of the mid-clivus consistent with canalis basilaris medianus.

**Conclusions:** Nasopharyngeal masses can arise from embryologic remnants of the clivus without obvious involvement of the clivus. Understanding the embryology of the clivus is crucial when considering the differential diagnosis of a nasopharyngeal mass. Identification of characteristic findings on imaging is critical in the early diagnosis and treatment of these lesions.

Poster #068

### **Neurological Considerations in the Endoscopic Management of Giant Frontal Mucocoeles with Extensive Intracranial Extension: A Systematic Review**

Janalee Stokken, MD  
Eisha Wali, BS  
Troy Woodard, MD  
Pablo Recinos, MD  
Raj Sindwani, MD  
Cleveland, OH  
USA

**Introduction:** Giant frontal mucocoeles, characterized by significant intracranial and/or intraorbital extension can present with significant neurologic symptoms. Whereas typical mucocoeles are managed endoscopically, giant mucocoeles are often treated with an open or combined approach, due to various concerns including rapid decompression of the intracranial component. The impact of significant intracranial extension on outcomes is not well-described. This review studied key neurologic considerations in the management of giant frontal mucocoeles and analyzed outcomes of different management strategies.

**Methods:** Systematic literature review.

**Results:** Thirty-five articles met criteria, representing 257 cases. Neurologic symptoms on presentation ranged from headache and visual deficits, present in the majority of patients, to extremity weakness (0.5%), frontal lobe syndrome (0.9%), and seizures (1.4%). One-hundred and sixty-nine patients were treated endoscopically (65.8%), 9 (3.7%) were treated with a combined endoscopic-external approach, and the remainder were treated with an external approach. Indications for the open approach included subdural empyema, enucleation, or large anterior table defects. Perioperative antibiotics were not consistently utilized. No peri-operative seizures were reported. There were 7 CSF leaks, 2 in patients treated endoscopically. Nearly all presenting symptoms resolved after surgery. The overall recurrence rate was 0.9%, with no recurrences reported in patients treated with an open approach. Follow-up ranged from 1 week to 8 years.

**Conclusions:** Giant frontal mucocoeles often present with neurological symptoms which generally resolve with treatment. Endoscopic management is effective and preferred, except in special circumstances. Slow decompression of mucocoele contents is advised. Intra-operative seizure prophylaxis does not appear necessary with the endoscopic approach.



## POSTERS

Poster #069

**Nonfunctional Invasive Pituitary Adenoma without Suprasellar Extension: A Case Report and Review of the Literature**

Rachel Regone, MD  
 William Yao, MD  
 Masayoshi Takashima, MD  
 Houston, TX  
 USA

**Introduction:** Nonfunctional invasive pituitary adenoma without suprasellar extension is an uncommon finding without many previously reported cases. Our objective is to discuss such a case and to review current literature.

**Methods:** Case report and review of the literature

**Results:** A 63 year-old male presented with headaches and nasal congestion. He did not have visual disturbances or neurologic deficits. A computed tomography (CT) scan revealed an aggressive destructive mass centered in the clivus without any extension into the suprasellar space. The entire extension involved the sella, cavernous sinuses, nasopharynx, posterior ethmoid air cells and extension into the maxillary sinus. An endoscopic biopsy revealed a pituitary adenoma. He underwent an endoscopic subtotal resection of the tumor, leaving tumor lateral to the carotid artery. A review of over 500 papers that met search criteria in the PubMed database revealed only 5 other adequately described cases without suprasellar extension. Management strategies including our own consisted of surgery alone (3/6), surgery plus adjuvant radiation therapy (1/6), and medical management (2/6).

**Conclusions:** Invasive nonfunctioning pituitary adenoma without suprasellar extension is rare and can be mistaken for a clival chordoma, chondrosarcoma, metastasis, or lymphoma. Few authors have described the characteristics and management of such tumors; however, surgical resection appears to lead to good outcomes with relief of symptoms and a low rate of recurrence. This case report and review of the literature highlights the importance of including an invasive pituitary adenoma in the differential for destructive lesions centered in the clivus in the absence of suprasellar extension.

Poster #070

**Office Surgery for Paranasal Sinus Recirculation**

Matthew Ochsner, Mr.  
 John DeGaudio, MD  
 Atlanta, Georgia  
 USA

**Introduction:** The circular flow of mucus between adjacent openings of a single paranasal sinus is known as recirculation, and can cause persistent sinonasal symptoms. Removing the bridging tissues allows the surgical ostium to connect to the natural ostium treating this condition. This procedure prevents the circular flow between the two ostia, and allows the mucocilliary system to provide for physiologic drainage of the sinuses. Traditionally this has taken place in the operating room, however, performing this procedure in the office is possible, even when there is significant intervening bone. Here we report a series of 7 patients with recirculation successfully treated in the office.

**Methods:** A prospective study of 7 patients endoscopically diagnosed with recirculation, 6 involving the maxillary sinus and 1 the sphenoid. Symptoms included facial pressure, mucus stasis, congestion, and recurrent sinusitis. All patients had previous sinus surgery. All patients were treated in the office under topical +/- local anesthesia. The bridging tissues between ostia were removed, 4 of which were mucosal bands between ostia within the middle meatus, 2 consisted of mucosa and turbinate bone between ostia in the inferior and middle meatus, and 1 involving bone of the sphenoid face.

**Results:** All 7 patients had significant improvement or resolution of the symptoms associated with recirculation

**Conclusions:** This case series demonstrates that mucus recirculation can be successfully treated in the office setting, even across bony structures. This leads to significant savings to the healthcare system in expense and missed work compared to an operating room procedure.

Poster #071

**Olfactory Assessment and Management of Olfactory Disorders in the General Rhinology Clinic**

Irfan Syed, FRCS(ORL-HNS)  
Carl Philpott, FRCS(ORL-HNS)  
London,  
England

**Objectives:** To provide a scheme for the investigation and management of olfactory disorder in the general rhinology clinic particularly where the diagnosis is not obvious.

**Methods:** Literature review using Medline search 15th March 2014 selecting articles in the English Language.

**Results:** Results from literature review and experience from a national UK Smell & Taste Centre were used to create a collection of key concepts in the assessment and management of olfactory disorders.

**Conclusion:** Olfactory dysfunction is a common presentation to the rhinology clinic. However, once common causes like chronic rhinosinusitis are excluded there is some uncertainty regarding further assessment and management of these patients. We outline some key concepts in the assessment and management of such patients from a specialised smell & taste centre that are transferrable to the general rhinology clinic.

Poster #072

**Osteosarcomatous Transformation in Fibrous Dysplasia of the Sphenoid Bone: Case Report and Review of Literature**

Pranay Soni, BS  
Alfred Iloreta, MD  
Marc Otten, MD  
Gurston Nyquist, MD  
James Evans, MD  
Marc Rosen, MD  
Philadelphia, PA  
USA

**Introduction:** Fibrous dysplasia is a rare dysplastic condition characterized by the replacement of normal bone by benign fibrous connective tissue. Monostotic and polyostotic forms exist, with the former comprising the majority (75%-80%) of cases. Osteosarcomatous transformation in the setting of monostotic fibrous dysplasia is very rare, with only 11 cases reported in the literature. We present the first case of osteosarcomatous transformation in monostotic fibrous dysplasia of the sphenoid bone.

**Methods:** Case report and review of literature.

**Results:** A 59-year-old female presented with a 10-day history of progressively worsening dull headaches and diplopia. CT imaging showed a large osseous ground-glass lesion in the right sphenoid bone with a central area of degeneration, and MR imaging revealed a heterogeneous mass centered in the right sphenoid sinus with extension into the pterygoid wedge and cavernous sinus. In the setting of a 22-month history of fibrous dysplasia, now with likely malignant degeneration, the patient underwent a right-sided endoscopic approach to the sphenoid for biopsy of the mass. Intraoperative microscopic evaluation revealed a spindle cell sarcoma showing osteosarcomatous differentiation in the background of fibrous dysplasia. The patient is currently undergoing neoadjuvant chemotherapy with doxorubicin and cisplatin with plans for possible resection in the future.

**Conclusions:** Osteosarcomatous transformation in monostotic fibrous dysplasia remains a rare disease. There are very few cases reported in the English literature and none previously reported occurring in the sphenoid bone. This case is presented to increase awareness of the possibility of malignant transformation in otherwise unsuspecting fibrous dysplasia.

## POSTERS

Poster #073

**Otolaryngology Learning Curve After Transition to Endoscopic Transsphenoidal Pituitary Surgery**

Tasneem shikary, MD  
 Jareen Meinzen-Derr, PhD  
 Collin Edwards, MD  
 Phillip Tehodosopoulos, MD  
 Lee Zimmer, MD, PhD  
 Cincinnati, OH  
 USA

**Background:** Previous experiences with transitioning to endoscopic techniques have revealed steep operative learning curves. The purpose of the current study was to delineate an operative learning curve after transition to pituitary resection through an endoscopic transsphenoidal approach.

**Study Design** A retrospective chart review was performed from April 2006 until February 2010.

**Methods:** Demographic data, tumor type, operative times, complication rates, and follow up periods were documented. Complications recorded include cerebrospinal leak, meningitis, epistaxis, septal osteomyelitis, anosmia, nasal obstruction, septal perforation, and sinusitis. Analysis was performed on two-hundred and two consecutive patients to delineate a learning curve.

**Results:** The mean age was 50.9 years with a range of 13.8-81 years. Forty-eight percent of patients were male and 51.5% were female. Average operative time was 134.2 minutes. Complication rates were 9.9% for temporary nasal obstruction, 8.4 % for cerebrospinal leak, 7% for post-operative epistaxis, 4.5% for sinusitis, 2.4 % for septal osteomyelitis, 1.5 % post-operative sellar hematoma, 0.5 % for anosmia, and 0.5 % for septal perforations. There was a decrease in operative time with increasing experience with a learning curve of 120-130 procedures. Cerebrospinal fluid (CSF) leak rates decreased with order of procedure plateauing after 80-90 procedures (OR 0.987, p = 0.01).

**Conclusion:** This study reports an initial learning curve for the first two-hundred and two patients in terms of operative time and improved outcomes with increasing operative experience. These findings support the notion that collaboration between a specialized otolaryngologist and neurosurgeon can predict safe transition to endoscopic pituitary surgery.

Poster #074

**Outcomes of Image Guided Sinus Surgery for Chronic Rhinosinusitis in a Tertiary Referral Centre**

Francesco Egro, MBChB, MRCS, MSc  
 Liam Masterson, MD, MRCS, DOHNS  
 Jessica Bewick, MRCS, DOHNS  
 Carl Philpott, FRCS  
 Gorleston, Norfolk  
 United Kingdom

**Background:** Functional endoscopic sinus surgery has been the mainstay for the surgical management of chronic rhinosinusitis. However, image guidance surgery is an emerging technology that provides a safe and cost effective alternative, and may decrease surgical revision rates, thus allowing a more efficient treatment of sinus disease. The aim of this study was to assess the early outcomes of image guidance sinus surgery with respect to quality of life.

**Methods:** A retrospective review of all patients who underwent bilateral image guided sinus surgery between January 2011 and December 2013 was performed.

**Results:** A total of 219 patients underwent image guided sinus surgery. The diagnoses included chronic rhinosinusitis with nasal polyposis (58%, n=126), without nasal polyposis (29%), and various forms of allergic/eosinophilic fungal rhinosinusitis (11%). A total of 49 patients (22.4%) had undergone previous endoscopic sinus surgery and 1.4% (n=3) required further revision in the scheduled time period. Two patients (0.9%) had specific surgical complications and 3 patients required an overnight admission on the day of surgery. A statistically significant decrease in SNOT-22 scores was observed and was comparable between aetiologies.

**Conclusion:** This study provides short-term evidence that navigational surgery performed in a uniform manner can result in significant patient gain. This was particularly noted terms of quality of life, low requirement for revision surgery and a high day case discharge rate.

Poster #075

### **Overuse of CT for Acute Sinusitis in the Primary Care Setting**

Sarah Novis, MD  
Sarah Akkina, BS  
Shana Lynn, BS  
Haley Kern, BS  
Matthew Davis, MD, MAPP  
Melissa Pynnonen, MD, MSc  
Ann Arbor, MI  
USA

**Introduction:** Sinusitis is a major source of healthcare spending in the primary care setting. One of the contributors to this high cost is CT imaging studies. The American Academy of Otolaryngology Clinical Practice Guidelines recommend that patients meeting diagnostic criteria for acute sinusitis should not undergo CT imaging within 28 days of diagnosis, as this is not cost effective and exposes patients to unnecessary radiation.

**Methods:** We created a retrospective cohort of adults diagnosed with acute sinusitis (ICD-9 code 461.X) in a primary care clinic or emergency department setting over a two year period. Patients undergoing a CT of the head or maxillary sinuses were identified and radiology reports reviewed.

**Results:** There were 1302 patients diagnosed with acute sinusitis during the study period. 44 of these patients (3.4%) underwent CT scan performed within 28 days of the initial diagnosis. Predictors of CT included visit location in the emergency room, male gender, presence of nasal drainage, facial pain, subjective fever, and history of migraine headaches, diabetes and depression on bivariate analysis ( $p < 0.05$ ). Patients undergoing CT were significantly more likely to be treated with antibiotics, analgesics and nasal steroids ( $p < 0.05$ ). 36/44 (81.8%) had some evidence of sinusitis on CT, read as mild in 50.0%, moderate in 44.4% and severe in 5.6%. An otolaryngology referral was given to 34.1% of patients undergoing CT scan.

**Conclusions:** Inappropriate ordering of CT for acute sinusitis is related to multiple patient factors and remains an area for quality improvement in the primary care setting.

Poster #076

### **Peripheral Blood Eosinophilia Correlates with Nasal Polyp Growth**

Jean Kim, MD PhD  
Virginia Drake, BS  
Baltimore, MD  
USA

**Introduction:** Eosinophils are thought to play a significant role in nasal polyposis, but the exact mechanism by which they contribute to polyposis remains unclear. We, therefore, proposed to test the hypothesis that peripheral blood eosinophilia (PBE) is a biomarker for polyp growth. To do this we examined whether PBE levels correlate with nasal polyp size in a longitudinal manner.

**Methods:** We retrospectively analyzed the fluctuation of PBE and nasal polyp load in each patient ( $n=61$ ) assessed preoperatively, postoperatively, and during later follow up. Nasal polyp load was assessed using endoscopy and CT scan, when available using Lund-McKay scores. Correlation coefficients were analyzed using non-parametric and parametric statistics.

**Results:** There was a positive correlation between initial baseline PBE and nasal endoscopic load of polyps (Spearman rank correlation coefficient 0.22,  $p < 0.009$ ). When patients were analyzed longitudinally, we found that PBE correlated nasal endoscopy scores obtained at or near the same time point ( $p < 0.006$ ). However, if initial PBE was  $> 450$ , then no correlation occurred. When nasal polyp load increased with time, we observed stepwise increase in eosinophil counts ( $p < 0.008$ ).

**Conclusions:** PBE is a biomarker for nasal polyp growth. PBE levels may be used along with nasal endoscopy to prospectively follow nasal polyp load in patients with chronic rhinosinusitis with hyperplastic nasal polyposis.

## POSTERS

Poster #077

**Pneumatization and Anterior Ethmoid Artery Location in the Pediatric Population**

Gitanjali Fleischman, MD  
 Stanley McClurg, MD  
 Charles Ebert, Jr, MD  
 Chapel Hill, NC  
 USA

**Introduction:** The Anterior Ethmoid Artery (AEA) is a vital anatomic landmark in endoscopic sinus surgery. In adults, paranasal sinus pneumatization is associated with aeration around AEA, but this relationship has not been reported in the children.

**Objectives:** To establish the frequency of AEA location below the skull base in children, and determine association between sphenoid sinus pneumatization and location of AEA below the skull base.

**Methods:** Maxillofacial computer tomography scans of pediatric patients < 18 years were graded for the location of 100 AEA foramina (above or below skull base) and degree of sphenoid sinus pneumatization (conchal, pre-sellar or sellar/post-sellar) was determined.

**Results:** AEA Foramina could be identified in 99% of cases. AEA was located within the skull base in 100% of patients with conchal and 28.6% of patients with pre-sellar pneumatization pattern. Bilateral AEAs below skull base were noted in 32% of CT scans, and 81.2% of these had a sellar/post-sellar sphenoid pneumatization. Youngest age at which the AEA was found below skull base was four years. Average age of patients with AEA within the skull base was 10.81, which was 24.7% younger than those with AEA below the skull base bilaterally (14.38,  $p < 0.00001$ ).

**Conclusion:** AEA location below skull base is associated with increased sinus pneumatization and age. Instances of early descent of the AEA below the skull base was observed in children as young as four. Presence of any sphenoid pneumatization in a pediatric patient should increase index of suspicion for AEA location below the skull base.

Poster #078

**Prospective Trial of Pulsating Nasal Wash in Cadavers Undergoing Sinus Surgery**

Philip Chen, MD  
 Jae Murphy, MBBS  
 Samuel Boase, BMBS (Hons), PhD  
 Peter-John Wormald, MD, FRACS, FRCS (Ed)  
 San Antonio, TX  
 USA

**Background:** Nasal irrigation is standard in the management of chronic rhinosinusitis before and after surgical intervention. Numerous irrigation devices are commercially available, however many have not been clinically validated. The aim of this study was to compare the efficacy of a low pressure pulse irrigator against the gold standard squeeze bottle irrigator in maxillary, sphenoid, and frontal paranasal sinuses before and after endoscopic sinus surgery (ESS).

**Methods:** Five cadaveric specimens were prepared with visualization ports into each sinus facilitating video-documentation of the irrigation. ESS was performed on each cadaver from minimal to maximal dissection, completed with a modified endoscopic Lothrop procedure. Both devices were used to irrigate the sinus systems with a fluorescein solution following each dissection. A blinded independent observer scored each irrigation according to a defined scale.

**Results:** Comparison of the two devices using an intraclass correlation coefficient (ICC=0.39) showed the two systems differed. Observation of individual sinuses showed the squeeze bottle consistently provided greater irrigation in the maxillary ( $p=0.0006$ ), frontal ( $p < 0.0001$ ) and sphenoid ( $p < 0.0001$ ) sinuses. Pulsated irrigation improved following ESS in the maxillary ( $p=0.0276$ ), but not in the frontal or sphenoid sinuses.

**Conclusion:** The squeeze bottle consistently demonstrated superior irrigation in both native and operated conditions. ESS offers marginal improvement in sinus penetration when combined with a low pressure pulsated irrigation device. Nasal irrigation delivery devices have many advantages if used judiciously and when the device is appropriately selected for the patient and disease.

Poster #079

### **Radiographic Study for Rapid Identification of the Sphenopalatine Foramen**

Anne Maxwell, MD  
Henry Barham, MD  
Vijay Ramakrishnan, MD  
Aurora, CO  
USA

**Introduction:** Transnasal endoscopic sphenopalatine artery ligation (TESPAL) is becoming the procedure of choice for surgical control of intractable posterior epistaxis. Identification of the sphenopalatine artery as it exits the sphenopalatine foramen (SPF) traditionally relies on identification of the crista ethmoidalis, and landmarks for rapid identification of this bony prominence can facilitate surgical exposure. This study examines distances from easily identified endoscopic surgical landmarks to the SPF for use in TESPAL.

**Methods:** Using computed tomography (CT) sinus scans to study radiologic anatomy in 50 adults, distances were measured between five simple endoscopic landmarks and the SPF. Microsoft Excel was used for statistical analysis.

**Results:** Five measurements were recorded bilaterally on 50 adult CT scans for a total of 500 measurements. Right- and left-sided measurements were similar. Mean distances to the SPF in the anteroposterior dimension are reported from the maxillary line (36.7 +/- 5.5 mm), anterior head of the middle turbinate (33.8 +/- 6.7 mm), basal lamella (11.8 +/- 1.9 mm), and choanal arch (-9.2 +/- 1.4 mm). Mean distance in the vertical dimension is reported from the nasal floor (26.6 +/- 2.6 mm). Female patients had statistically shorter distances from the SPF to the maxillary line ( $p = 0.01$ ), anterior head of the middle turbinate ( $p = 0.03$ ), choanal arch ( $p = 0.01$ ) and nasal floor ( $p = 0.01$ ).

**Conclusions:** TESPAL is the surgical workhorse in the management algorithm for intractable epistaxis. Knowledge of standard distances from simple endoscopic landmarks will help facilitate rapid surgical exposure during this procedure.

Poster #080

### **Rate of Postop CSF Leak after torn Nasoseptal Flap Reconstruction of Skull Base Resections**

Colin Huntley, MD  
Alfred Iloreta, MD  
Christopher Farrell, MD  
Gurston Nyquist, MD  
James Evans, MD  
Marc Rosen, MD  
Philadelphia, PA  
US

**Introduction:** The Nasoseptal Flap (NSF) has been shown to be a valuable addition to the reconstructive armamentarium of an endoscopic skull base surgeon. NSF harvest is often complicated by inadvertent perforation of the donor tissue due to septal spurs or deviation. We aim to evaluate the rate of post-operative cerebrospinal fluid (CSF) leak after use of a NSF that has had a perforation during harvest.

**Methods:** After IRB approval, we analyzed our database of patients undergoing skull base resection. Patients undergoing skull base repair using a NSF were identified. Computed tomography scans were reviewed and patients with clinically significant septal deviations and septal spurs were selected. A senior otolaryngology resident and a rhinology fellow then reviewed intraoperative video for perforation of the NSF. Data including diagnosis, type of reconstruction, procedure, presence of NSF tear, post-operative CSF leak, and lumbar drain placement were recorded.

**Results:** 21 patients were identified that had a skull base procedure with reconstruction using a NSF, and had either a septoplasty or evidence of a septal spur on coronal CT. Of these 21 patients, 11 patients had identified intraoperative perforations of the NSF confirmed by intraoperative video. Zero patients with a perforated NSF had a post-operative CSF leak

**Conclusions:** Our series shows a 0% postop CSF leak rate in patients undergoing skull base resection and reconstruction with a NSF that was perforated during harvest. Small perforations in NSF do not affect post-operative leak rates and should not be considered a contraindication for use of donor tissue.



## POSTERS

Poster #081

**Safety, Feasibility, and Efficacy of Placement of Steroid-Eluting Bioabsorbable Sinus Implants in the Office Setting: A Prospective Case Series**

Keith Matheny, MD  
 Kenny Carter, Jr, MD  
 Ewen Tseng, MD  
 Karen Fong, MD  
 Frisco, TX  
 USA

**Background:** The outcomes of endoscopic sinus surgery (ESS) for chronic rhinosinusitis (CRS) can be compromised by postoperative inflammation, recurrent polyposis, middle turbinate lateralization, and synechiae, often requiring subsequent interventions. A bioabsorbable, steroid-releasing sinus implant, placed in the operating room following ESS, has been proven effective in two prospective, randomized clinical trials and a subsequent meta-analysis for its ability to preserve sinus patency, as well as reduce medical and surgical interventions postoperatively. This trial sought to evaluate the methods and outcomes of implants placed in the office after achieving hemostasis.

**Methods:** Twenty subjects with CRS underwent ESS including bilateral ethmoidectomy. Steroid-eluting bioabsorbable implants were deployed into each ethmoid cavity in the office within 7 days after ESS. Endoscopic appearance of the ethmoid cavities was evaluated at 1, 2, & 4 weeks postoperatively by the operating surgeon, as well as an independent evaluator, for middle turbinate position, synechiae, polyposis, and ethmoid patency. SNOT-20 questionnaires were completed at each postoperative visit. Procedural tolerance questionnaires were completed at Week 2.

**Results:** In-office placement of steroid-eluting bioabsorbable implants was well-tolerated with 90% of patients very satisfied with the overall experience and 80% very satisfied with the recovery process. At one month, there were no significant adhesions or frank polyposis. Middle turbinate lateralization was 5.0%. The mean SNOT-20 score demonstrated a statistically significant improvement from baseline to Week 4 (42.8 to 8.94;  $p < 0.001$ ).

**Conclusion:** In-office placement of steroid-eluting bioabsorbable implants after achieving hemostasis is well-tolerated, and may improve local drug diffusion to further improve surgical outcomes.

Poster #082

**Schneiderian Papilloma of the Lacrimal Sac**

Rachel Arffa, MD  
 David Clark, MD  
 Temple, TX  
 USA

**Introduction:** Schneiderian papillomas (SP) are benign but infiltrative epithelial neoplasms with malignant potential characterized by a high recurrence rate. Majority of cases arise from the nasal wall and paranasal sinuses. In this case report, we demonstrate a SP confined to the lacrimal duct and sac.

**Methods:** This article is a case report of a rare presentation of SP.

**Results:** A 45-year-old male presented with 10 months of right-sided epiphora and swelling of his medial right lower eyelid area. He was found to have a 10 mm x 10 mm area of distension in the vicinity of the right lacrimal sac and underwent an external dacryocystorhinostomy. Surgical pathology showed SP with inverted features. A computed tomography scan revealed an expansile mass in the right nasolacrimal duct area as well as bilateral pansinus disease and a left septal deviation. The patient was subsequently referred to Otolaryngology and underwent right endoscopic sinus surgery and endoscopic dacryocystorhinostomy. Surgical pathology confirmed the diagnosis of SP within the lacrimal sac and duct. No evidence of SP was found within the nasal cavity or sinuses.

**Conclusions:** This case illustrates the importance of including Schneiderian papilloma, a benign but invasive neoplasm, in the differential diagnosis of nasolacrimal duct obstruction.

Poster #083

**Selective Use of Alloplastic Nasal Implants in Septorhinoplasty: Case Series and Review of Literature**

Irfan Syed, FRCS (ORL-HNS)  
Nikul Amin, MRCS  
Waseem Ahmed, MRCS  
Abbad Toma, FRCS (ORL-HNS)  
London,  
England

**Outcome Objectives:** Describe the selective use of alloplastic nasal implants in reconstructive surgery.

**Methods:** Case series of patients at St George's Hospital, London under the care of a single surgeon. These included a mix of primary cases, revision cases and complex nasal deformity secondary to granulomatous disease. A literature review of the use of alloplastic implants in rhinoplasty surgery was performed.

**Results:** Medline Search on 6th January 2014 identified 19 articles for consideration alongside the case series of the author. The use of alloplastic implants in our case series was associated with favourable cosmetic outcome in all patients with no cases of implant infection or extrusion.

**Conclusions:** The use of alloplastic material is an area of controversy in rhinoplasty. There has been concern regarding perceived high rates of infection, extrusion & other complications. Our short case series on our selective use of porous polyethylene implants for septorhinoplasty in the UK shows favourable outcomes at follow up of up to two years. We present literature which also supports the use of alloplastic materials in rhinoplasty when used for selective indications

Poster #084

**Septorhinoplasty can be Performed as Day Surgery Without Jeopardising Patient-Reported Outcomes**

Neeraj Sethi, MRCS  
Rupert Simpson, MBChB  
Sanjai Sood, FRCS (ORL-HNS)  
David Strachan, FRCS (ORL-HNS)  
Leeds, West Yorkshire  
UK

**Introduction:** The postoperative management of rhinoplasty/septorhinoplasty patients remains debated amongst surgeons. There is a wide variation in practice in terms of surgical approach, technique and whether these are performed as day case or inpatient surgery. Day case surgery is cost effective and resource conserving.

We aimed to evaluate if patient reported outcomes differed in patients whom had undergone septorhinoplasty as a day case compared to those treated as an inpatient.

**Methods:** All septorhinoplasty and rhinoplasty operations performed over a four-year period at Bradford Teaching Hospitals NHS Trust were identified. These patient case notes were then reviewed to obtain patient demographics, operation details (including details of whether the patient was packed or not at the time of surgery) and any post-operative complications. The Glasgow Benefit Inventory (GBI) was administered via telephone to measure patient-reported outcomes.

**Results:** In total 167 patients were identified for 11 of whom the case notes were unavailable. Of the 156 patients remaining, 126 completed the GBI questionnaire (who had undergone 132 operations). 38 patients were treated as a day case whilst 88 were treated as an inpatient. No day case patients required readmission to hospital after discharge. No significant difference in patient reported outcomes (GBI scores) was found between patients treated as a day case compared to those treated as an inpatient.

**Conclusion:** This study suggests that in appropriate patients septorhinoplasty can be performed as a day case safely and with confidence that the patient outcome and experience is not being compromised

## POSTERS

Poster #085

**Significant Increases of Pituitary Tumors and Resections from 1993 to 2011**

Jennifer Villwock, MD  
 Mark Villwock, MSE  
 Eric Deshaies, MD  
 Parul Goyal, MD  
 Syracuse, NY  
 USA

**Background:** Pituitary tumors comprise 10-15% of all diagnosed intracranial tumors. 90% are adenomas. Though benign, significant morbidity via compression of surrounding structures or aberrant hormone secretion can occur. This study investigated rates of pituitary tumor diagnoses and treatment trends from 1993 to 2011.

**Methods:** Retrospective review of the 1993 to 2011 Nationwide Inpatient Sample for patients diagnosed with pituitary tumor as well as those patients who underwent pituitary tumor resection. Incidences of pituitary lesions, surgical approaches, and clinical and economic outcomes were evaluated.

**Results:** The rate of primary and secondary diagnoses of pituitary tumor per 100,000 persons significantly grew over the study period (Correlation coefficient = .934 and .987, respectively,  $P < .001$ ); a significant increase in the number of pituitary resections performed annually (Correlation coefficient = .942,  $P < .001$ ) were also seen. Admissions with a primary diagnosis of pituitary neoplasm experienced significant decreases in length of stay over time (Correlation coefficient =  $-.913$ ,  $P < .001$ , Table 1) and mortality (Correlation coefficient =  $-.697$ ,  $P = .001$ ). Interestingly, hospital charges more than tripled over the same time span (Correlation coefficient = .970,  $P < .001$ ). Transfrontal resections decreased linearly with time.

**Conclusions:** Pituitary tumor diagnoses and resections have grown significantly over the past 20 years. Transsphenoidal surgical resection among this patient population has significantly increased, while transfrontal resections have decreased.

Poster #086

**Sinonasal and Skull Base Pleomorphic Adenoma: A Case Series and Literature Review**

Edward Kuan, MD  
 Miguel Palma Diaz, MD  
 Alexander Chiu, MD  
 Marilene Wang, MD  
 Marvin Bergsneider, MD  
 Jeffrey Suh, MD  
 Los Angeles, CA  
 USA

**Introduction:** Pleomorphic adenoma (PA) is the most common benign neoplasm of the major salivary glands. PA of the paranasal sinuses and skull base is an extremely rare pathologic entity. We report three cases of sinonasal and skull base PA and discuss clinical course, diagnosis, and management.

**Methods:** Retrospective review of patients with PA of the sinuses and skull base treated at two tertiary academic medical centers.

**Results:** Two patients presented with disease at the skull base (clivus and sphenoid sinus) from parotid primaries after repeated parotidectomies and adjuvant radiation therapy. Both patients were found to have skull base recurrences which were unresectable. The third patient presented with primary disease in the maxillary sinus and had distal metastasis 9 months after surgery. Pathologic analysis of all samples demonstrated PA, with the maxillary sinus primary also demonstrating carcinoma ex-PA.

**Conclusion:** PA of the sinus and skull base is a rare tumor that behaves more aggressively than PAs found in the major salivary glands. Accurate tumor sampling is essential for surgical planning, as malignant transformation does occur. In certain cases of unresectable tumors, endoscopic debulking may improve patient symptoms and quality of life.

Poster #087

### **Sinonasal Hamartoma: A Case Series and Literature Review**

Luke Donatelli, MD  
Aaron Pearlman, MD  
New York, NY  
USA

**Introduction:** Sinonasal hamartomas are rare, benign tumors characterized by submucosal proliferation of glandular tissue. The differential diagnosis for these tumors includes benign and malignant masses such as antrochoanal polyp, inflammatory polyposis, inverted papilloma, and adenocarcinoma. We present two patients with sinonasal hamartomas and review the existing literature to describe the diagnosis and management of these tumors.

**Methods:** Case series and literature review

**Results:** Case 1: A 76-year-old woman presented with left sided nasal obstruction and anosmia. Examination showed a mass obstructing the left nasal cavity, originating from the cribriform region. A CT scan showed a 4.3 cm lesion, with possible dehiscence in the cribriform plate. MRI could not rule out encephalocele. The mass was completely surgically excised and no skull base dehiscence was seen. The diagnosis of chondro-osseous hamartoma was confirmed by histopathology.

**Case 2:** A 65-year-old woman presented with chronic headaches and was found to have a left nasal mass originating in the sphenothmoidal recess. CT scan showed a 3.2 cm mass, contiguous with the inferior wall of the sphenoid sinus. A complete surgical resection was performed. Preoperative biopsy and intraoperative frozen section were consistent with inflammatory polyp; however, ultimately the lesion was found to be a sinonasal hamartoma.

**Conclusion:** Sinonasal hamartomas are rare, benign lesions, which are not locally destructive. Complete surgical excision is the treatment of choice. As they can grossly appear similar to more aggressive pathology, it is important for clinicians to be aware of this disease entity in order to counsel and manage patients appropriately.

Poster #088

### **Sinus Surgery in Organ Transplant Recipients**

Rachel Arffa, MD  
David Clark, MD  
Temple, TX  
USA

**Introduction:** Organ transplant recipients are on chronic immunosuppressing agents, spend more time in hospitals than otherwise healthy patients, and often have abnormal clotting function. There are also studies showing that patients with organ transplant may be more prone to chronic rhinosinusitis (CRS). We hypothesized that those with CRS would be more likely to have a larger number of infections, drug-resistant infections, and increased bleeding with sinus surgery compared to CRS patients who have not had an organ transplant.

**Methods:** This study is a retrospective analysis of patients who underwent functional endoscopic sinus surgery (FESS) at Baylor Scott and White Hospital/Texas A&M between September of 2011 and December of 2013.

**Results:** Six organ transplant recipients underwent FESS during this time period. When compared to non-transplant patients who underwent equivalent FESS, no statistical difference was found in intraoperative bleeding rates, time of surgery, or number of postoperative infections. However, transplant recipients did have an increased rate of postoperative hemorrhage requiring control in the operating room (2/6 versus 0/6). Transplant recipients were also more likely to require escalation of antibiotics and compounded sinus irrigations (5/6 versus 0/6).

**Conclusion:** Despite their chronic immunosuppression and increased risk for abnormal clotting function, organ transplant patient do not have increased postoperative infections or intraoperative bleeding. However, they do have increased postoperative hemorrhage and increased requirement of escalation of antibiotics and compounded sinus irrigations.

## POSTERS

Poster #089

**Skullbase Crossbow Projectile Injury with Endonasal Repair of Cerebrospinal Fluid Leak: A case presentation**

Alexander Sevy, MD  
 Kathleen Gallagher, MD  
 Masayoshi Takashima, MD  
 Houston, TX  
 USA

Outcome Objectives:

1. Describe the workup and management of skull base projectile injuries including repair of cerebrospinal fluid leak.
2. Review of the literature of management of projectile injuries to the skull base

**Methods:** This case study was conducted between October – December 2013 involving the diagnosis and treatment of an adult male with an intraoral skull base projectile injury and subsequent cerebrospinal fluid leak. The clinical and surgical management of the subject was studied as both inpatient and outpatient. A multidisciplinary team comprised of anesthesia, interventional radiology, psychiatry and neurosurgical services along with otolaryngology skull base staff managed the care of this patient. Angiography and removal of the crossbow bolt and subsequent repair of cerebrospinal fluid leak in the operating room was performed. Our outcome measurements were survival, cerebrospinal fluid leak, and neurologic status.

**Conclusion:** This represents a case study of a rare intraoral skull base crossbow injury and the unique management variables involved with the diagnosis and treatment. A multidisciplinary approach is critical in the management of all intracranial skull base projectile injuries and subsequent repair of the defect and cerebrospinal fluid leak. We present this case and review of the literature.

Poster #090

**Spontaneous CSF Leaks Associated with Idiopathic Intracranial Hypertension: a Decade of Experience**

Raewyn Campbell, MD  
 Nithin Adappa, MD  
 Nina Zhao, MD  
 Brad Woodworth, MD  
 Douglas Farquhar, MD  
 James Palmer, MD  
 Philadelphia, PA  
 USA

**Background:** Endoscopic endonasal repair of cerebrospinal fluid (CSF) rhinorrhea secondary to idiopathic intracranial hypertension (IIH) has success rates of greater than 90% with minimal morbidity but often these series have relatively short-term follow-up. Given the pathophysiology of IIH, long-term follow up is necessary to identify true CSF leak recurrence rates. Our investigation aimed to evaluate long-term outcomes in endoscopically repaired CSF leaks.

**Methods:** Retrospective chart review of all patients with CSF rhinorrhea due to IIH who met inclusion criteria between 2001 and 2009. Outcome measures included: body mass index (BMI), ICP, skull base defect location, surgical repair technique, post-operative treatment with acetazolamide, ventriculoperitoneal (VP) shunt use, complications, recurrence of CSF rhinorrhea and the location of recurrence.

**Results:** Thirty two patients were reviewed over a mean follow-up of 12.6 years. Mean BMI and ICP were 36.6 and 27.2cm H<sub>2</sub>O respectively. Seven patients (21%) required revision surgery at the same site or a distant site. We found no statistical significance identifying recurrence risk was identified in the outcome measurements of BMI, ICP, repair technique, leak location, acetazolamide or VP shunts.

**Conclusion:** IIH is an increasingly recognized entity treated by otorhinolaryngologists. We present the first long-term IIH CSF leak repair series (mean follow-up 10 years). No outcome measure identified increased risk.

Poster #091

**Steroid Therapy Without Antibiotics for Chronic Rhinosinusitis Without Polyposis**

Jose Mattos, MD, MPH  
Stella Lee, MD  
Pittsburgh, PA  
USA

**Introduction:** Antibiotics are often prescribed for patients with chronic rhinosinusitis without nasal polyposis (CRSsNP) even in the absence of clinical infection. Our goal was to examine outcomes of patients with CRSsNP treated with a course of oral steroids and standard topical therapy, without antibiotics.

**Methods:** 13 patients with CRSsNP were prospectively enrolled in this study. None of the patients exhibited purulence on nasal endoscopy and were treated with a 4-week oral steroid taper in addition to standard topical therapy, including nasal saline irrigations and topical nasal steroids. None were prescribed antibiotics. Pre and post-treatment CT scans were obtained, and Lund-Mackay scores (LMS) were calculated. Additionally, pre and post-treatment sino-nasal questionnaires (SNQ) and Short-Form 12 (SF-12) were obtained. One-tailed, paired t-test analysis was performed.

**Results:** The average reduction in LMS was 4.2 ( $p = 0.006$ ). The average reduction in the SNQ was 0.3 ( $p = 0.02$ ). For the SF-12 scores, there was no significant difference in the physical composite scale, but the mental composite scale showed an average improvement of 12.5 points ( $p = 0.01$ ). 5 of 13 patients (38%) eventually required surgical therapy, but the remaining 8 patients were able to avoid surgery and were maintained on topical therapy.

**Conclusion:** Withholding antibiotics when no purulence is seen in patients with CRSsNP, and treatment with a 4-week course of oral steroids and topical therapy only provides significant reduction in radiologic scores, as well as symptomatology and quality of life.

Poster #092

**Steroid-eluting Sinus Implant (Propel Stent) and Adhesion Formation: One Surgeon's Experience**

Thomas Heineman, BA  
Luke Donatelli, MD  
Angela Donaldson, MD  
Vijay Anand, MD  
New York, NY  
USA

**Objective:** Outcomes after endoscopic sinus surgery (ESS) are commonly compromised by adhesion formation. The Propel stent (Intersect, CA) is an absorbable sinus stent that functions as a mechanical spacer and as a delivery system for mometasone furoate. The aim of this study is to evaluate the outcomes of a stent versus non-stent patient population

**Study Design:** Retrospective review

**Setting:** Single surgeon rhinology practice

**Subject and Methods:** Medical charts were reviewed on patients who had undergone ESS between January 2012 and August 2013. Patients were grouped based on placement of the stent during surgery or not. Charts were evaluated for postoperative synechiae. The non-stent group was considered the control. Postoperative nasal endoscopy findings for both stent and control groups, were evaluated within 10 days, between 20 and 40 days, and between 70 and 110 days of the surgical procedure.

**Results:** One hundred and thirty two patients underwent ESS during the study period, which included 58 stent and 71 control sides. At the second postoperative visit, the rate of adhesion formation was 8.6% for the stent group and 9.9% for the control group, which was not statistically different ( $p$ -value = 1.0). Twenty-six stent sides and 34 control sides were seen for a third visit, at which time 27.3% in the stent group and 11.1% in the control group had developed adhesions ( $p$ -value = 0.16).

**Conclusions:** This study represents a single surgeon's experience and shows no statistical difference in postoperative rates of adhesion in patients with or without stent placement.



## POSTERS

Poster #093

**Subjective Olfactory Dysfunction is associated with Higher Body Mass Index**

Zara Patel, MD  
 Sarah Wise, MD, MSCR  
 John DeGaudio, MD  
 Atlanta, GA  
 USA

**Background:** Morbidly obese patients have been found to show altered olfactory acuity. Recently it has been shown that adiponectin, a hormone inversely correlated with body fat, increases the responsiveness of mature olfactory neurons. To date, there has been no study directly assessing Body Mass Index (BMI) in patients with olfactory dysfunction. The purpose of this study was to compare BMI in a group of patients with subjective olfactory dysfunction to a group without subjective olfactory complaints.

**Methods:** Retrospective matched case-control study. Sixty patients were identified via diagnosis codes and SNOT-22 responses, who presented to a tertiary care rhinologic center with subjective smell dysfunction over the course of one year. Neoplastic and obstructive etiologies were excluded. Demographic data such as age, gender, and race were reviewed, as well as BMI and smoking status. Sixty age, gender and race matched control patients were selected from those also presenting to the rhinology practice over the last year, but without subjective olfactory dysfunction. Chi-square testing was used.

**Results:** 48 out of 60 patients (80%) in the olfactory dysfunction group fell into the overweight or obese categories, compared to 36 out of 60 patients (60%) in the control group. Chi-square testing showed this was a statistically significant difference ( $p=0.0168$ ).

**Conclusions:** High BMI appears to be correlated with olfactory dysfunction. Prospective clinical research should examine this further to determine if increasing BMI may be a risk factor for olfactory loss or lack of olfactory recovery after an inciting event.

Poster #094

**Surgical Monitor Height Ergonomics**

Erik Weitzel, MD  
 Fort Sam Houston, TX  
 USA

**Introduction:** A surgeon's eyes should be positioned 1 meter distant and no more than 15 degrees below the top of an operating monitor (10.5in).

**Methods:** Floor to eye height was measured for surgeons in seated (SEA), perched (PER), and standing (STA) positions. These ranges plus a height adjustment (10.5 inches) were then compared to vertical displacement ranges for monitors measured from floor to top of the screen.

**Results:** Surgeon eye height was measured for STA (61.5-71in), PER (55-65in), and SEA (43.5-52) positions. The minimum distance between the floor and the top of the monitor (min) and the vertical mobility range of the monitor (VR) were measured throughout a tertiary medical center including towers with boom arms (TcB) (min:63in, VR:11.5in), towers without booms (TsB) (min:71.8in, VR:1in), ceiling mounted booms (CMB) (min:52.6in, VR:41.1in), and slave monitors (SM) (min:68.2in, VR:1.5in). ANOVA with LSD post hoc testing identified all minimum distances and vertical ranges to be statistically different ( $p<0.001$ ) excluding the vertical range of SM and TsB. The shortest eye to floor distance able to be accommodated by each system includes 52.5in for TcB, 61.3in for TsB, 42.1in for CMB, and 57.7in for SM.

**Conclusions:** Monitor vertical displacement ranged greatly between styles of carts. Most surgical monitors can accommodate standing surgeons. TcB permit lowering of a monitor to accommodate most perched surgeons. CMB are the only system available that can ergonomically accommodate a seated surgeon.

Poster #095

### Targeting ARNO-Arf6 to Stabilize Barrier Dysfunction in Chronic Rhinosinusitis

Nyall London, MD, PhD  
Michelle Mendiola, BA  
Gina Paris, BA  
Tatyana Pozharskaya, BA  
Dean Li, MD, PhD  
Andrew Lane, MD  
Baltimore, MD  
USA

**Introduction:** Chronic rhinosinusitis (CRS) is characterized by elevated cytokine levels, inflammation, and vascular permeability in the sinus mucosa. Dysfunction of cell-cell adhesion in the mucosal barrier is postulated to play a role in CRS pathogenesis. The ARNO-Arf6 pathway has recently been shown to regulate endocytosis and removal of adhesion molecules from the cell surface. In this study, ARNO and Arf6 expression were investigated in human sinonasal tissue, and the pathway was pharmacologically inhibited in a mouse model to determine whether barrier stabilization could reduce inflammation.

**Methods:** Human sinonasal tissue sections and cultured human sinonasal epithelial cells were analyzed for ARNO and Arf6 expression by immunofluorescence. OVA-sensitized mice that were challenged intranasally for two weeks were treated with either systemic SecinH3 or dexamethasone for an additional six weeks. Murine sinonasal tissue was analyzed histologically, and nasal lavage samples were assayed for eotaxin-1

**Results:** Both ARNO and Arf6 were expressed in the cytoplasm of the sinonasal barrier as assessed by immunofluorescence. Treatment with SecinH3 reduced histologic parameters of inflammation as well as lavage eotaxin-1 levels to a degree comparable to dexamethasone in the OVA model of CRS.

**Conclusions:** These data demonstrate that the ARNO-Arf6 pathway is present in the human sinonasal barrier. Inhibition of this pathway in a mouse allergen sensitization model suggests that barrier stabilization can markedly reduce indices of chronic sinonasal inflammation. Further studies are necessary to demonstrate mechanistic relationships between barrier function and mucosal inflammation. Pharmacologic targeting of barrier dysfunction has potential as a novel therapeutic approach in CRS.

Poster #096

### The Effect of Blood Pressure and Cardiac Output on the Quality of the Surgical Field and Middle Cerebral Artery Blood Flow During Endoscopic Sinus Surgery

Thanh Ha, MBBS  
Robert van Renen, MBBCh,FFA(SA),FRCA  
Guy Ludbrook, PhD, MBBS, FANZCA  
Peter Wormald, MD,FRACS,FRCS,MBChB  
Adelaide, South Australia  
Australia

**Introduction:** Endoscopic sinus surgery (ESS) relies upon a clear surgical field in order to achieve safe and efficient outcomes. Hypotensive anesthesia is often used to optimize the surgical field, however evidence regarding its safety and efficacy are conflicting. Cardiac output (CO) monitoring has been impractical in the non-critical setting until recently. The aims of this study were to evaluate the effect of blood pressure (BP) and CO on intraoperative bleeding and middle cerebral artery blood flow velocity (Vmca) during ESS.

**Methods:** Patients undergoing symmetrical ESS for chronic rhinosinusitis at a tertiary institution during March-April 2013 were recruited. Patients were randomized to receive BP manipulation to either their left or right sinuses using noradrenaline. Simultaneous Transcranial Doppler ultrasonography and bleeding assessment scores (BAS) were conducted at regular intervals, then time-matched with invasive BP and minimally-invasive CO measurements.

**Results:** Eight patients participated in the study, yielding a total of 105 time-points across a 32-116mmHg MAP range. Bland and Altman methods demonstrated significant correlations between MAP and CO with Vmca; and moderate correlations between MAP and CO with BAS ( $r=0.5$  and  $r=0.42$  respectively,  $p<0.0001$ ). The greatest effect on BAS was seen at MAPs of 40-59mmHg and the greatest effect on Vmca was seen at MAPs below 60mmHg.

**Conclusions:** Hypotensive anesthesia is an effective method of controlling intraoperative bleeding during ESS, however very low pressures should be applied judiciously. In otherwise healthy patients undergoing ESS under general anesthesia, inducing MAP below 60mmHg improves the surgical field but may increase the risk of cerebral ischemia.

## POSTERS

Poster #097

**The Novel Use of an Ultrasonic Aspirator in Endoscopic Frontal Sinusotomy**

Sean Bury, MD  
Jay Diamond, MD  
Ameet Singh, MD  
Washington, DC  
USA

**Introduction:** Endoscopic frontal sinus surgery often requires extensive bony dissection. Traditionally, a variety of high speed drills have been used for this purpose. Disadvantages of these devices include potential thermal and mechanical damage to surrounding tissues and structures. A recently introduced ultrasonic aspirator has been used in Otolaryngology for efficient bone removal. We describe the novel use of the Sonopet Ultrasonic Aspirator for extended endoscopic frontal sinusotomies.

**Methods:** A prospective study of patients undergoing primary or secondary extended frontal sinus surgery with an ultrasonic aspirator was performed. Patient demographics, range of pathologies, operative technique, and intra-operative and post-operative complications were evaluated.

**Results:** Nine patients underwent extended frontal sinusotomies with the ultrasonic aspirator from 2010 to 2014. Seven patients were treated with a Draf III (Lothrop) approach; two patients were treated with a unilateral or bilateral Draf IIb approach. Pathologies included benign and malignant pathologies. There were no intra-operative or post-operative complications related to the ultrasonic aspirator use for extended sinusotomies. Patency of all frontal sinusotomies was maintained during the follow-up period. One patient required a minor revision.

**Conclusion:** The ultrasonic aspirator device may be used as an acceptable successful alternative to high speed drills for extended frontal sinusotomies. Challenges include limited maneuverability and minimal tip angulation as well as cost concerns. Instrument design changes will be needed for widespread acceptance of this ultrasonic aspirator for extended frontal sinus surgery

Poster #098

**The Use of 3-Dimensional Image Reconstruction for Pre-Operative Planning of Skull Base Defects**

Eugene Chang, MD  
Iowa City, IA  
USA

**Background:** The sensitivity and specificity of detecting anterior skull base defects by 2-D CT scan has increased with the use of high-resolution spiral CT scanning. One disadvantage of conventional triplanar imaging is that the surgeon must conceptualize these images in 3-dimensions. Additionally, superimposed soft tissue structures may obscure visualization of bony defects of the skull base. The use of segmented 3-D CT modeling may potentially address these concerns.

**Objective:** To investigate if a 3-dimensional (3-D) computed tomography (CT) model could efficiently and accurately detect the size and location of anterior skull base defects while providing advantages over the standard 2-dimensional (2-D) triplanar CT.

**Methods:** Four patients who had undergone endoscopic repair of anterior skull base defects secondary to meningoencephalocele between 2010 and 2013 were selected. A neuroradiologist identified and measured the skull base defects from 2-D triplanar CT images. A 3-D CT model was created and compared to the 2-D CT findings.

**Results:** Our 3-D CT model accurately detected the size and location of skull base defects. Advantages of our model include visualization of skull base defects from multiple angles as well as the ability to digitally subtract superimposed soft-tissue structures.

**Conclusions:** 3-D CT modeling allows a unique perspective to the skull base surgeon. This technique shifts the burden of 3-D image conceptualization from the clinician to the computer. After initial training in the software and segmentation, these images can be produced efficiently and portably. This model may assist in the preoperative analysis of skull base defects.

Poster #099

**The Use of Balloon Sinuplasty for Treatment of Recurrent Acute Sinusitis**

Irfan Syed, FRCS (ORL-HNS)  
Waseem Ahmed, MRCS  
Nikul Amin, MRCS  
Abbad Toma, FRCS (ORL-HNS)  
London,  
England

**Objectives:** Describe the role for balloon sinuplasty in the treatment of recurrent acute sinusitis in a large tertiary rhinology centre.

**Methods:** Retrospective case note review of all balloon sinuplasty cases from St George's Hospital London. Assessment of notes included identification of symptom improvement, discharge from care and the need for more invasive surgical management/medical therapy. Pre and post surgical SNOT-22 questionnaires were also completed by a cohort of the patients.

**Results:** 101 balloon sinuplasty cases were identified and assessed. Preliminary sub-analysis of cases of balloon sinuplasty for acute recurrent sinusitis suggests there was a significant reduction in the incidence and severity of sinusitis symptoms following the surgery as evidenced by successful discharge from secondary care and SNOT-22 score.

**Conclusions:** The exact role for balloon sinuplasty as either an office procedure or minimally invasive endoscopic sinus surgery technique is still under debate in the UK. In our tertiary centre with one of the largest series of balloon sinuplasty cases in the UK we have found that there is a role for the use of balloon sinuplasty in the treatment of recurrent acute sinusitis in selected cases

Poster #100

**The Utility of the Sino-Nasal Outcome Test (SNOT) as a Treatment Outcome Measure in Non-Sinugenic Facial Pain Syndrome**

Samuel Leong, FRCS MPhil  
Hoo Tsang, FRCA  
Gyorgy Banhegyi, FRCS  
Liverpool, Merseyside  
United Kingdom

**Introduction:** The purpose of this study was to assess the strength of correlation between the Sino-Nasal Outcome Test (SNOT) subdomains to determine which bore the greatest disease burden so that it could be used as a suitable measure of clinical response.

**Methods:** Prospective clinical audit of patients attending the Liverpool Multi-Disciplinary Facial Pain Clinic. The Brief Pain Inventory-Facial (BPI-F) was used as a comparator and surrogate measure of quality of life.

**Results:** Fifty patients (38 females) were reviewed, of whom 66% had midfacial segment pain. The average total SNOT score of the cohort was 53.1 (Standard Deviation (SD) 23.4), whilst the average subdomain scores were as follows: rhinologic symptoms (mean 8.5, SD 7.0), ear-facial symptoms (mean 10.1, SD 5.3), sleep function (mean 8.7, SD 5.4) and psychological issues (mean 16.3, SD 8.9). The total SNOT score was highly correlated to the BPI-F. Both the sleep function and psychological issues were the most highly correlated SNOT subdomains to the BPI-F, followed by ear-facial symptoms. The rhinologic symptom subdomain had a weak with the BPI-F. The total SNOT score was most significantly correlated with the sleep function and psychological issues subdomains.

**Conclusion:** This study supports the utility of the SNOT questionnaire as a measure of clinical outcome for non-sinugenic facial pain. The total SNOT score is highly correlated to the BPI-F, which has been used as surrogate measure of quality of life. In addition, the sleep function and psychological issues subdomains are suitable variables to measure response to treatment.

## POSTERS

Poster #101

**Therapeutic Interventions Following Endoscopic Sinus Surgery with a Steroid-Eluting Sinus Implant: Characterization and Cost-Analysis**

Angela Donaldson, MD  
 Luke Donatelli, MD  
 Thomas Heineman, BA  
 Vijay Anand, MD  
 New York, NY  
 USA

**Objectives:** The aim of this study is to perform a cost analysis of medical and surgical intervention following endoscopic sinus surgery (ESS) among patients who received the Propel stent versus those who did not.

**Study Design:** Retrospective review

**Setting:** Single surgeon rhinology practice

**Subject and Methods:** A review of medical charts was performed on patients who underwent ESS between January 2012 and August 2013. Patients were grouped based on placement of the stent (S) or not (C). Charts were reviewed for medical and surgical interventions following surgery. The non-stent group was considered the control.

**Results:** Ten patients (7.8%) required surgical intervention, including lysis of adhesions, revision ethmoidectomy, and/or balloon dilations (C=7, S=3). Twelve adhesion lysis procedures (C=8, S=4), 5 ethmoidectomy revisions (C=2, S=3), and 5 sinus balloon dilations (C=4, S=1) were performed. The estimated total surgical revision costs in the stent group was \$10,528 compared to \$17,971 in the control.

Of these 10 patients, 4 patients were started on nasal steroids (C=2, S=2), with 4 patients requiring both oral and nasal steroids (C=3, S=1). Three patients were started on antibiotics (C=3, S=0). The estimated cost of medical intervention in the stent group was \$1,613 compared to \$1,710 in the control group.

The average number of postoperative patient visits in those patients requiring intervention was 6.3, compared to 4.1 in those that did not.

**Conclusions:** The Propel stent, despite a larger up-front cost of the implant, may reduce treatment costs overall with decreased rates of post-ESS surgical and medical interventions.

Poster #102

**Treatment Carryover Effect of Office-Based Sclerotherapy for Epistaxis Due to Hereditary Hemorrhagic Telangiectasia**

**Anna Berglund, Medical Student**  
 Holly Boyer, MD  
 Minneapolis, MN  
 USA

**Outcome objectives:** Previous studies have demonstrated that office-based sclerotherapy using sodium tetradecyl sulfate (STS) is a safe and well-tolerated treatment option for recurrent epistaxis due to hereditary hemorrhagic telangiectasia (HHT). The objective of this study was to determine whether or not STS sclerotherapy exhibits carryover effect as measured by increasing time between consecutive sclerotherapy treatments.

**Methods:** A retrospective chart review was performed on 44 adult patients who were treated with STS sclerotherapy for recurrent epistaxis due to HHT between 3/27/08 and 5/15/14. The primary outcome measured was number of weeks between treatment sessions. Secondary endpoints included number of lesions treated and dose of sclerosant administered.

**Results:** Adequate data was found on 28 patients for analysis of time intervals between consecutive sclerotherapy treatments. Twenty patients (71%) demonstrated a trend toward increasing time between treatments as well as a shorter time interval between their first and second treatment than that preceding their last treatment. A trend toward decreasing time between treatments was seen in 7 patients (25%), while 1 patient (4%) demonstrated no change in treatment intervals. The number of lesions treated and the dose of sclerosant administered during each sclerotherapy procedure did not appear to influence the time interval between treatments.

**Conclusion:** Despite significant variation in treatment intervals both between subjects and within individual patients, there is an overall trend toward an increased number of weeks between consecutive sclerotherapy treatments. This observation suggests that STS sclerotherapy may exhibit carryover effect in patients being treated for recurrent epistaxis due to HHT.

Poster #103

**Treatment outcomes of midfacial segment pain: Experience from the Liverpool (United Kingdom) Multi-Disciplinary Team Facial Pain Clinic.**

Samuel Leong, FRCS MPhil  
Lepa Lazarova, MRCS  
Hoo Tsang, FRCA  
Gyorgy Banhegyi, FRCS  
Liverpool, Merseyside  
United Kingdom

**Objectives:** Midfacial segment pain (MSP) has the characteristics of tension-type headache which is confined to the midface corresponding to the second division of the trigeminal nerve. This review presents treatment outcomes of MSP patients managed at the Multi-disciplinary Team (MDT) Facial Pain Clinic in Liverpool.

**Design:** Prospective clinical outcome.

**Setting:** Tertiary referral centre for complex facial pain syndromes.

**Main outcome measures:** Sino-Nasal Outcome Test (SNOT). Clinical "success" was defined as an improvement in total SNOT score of >9 points and a reduction of the ear-face symptoms sub-domain score by =50% from baseline.

**Results:** The average age of this cohort (N = 20) was 49 years (median 50, range 25 - 70), with an average follow-up of 12 months (median 11 months, range 3 - 33). The overall pre-treatment total SNOT-22 score was 59.5 (standard deviation (SD) 20.7) which improved significantly ( $p < 0.05$ ) to 42 (SD 26.6) at latest follow-up. Although the average scores of all sub-domains improved, only the ear-facial symptoms and psychological issues sub-domains achieved statistical significance. When the criterion for success was applied, nine (45%) patients fulfilled this definition at an average of 12 months (SD 7.5) follow-up. The baseline total SNOT score in this cohort improved from 60.6 (SD 19.9) to 19.7 (SD 13.4). Half of these patients achieved success within 18 months of commencing treatment and the probability of attaining success at long-term follow-up was high

**Conclusions:** Treatment of midfacial segment facial pain is complex and requires follow-up to achieve any meaningful clinical outcome.

Poster #104

**Treatment Strategies in Hereditary Hemorrhagic Telangiectasia**

Valerie Lund, MD MS CBE  
Joanne Rimmer, MD  
London,  
UK

**Introduction:** Epistaxis in hereditary hemorrhagic telangiectasia (HHT) can be challenging to manage. A treatment strategy is required to provide optimum control of severity and frequency.

**Method:** Data on a cohort of HHT patients with epistaxis of varying severity have been prospectively collected. All fulfilled the Curacao diagnostic criteria and an analysis of treatment strategies was undertaken using validated outcome measures.

**Results.** There were 430 patients, 214 men and 216 women. Follow-up ranged from 6-380 months (mean 98 months). Three hundred (70%) have undergone KTP (or argon) laser between 1 and 18 times and 103 (24%) have had septodermoplasty (bilateral in 30%). Hormone modulation was undertaken with high dose oral oestrogen (8), medoxyprogesterone (15) and tamoxifen (60). These strategies reduced bleeding and significantly improved quality of life (QoL). Eighty (19%) of the most severe cases have undergone nasal closure, bilateral in 65, which was staged in 5. Eight have required revision with primary closure or nasolabial flaps. Complete closure was achieved in 62/65 (95%) and was associated with complete cessation of nasal bleeding in 60/62 (97%) and greatest QoL improvement.

**Conclusions:** Patients may receive several different treatments during the course of their disease, dependant on an algorithm based on severity of bleeding and the need for blood transfusions. Whilst most treatments reduce severity and frequency of bleeding, nasal closure may be anticipated to stop epistaxis completely and is therefore associated with the greatest improvement in clinical parameters and quality of life.



## POSTERS

Poster #105

**Unusual Complications Of Anti-TNF Therapy In CRS Patients: An Emerging Disease Entity?**

Badr Ibrahim, MD  
 Saud Alromaih, MD  
 Martin Desrosiers, MD  
 Montreal, QC  
 Canada

**Introduction:** Members of the anti-TNF alpha drug classes have demonstrated efficacy in a number of inflammatory conditions but may be accompanied by a number of serious adverse effects secondary to immunosuppression, their mechanism of action. Over the past year, we have encountered five cases of CRS patients treated with anti TNF agents for an underlying systemic disease presenting with unusual complications of CRS.

**Objectives:** We wished to describe our experience in the management of patients with CRS concomitantly managed with anti-TNF agents in order to inform other rhinologists of possible complications related to these therapies and therapeutic implications for management.

**Method:** Five patients with complicated CRS under treatment with anti-TNF-alpha agents were seen in a tertiary outpatient setting. Complications are described for each case.

**Results:** Patients with CRS and TNF-alpha agents presented 1) silent dental abscesses producing unilateral pansinusitis (two cases) 2) Failed surgery for oro-antral fistula (one case) 3) abnormal serum biochemistry (Total serum IgE 19, 200 IU/ml (one case) and serum eosinophilia 52% with pericarditis and asthma exacerbation (one case)).

**Conclusions:** Patients under therapy with anti-TNF alpha agents may present with unusual courses of CRS, principally secondary to asymptomatic dental complications or unexpected immunologic disorders. These may manifest as silent dental abscesses, unusual biochemical values, and failure to heal following therapy. As symptomatology may be atypical, assessment of these patients must be thorough, with appropriate imaging and biochemical testing. Anti-TNF therapy might have to be paused during exacerbations or following surgery to ensure optimal outcomes.

Poster #106

**Update: Algorithm for Reconstruction of Pituitary and Skull Base Defects**

Angela Donaldson, MD  
 Theodore Schwartz, MD  
 Vijay Anand, MD  
 New York, NY  
 USA

**Objectives:** We have previously described a reconstructive algorithm for skull base defects after endoscopic resection. The aim of this study is to evaluate the complication rates after modifications to our reconstructive protocol.

**Setting:** Tertiary academic center

**Study Design:** Retrospective review of a prospectively collected database

**Study Methods:** Chart review of patients who underwent endonasal endoscopic resection of skull base tumors between 2008 and 2013. Demographics, reconstructive materials and technique, and operative cerebrospinal fluid (CSF) leak rates were reviewed. An algorithm was constructed for sellar, suprasellar, and extended approaches. A previously published CSF leak grading system was used to categorize reconstructive techniques and assess CSF leak rates.

**Results:** There was a total of 383 patients in this series, 250 of which had a documented intra-operative leak. Ninety-three patients were reconstructed based on our updated algorithm, with a 98% success rate. A total of 9 post-operative leaks, two of which occurred using our current algorithm, were noted. The algorithm was divided into those with Grade 0 (no leak), Grade 1/2 (weeping CSF, small tears in the arachnoid, and moderate diaphragmatic defects), and Grade 3 (intradural, suprasellar, and anterior cranial fossa defects) leaks. Grade 0 and 3 CSF leaks had a 0% post-operative leak rate based on our algorithm. 2/21 of patients with a Grade 2 intra-operative CSF leak had a post-operative leak.

**Conclusion:** The algorithm for reconstruction after endoscopic surgery presented in this study is associated with excellent success rate.

Poster #107

### **Use of CT to Confirm a Diagnosis of Chronic Sinusitis in the Primary Care Setting**

Sarah Novis, MD  
Sarah Akkina, BS  
Shana Lynn, BS  
Hayley Kern, BS  
Matthew Davis, MD, MAPP  
Melissa Pynnonen, MD, MSc  
Ann Arbor, MI  
USA

**Introduction:** Chronic sinusitis is a common diagnosis in the primary care population. The diagnosis of chronic sinusitis is complex, and the American Academy of Otolaryngology Clinical Practice Guideline requires both the presence of symptoms for 90 days and confirmation of inflammation on CT or with endoscopy. We hypothesized that CT to confirm the diagnosis is not utilized appropriately in this setting.

**Methods:** A retrospective cohort of adults diagnosed with chronic sinusitis (ICD-9 code 473.X) during a two year period was created. This cohort was limited to primary care clinic or the emergency department visits. Patients with concurrent diagnosis of pharyngitis, otitis media, acute tonsillitis, bronchitis or strep throat were excluded to minimize confounding.

**Results:** There were 114 patients diagnosed with chronic sinusitis during the study period. 26 of these patients (22.8%) of these patients underwent CT scan performed within 90 days of initial diagnosis. Presence of nasal drainage, facial pressure, migraine headaches, and diabetes were predictive of patients undergoing CT on bivariate analysis ( $p < 0.05$ ). Of the patients undergoing CT scanning, 19 (73.1%) had radiographic evidence of sinusitis per report. This was classified as mild in 11 (57.9% of cases) and moderate in 8 (42.1%). 53.9% were seen by a primary care provider within 14 days of CT, and 11.5% were seen by an otolaryngologist within 180 days of initial diagnosis.

**Conclusion:** CT to confirm a diagnosis of chronic sinusitis is underutilized in the primary care setting. Interpretation of findings and appropriate referrals are missed in this setting.

Poster #108

### **Use of the Enterprise Data Warehouse to Understand Chronic Rhinosinusitis**

Rakesh Chandra, MD  
Amy Blood, MS2  
Stephanie Smith, MD  
Bruce Tan, MD  
David Conley, MD  
Robert Kern, MD  
Nashville, TN  
USA

**Background:** The enterprise data warehouse has permitted large hospitals and healthcare systems to consolidate medical record entries. Analysis of such a database can help to profile patients with a particular disease process with regard to demographics and comorbidities. We applied this analysis to chronic rhinosinusitis in a large patient population.

**Methods:** CPT coding was utilized to extract records from patients with chronic rhinosinusitis with nasal polyposis (CRSwNP;  $n=2320$ ), chronic rhinosinusitis without nasal polyposis (CRSSNP;  $n=27659$ ), and those without chronic sinusitis (noCRS;  $n=230456$ ) presenting over a five-year period. Demographics and comorbidities were compared amongst these groups.

**Results:** CRSwNP patients were significantly older than CRSSNP (50 v. 45yo), and a greater proportion of those with CRSwNP were male (56% v. 38%). Odds ratios were greater in CRSwNP than CRSSNP for manifesting asthma (4.4 v. 1.4) or allergic rhinitis (5.8 v. 2.9). Odds ratio for comorbid laryngopharyngeal reflux disease was also significantly greater in CRSwNP patients (8.5 v. 3.3 in CRSSNP). Interestingly, the prevalence of smoking and diabetes were both lower in each of the CRS groups then in those without CRS.

**Conclusions:** Enterprise data warehouse analysis reveals internal measures of validity in the data set and also elucidates novel observations regarding comorbid conditions.

## POSTERS

Poster #109

**Using Computational Fluid Dynamics to Optimize Targeted Intranasal Drug Delivery**

Stanley McClurg, MD  
 Charles Ebert, MD  
 Adam Zanation, MD  
 Brent Senior, MD  
 Julia Kimbell, PhD  
 Chapel Hill, North Carolina  
 USA

**Introduction:** Intranasal drug delivery is used with varying success. Possible reasons for failure are suboptimal positioning of the spray nozzle in the nose, and suboptimal released particle sizes. Nozzle position is known to affect spray deposition, but to date there are very few studies that have explored nozzle position systematically to optimize drug delivery from nasal sprays. Computational fluid dynamics (CFD) can be used to estimate “sweet spots” for particle release that maximize drug delivery to target areas within the nasal cavities. When combined with optimal particle size distributions (OPSD), significant increases in deposition to various target areas may potentially be achieved.

**Methods:** CT imaging was obtained for a total of 5 post-operative sinus cavities. CFD analysis was then used to estimate sweet spots for maximization of intranasal spray delivery to the maxillary sinus (MS), as well as the OPSD for the MS.

**Results:** The 5 sinus cavities were predicted to each have very different sweet spot locations for optimal MS drug deposition. In one sinus, the OPSD was estimated to be 5-35  $\mu\text{m}$  and maximal simulated MS deposition increased 7-fold from 0.03% to 0.22% of the total spray volume when optimally located, and when the OPSD was utilized.

**Conclusions:** This preliminary study suggests that the optimal release point of intranasal sprays may be highly variable between sinus cavities, and that nasal spray particle delivery could potentially be improved when the nozzle is located at the sweet spot, with additional benefit derived from OPSDs.

Poster #110

**Vitamin D Deficiency Does Not Influence Reported Fatigue Severity in Patients With Chronic Rhinosinusitis**

Eugene Sansoni, MD  
 Timothy Smith, MD,MPH  
 Jess Mace, MPH,CCRP  
 Jennifer Mulligan, PhD  
 Rodney Schlosser, MD  
 Nathan Sautter, MD  
 Portland, OR  
 USA

**Objective:** Fatigue and sleep dysfunction are frequently associated with chronic sinusitis (CRS) and significantly impact perception of disease severity. Vitamin D (VD3) deficiency has been linked to certain CRS subtypes and is associated with worse fatigue scores in other disease processes. The association between VD3 levels and patient-reported fatigue in CRS is unknown.

**Methods:** CRS patients meeting 2007 Adult Sinusitis Guidelines criteria choosing surgical management were prospectively enrolled from Oregon Health & Science University (OHSU) and Medical University of South Carolina (MUSC) between January 2012 and December 2013. Pre-operatively, each patient completed the Pittsburgh Sleep Quality Index (PSQI), and two CRS-specific quality of life (QOL) instruments which include fatigue questions: the Rhinosinusitis Disability index (RSDI) and Sino-Nasal Outcomes Test (SNOT-22). Blood was drawn during surgery and plasma 25-hydroxyvitamin-D (25-VD3) was measured by enzyme-linked immunosorbent assay. 25-VD3 sufficiency was defined as  $>30\text{ng/mL}$  and deficiency as  $\leq 20\text{ng/mL}$ .

**Results:** 98 patients were enrolled from MUSC ( $n=51$ ) and OHSU ( $n=47$ ) with mean 25-VD3 levels of 31.6 and 28.5, respectively ( $p=0.176$ ). 60.2% of subjects demonstrated VD3 insufficiency or deficiency. 12 patients reported history of obstructive sleep apnea, including 7 with confirmed diagnosis following polysomnogram. No significant associations between 25-VD3 levels and PSQI scores, RSDI or SNOT-22 fatigue scores were demonstrated even after accounting for polyp status or enrollment site.

**Conclusions:** There is no association between 25-VD3 insufficiency/deficiency and level of reported fatigue in CRS patients undergoing sinus surgery. Given the high prevalence of 25-VD3 insufficiency in CRS, routine testing of CRS patients should be considered.







# 2015

## SAVE THE DATE



### The ARS at COSM 2015

April 23-24, 2015

Hynes Convention Center  
Sheraton Boston  
Boston, MA

Abstract Deadline: 1/16/15  
Manuscript Deadline: 3/27/15



### 4th Annual Summer Sinus Symposium

July 16-18, 2015

Westin Michigan Avenue  
Chicago, IL



### The ARS at AAO 61<sup>st</sup> Annual Meeting

September 26, 2015

Sheraton Dallas Hotel  
Dallas, TX

Abstract Deadline: 6/5/15  
Manuscript Deadline: 8/28/15

[www.american-rhinologic.org/meetings](http://www.american-rhinologic.org/meetings)

**JOIN US! ARS MEMBERSHIP BENEFITS:** Membership in the ARS places you in a highly respected professional organization that has a significant and far-reaching impact on the subspecialty of Rhinology. The ARS is dedicated to promoting excellence in clinical care, investigation, education, and patient advocacy in the field of rhinology. Membership benefits include: Professional camaraderie, Educational and research benefits, Advocacy in socioeconomic issues for your rhinology practice, Subscription to the *International Forum of Allergy & Rhinology*, the official publication of the ARS, Discounted registration fees for the annual Fall and Spring meetings, A subscription to the ARS newsletter, Access to the "Members only" sections of the ARS website. See more at: <http://www.american-rhinologic.org/membership>