



2013 **cosm**

PROGRAM & ABSTRACTS

April 12-13, 2013

JW Marriott Grande Lakes, Orlando, FL

www.american-rhinologic.org

SAVE THE DATES

JULY 19-20, 2013
Chicago, IL
Westin Michigan Avenue

2013 ARS SUMMER SINUS SYMPOSIUM

Please plan to join us in Chicago July 19-20, 2013 at the Westin Michigan Avenue hotel.

Complete program details, including hotel and registration to follow. Please visit the ARS website at www.american-rhinologic.org for more information.



The inaugural symposium, held in Chicago July 13-14, 2012, was a huge success! Over 300 attendees from 40 states including Otolaryngologists from around North America, both Community and University, met to discuss the pertinent issues that affect their practices. Attendees at this unprecedented ARS event witnessed cadaver dissections performed by Drs. David Kennedy and James Stankiewicz and attended sessions on Rhinology, Sleep Apnea, Reflux, Rhinoplasty, Skull Base Surgery, Practice Management, and applications of new technology such as balloon dilation.

The ARS Summer Sinus Symposium truly is a meeting for all Otolaryngologists who treat and manage nasal and sinus issues, from the office to the operating room. Don't miss your chance to attend in 2013!





Todd Kingdom, MD

Presidential Welcome to the ARS at COSM 2013

On behalf of the Board of Directors, it is my great honor and pleasure to welcome you to the American Rhinologic Society meeting at COSM in beautiful Orlando. Under the direction of Program Chairman, Tim Smith, MD, and his program committee, we once again hope to offer an exciting, valuable and enjoyable program. It is our sincere goal to provide program content that is broad and timely as we recognize the wide array of interests and needs amongst our membership. On display during this program will be unparalleled scientific research, clinically relevant panel discussions, and invited speakers sharing their experiences. It is my sincere goal to help the ARS become a society that appeals to all otolaryngologists with interest in the field of rhinology.

I continue to marvel at the generosity our corporate partners exhibit in support of our organization and its endeavors. It is only through these strong relationships that we are able to realize our lofty goals of excellence in education, training, research, and patient advocacy. On behalf of the entire Board of Directors, I am proud to say that these partnerships are stronger than ever with aligned strategic goals. Please join me in thanking our corporate partners by exploring the exhibits and visiting with them.

I believe this COSM will prove to be our finest yet as an organization. Please enjoy your time in Orlando and welcome to the ARS.

Todd T. Kingdom, MD
President, American Rhinologic Society



Timothy Smith, MD

Program Chair Welcome

Welcome to the ARS at COSM Orlando!

I would like to welcome you to the ARS at COSM Orlando 2013! The ARS is proud to provide this educational program to serve our members, all otolaryngologists, and allied health care providers from throughout the United States, North America, and the world.

At the ARS, we have worked very hard to arrange a program that has something for everyone. We've developed clinical debates, moderated panels that address the most pressing issues in our field, and a scientific program that is state-of-the-art, well rounded, and highly educational.

It is our sincere hope that there is "something outstanding" in this program for every attendee. Thank you for your continued support of the American Rhinologic Society. Please seek me out and provide me with your critical feedback about the program.

I'll see you at our corporate partners coffee break!

Tim L. Smith, MD, MPH
ARS President-Elect & Program Chair

P.S. If you think the ARS at COSM Program is great, wait until you see the program for the ARS at AAO-HNS September 28, 2013 in Vancouver, BC! Please save the date! Highlights include:

- Panel: *What is Happening in the World of Rhinology: An International Forum of Allergy & Rhinology*
- Panel: *An Insightful Discussion: In hindsight, I would have handled this differently. Lessons learned the hard way...*
- The 9th Annual Kennedy Lecture - Berrylin J. Ferguson, MD: *Twenty-five Years of Sinus Study: Learning and Unlearning*
- Showcasing ARS Research and *The International Forum of Allergy & Rhinology*
- ARS/AAOA Combined Panel: *Changing Your Practice: Strategies to Manage Your Patients with Recalcitrant Rhinosinusitis*
- Join your colleagues to discuss the latest advances in our field and discuss your challenging cases!
- Explore the exhibits of our *Industry Partners* where the latest technology is unveiled!

American Rhinologic Society Executives - 2013



Todd Kingdom, MD
President
University of Colorado
School of Medicine
12631 E. 17th Avenue, #B205
Aurora, CO 80045
Tel: 303-724-1960
Fax: 303-724-1961
Email: todd.kingdom@ucdenver.edu



Michael Setzen, MD
Immediate Past President
600 Northern Blvd., Suite 312
Great Neck, NY 11021
Tel: 516-829-0045
Fax: 516-829-0441
Email: msmdent@aol.com




Timothy Smith, MD
President Elect
Oregon Health & Science University
Oregon Sinus Center
3181 SW Sam Jackson
Park Rd PV- 01
Portland, OR 97239
Tel: 503-494-7413
Fax: 503-494-4631
Email: smithtim@ohsu.edu



James Palmer, MD
Secretary
University of Pennsylvania
Medical Center
5 Ravdin, Division of Rhinology
3400 Spruce Street
Philadelphia, PA 19104
Tel: 215-662-7746
Fax: 215-614-0071
Email: secretaryars@gmail.com



Joseph B. Jacobs, MD
Treasurer
NYU Medical Center
345 E. 37th Street #306
New York, NY 10016
Tel: 646-754-1202
Fax: 646-754-1222
Email: joseph.jacobs@nyumc.org



Roy Casiano, MD
First Vice President
University of Miami Hospitals
& Clinics
1120 NW 14th Street
5th floor, Clinical Research Bldg
Miami, FL 33136
Tel: 305-401-7088
Email: rcasiano@med.miami.edu



Peter Hwang, MD
Second Vice President
801 Welch Road
Stanford, CA 94305
Tel: 650-725-6500
Fax: 650-725-8502
Email: phwang@ohns.stanford.edu



Wendi Perez
Administrator
PO Box 495
Warwick, NY 10990
Tel: 845-988-1631
Fax: 845-986-1527
Email: wendi.perez@gmail.com

ARS Board of Directors



Pete Batra, MD



John DelGaudio, MD



Marc Dubin, MD



Joseph Han, MD



Robert Kern, MD



Rodney Schlosser, MD

Consultants to the Board




Parul Goyal, MD



Ralph Metson, MD



Michael Stewart, MD



Sarah Wise, MD


Chairs




Audit
Subinoy Das, MD



By-Laws
Douglas Reh, MD



Awards
David Poetker, MD



Business Development
Joseph Jacobs, MD



CME
Raj Sindwani, MD



Research Grants
Noam Cohen, MD



Education
Rick Chandra, MD



Ethics
Mark Zacharek, MD



Fellowship
Todd Kingdom, MD



Information Technology
Kevin Welch, MD



International Liaison
Nicolas Busaba, MD



Membership
Christopher Melroy, MD



Historian
Eugenia Vining, MD



Newsletter
Sarah Wise, MD



Patient Advocacy
Seth Brown, MD



Pediatric Rhinology
Hassan Ramadan, MD



Resident/Fellows
Bellachew Tessema, MD

Past Presidents

1954 - 1955	Maurice H. Cottle, MD*
1955 - 1956	Ralph H. Riggs, MD*
1956 - 1957	Walter E. E. Loch, MD*
1958 - 1959	Kenneth H. Hinderer, MD*
1959 - 1960	Roland M. Loring, MD*
1960 - 1961	Ivan W. Philpott, MD*
1962 - 1963	Raymond I. Hilsinger, MD*
1963 - 1964	H. Ashton Thomas, MD*
1964 - 1965	Carl B. Spath, MD
1966 - 1967	Walter J. Agesen, MD
1967 - 1968	Richard Hadley, MD*
1968 - 1969	Henry L. Williams, MD*
1970 - 1971	Charles A. Tucker, MD*
1971 - 1972	Pat A. Barelli, MD
1972 - 1973	Gerald F. Joseph, MD
1973 - 1974	Manuel R. Wexler, MD*
1974 - 1975	George H. Drumheiler, MD*
1975 - 1976	Joseph W. West, MD*
1976 - 1977	Albert Steiner, MD*
1977 - 1978	Anthony Failla, MD*
1978 - 1979	Clifford F. Lake, MD*
1979 - 1980	W. K. Locklin, MD
1981 - 1982	Eugene B. Kern, MD
1982 - 1983	Carlos G. Benavides, MD
1983 - 1984	Leon Neiman, MD
1984 - 1985	George C. Facer, MD
1985 - 1986	Larry E. Duberstein, MD
1986 - 1987	Glenn W. Drumheiler, DO
1987 - 1988	Alvin Katz, MD
1988 - 1989	Donald Leopold, MD
1990 - 1991	Pierre Arbour, MD
1991 - 1992	Fred Stucker, MD
1992 - 1993	David W. Kennedy, MD
1993 - 1994	Sanford R. Hoffman, MD
1994 - 1995	Richard J. Trevino, MD
1995 - 1996	Vijay K. Anand, MD
1996 - 1997	Dale H. Rice, MD
1997 - 1998	Michael S. Benninger, MD
1998 - 1999	William Panje, MD
1999 - 2000	Charles W. Gross, MD
2000 - 2001	Frederick A. Kuhn, MD
2001 - 2002	Paul Toffel, MD
2002 - 2003	Donald C. Lanza, MD
2003 - 2004	James A. Hadley, MD
2004 - 2005	Joseph B. Jacobs, MD
2005 - 2006	Michael J. Sillers, MD
2006 - 2007	Howard L. Levine, MD
2007 - 2008	Marvin P. Fried, MD
2008 - 2009	James Stankiewicz, MD
2009 - 2010	Stilianos Kountakis, MD
2010 - 2011	Brent A. Senior, MD
2011 - 2012	Michael Setzen, MD
2012 - 2013	Todd Kingdom, MD

*Deceased

Secretaries

2012 - present	James Palmer, MD
2009 - 2012	Peter Hwang, MD
2005 - 2008	Brent A. Senior, MD
1999 - 2005	Marvin P. Fried, MD
1995 - 1999	Frederick Stucker, MD
1990 - 1995	Frank Lucente, MD
1985 - 1990	George Facer, MD
1980 - 1985	Pat A. Barelli, MD
1975 - 1980	Glenn H. Drumhillier, MD
1970 - 1975	Ralph H. Riggs, MD

ARS Mission Statement

The American Rhinologic Society's mission is to serve, represent and advance the science and ethical practice of rhinology. The Society promotes excellence in patient care, research and education in Rhinology and Skull Base Disorders. The American Rhinologic Society is dedicated to providing communication and fellowship to the members of the Rhinologic community through on-going medical education, patient advocacy, and social programs. The ARS continuing medical education activities serve to improve professional competence, performance, and promote research.

Business/ACCME

Continuing Education

Accreditation Statement

The American Rhinologic Society is accredited by the Accreditation Council for Continuing Medical Education to provide continuing medical education for physicians.

Credit Designation Statement

The American Rhinologic Society designates this live activity for a maximum of 10.25 *AMA PRA Category 1 Credits™*. Physicians should claim only the credit commensurate with the extent of their participation in the activity.

Goals and Objectives

At the conclusion of this meeting participants will be able to:

1. Discuss the latest information on the medical management of patients with chronic rhinosinusitis and other rhinologic diseases including allergic rhinitis.
2. Gain an understanding of the indications, procedural nuances and potential complications of contemporary surgical techniques used in nasal, endoscopic sinus, and skull base surgery.
3. Demonstrate awareness of emerging research examining the pathophysiology of chronic rhinosinusitis and other rhinologic diseases.

Welcome New ARS Members!

September 2012 - February 2013

INTERNATIONAL MEMBERS

Julian Lee, MD, Singapore, Singapore

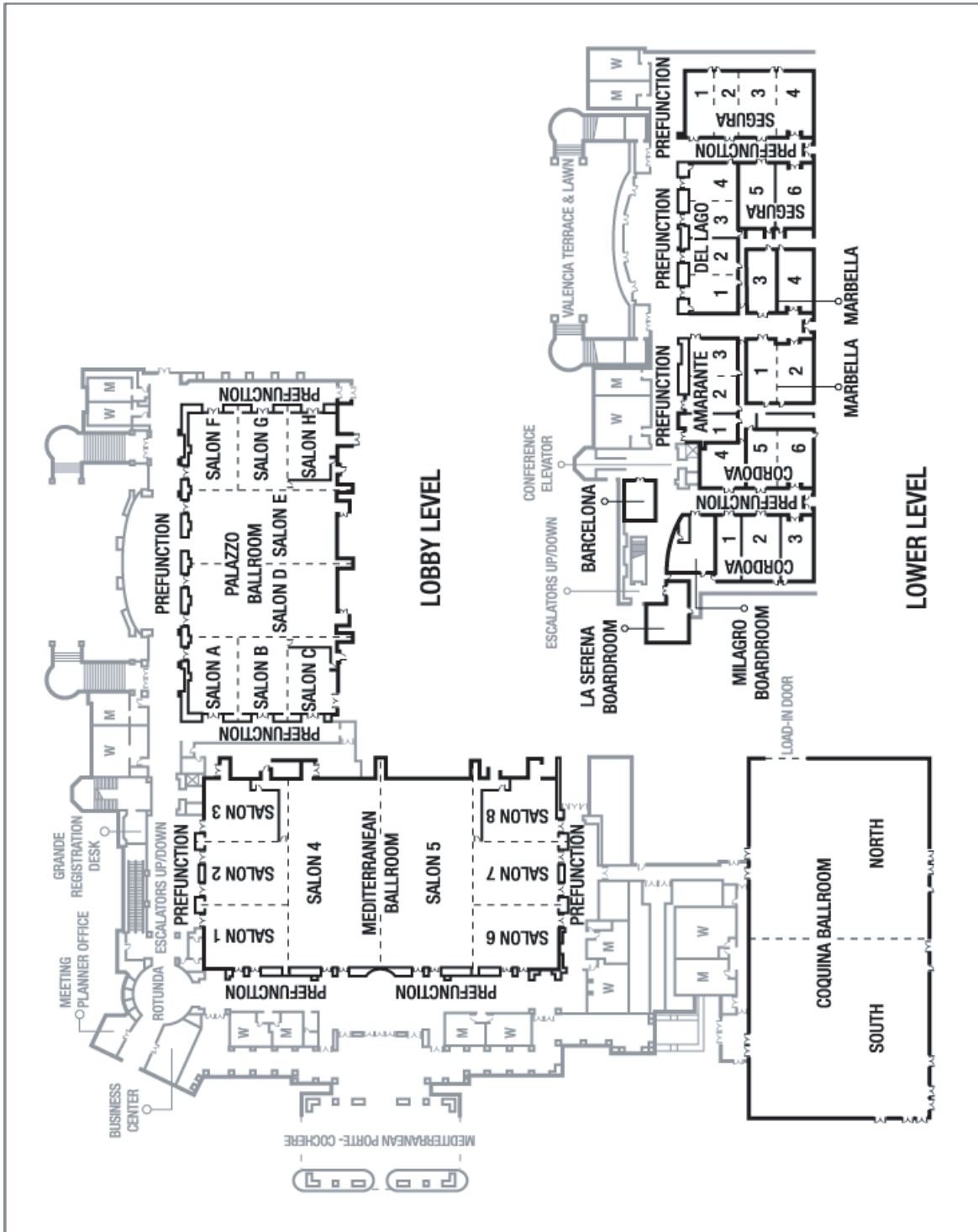
REGULAR MEMBERS

Ryan C. Case, MD, Brookhaven, MS
Sandra Ettema, MD, Galesburg, IL
Robert Mancuso, MD, Meza, AZ
Lee Mandel, MD, Hollywood, FL
Rae McIntee, MD, Quincy, IL
Samuel Pate, MD, Omaha, NE
Margaret J Provenza, MD, Rockford, IL
Jeremy Reed, MD, Harker Heights, Tx
Michael Rontal, MD, Bloomfield Hills, MI
Majd Roufail, MD, Doha, Qatar
Matthew S. Russell, MD, San Francisco, CA
Victor Scapa, MD, Kirkland, WA
Justin H. Turner, MD, Nashville, TN
Douglas Worden, MD, Flemington, NJ
Arthur W Wu, MD, Los Angeles, CA
Fazlur Zahurullah, MD, Rockford, IL
Adam M Zanation, MD, Chapel Hill, NC

RESIDENT MEMBERS

Yazeed Alghonaim, MD, Montreal, Quebec
Shawn Allen, MD, Memphis, TN
Jennifer Alyono, MD, Menlo Park, CA
Rachel Arffa, MD, Temple, TX
Mary Ashmead, MD, Jackson, MS
Christie Barnes, MD, South Burlington, VA
Mark Been, MD, Chicago, IL
Kevin Burke, MD, San Francisco, CA
Nadieska Caballero, MD, Park Ridge, IL
Nan Chen, MD, Columbia, MO
Adrienne Childers, MD, Richmond, VA
Matthew Clavenna, MD, Shreveport, LA
Adam S. DeConde, MD, Santa Monica, CA
Justin W. Douglas, MD, Morgantown, WV
Deepak Dugar, MD, Chapel Hill, NC
Megan Durr, MD, San Francisco, CA
Mohamed Hegazy, MD, Damietta, Domiat
Candace Hrelec, MD, Campbell, OH
Scott Hudson, MD, Salt Lake City, UT
Qasim Husain, BS, Fairlawn, NJ
Armon Jadidian, MD, Gainesville, FL
Adam Kimple, MD, Chapel Hill, NC
Joshua M. Levy, MD, New Orleans, LA
Victor Lin, MS, Fort Worth, TX
Jackie Matijasec, MD, Baton Rouge, LA
Wendy McConnell, MD, Saint Louis, MO
Rahul Mehta, MD, Baltimore, MD
Sarah Novis, MD, Ann Arbor, MI
James J. Owusu, MD, Minneapolis, MN
Charles Parker, MD, Cincinnati, OH
Alkis Psaltis, MD, Palo Alto, CA
Shoib Sana, DO, Detroit, MI
Joseph Schwartz, MD, Montreal, Quebec
Prateek Srinet, MD, New Haven, CT
Jacob Stelle, MD, Springfield, IL
Patrick Stevens, MD, Hartford, CT
Alexis Strohl, MD, Rochester, NY
Wade Swenson, MD, Minneapolis, MN
Timothy Wong, MD, Gainesville, FL
Edward Wu, MD, Diamond Bar, CA
William Yao, MD, Houston, TX

Floor Plan





COSM 2013 Friday PM Session *At-A-Glance*

1:00PM

Welcome

ARS President Todd Kingdom, MD
and President-Elect Timothy L. Smith, MD, MPH

1:05PM

Panel: Chronic Sinusitis from the Allergist/Immunologist Perspective: Immunotherapy, Steroids, ASA Desensitization, Immunomodulators, and what Allergists expect from our surgery!

Moderator: Robert Kern, MD

Panelists: *Larry Borish, MD; * Anju Tripathy Peters, MD *Member, American Academy of Allergy, Asthma, and Immunology

Session: Inflammation in Rhinosinusitis

Moderators: Devyani Lal, MD,
Eugene Chang, MD

1:50PM

IL-4 and IL-13 Compromise the Sinonasal Epithelial Barrier and Perturb Intercellular Junction Protein Expression

Sarah K. Wise, MD

1:57PM

P-glycoprotein is a Marker of Tissue Eosinophilia and Radiographic Inflammation in Chronic Rhinosinusitis without Nasal Polyps

Rachel E. Feldman, BA

2:04PM

The In-Vivo Effect of Leptospermum Honey on Cytokine Expression in CRS Patients

Jamil Manji, BSc.H

2:11PM

Differential Expression of VCAM and ICAM by Sinonasal Fibroblasts Among Control and Chronic Rhinosinusitis Patients

Samuel L. Oyer, MD

2:18PM

Discussion/ Q&A

Session: Topical Therapies and Delivery

Moderators: Karen Fong, MD, Luke Rudmik, MD

2:25PM

Budesonide Nasal Irrigations in the Management of Chronic Rhinosinusitis

David Jang, MD (Presented by Jamie Segel, MD)

2:32PM

Effect of High Dose Intranasal Steroids on Intraocular Pressure

Kristin Seiberling, MD (Presented by Justin McClarty, MD)

2:39PM

Effects of Intranasal Budesonide Delivered by Nasal Nebulizer on Symptoms and Objective Measures of Nasal Congestion in Perennial Allergic Rhinitis

Faud Baroody, MD

2:46PM

The Effect of Head Position on Distribution of Topical Medication using the Mucosal Atomization Device on the Paranasal Sinuses: A Cadaver Study

Al-Rahim Habib, BSc

2:53PM

Discussion/Q&A

3:00PM

Break with Industry Partners

3:25PM

Update on Etiology of CRS: Do Our Sinuses Crave Certain Bacteria for Health?

Invited Speaker: Andrew Goldberg, MD

Session: Rhinosinusitis: The Role of Bacteria

Moderators: Pete Manes, MD, Erin O'Brien, MD

3:50PM

Impact of Therapy on the CRS Sinus Microbiome

Cindy Liu, MD, MPH

3:57PM

The Impact of Culturable Bacterial Community on Histopathology in CRS

Darren Rom, MD

4:04PM

Comparing Sinus and Pulmonary Cultures in Patients with Bronchiectasis and Chronic Rhinosinusitis

Vijay Ramakrishnan, MD

4:11PM

Discussion/Q&A

4:18PM

Panel: Everyday Struggles in Our Practices-Expert Solutions!

Moderator: Donald Lanza, MD

Panelists: John DelGaudio, MD; Todd Kingdom, MD; Marc Dubin, MD; Stacey Gray, MD

5:00PM

Closing Remarks and Adjournment

*Timothy L. Smith, MD, MPH,
President-Elect and Program Chair*

COSM 2013 Saturday Session At-A-Glance

8:00AM

Welcome

*Timothy L. Smith, MD, MPH,
President-Elect and Program Chair*

8:05AM

Presidential Address

Todd Kingdom, MD

Session: Surgical Practices

Moderators: Greg Davis, MD, Zach Soler, MD

8:15AM

Office-Based Balloon Sinus Dilation: 52+ Week Follow-up of a Prospective Multicenter Study

Ashley Sikand, MD

8:22AM

Novel Vacuum-Powered Microdebrider for Office Polypectomy: A Case Series

Amin Javer, MD

8:29 AM

Nasal Surgery for Obstructive Sleep Apnea- A Role for Endoscopic Sinus Surgery?

Rohan Wijewickrama, MD

8:36AM

A Comparison of Septal Stapler to Suture Closure in Nasal Septoplasty: A Prospective, Randomized Trial Evaluating the Effect on Operative Time and Outcomes

Leigh Sowerby, MD

8:43AM

Discussion/Q&A

Session: Novel Research at the Cutting Edge

*Moderators: Vijay Ramakrishnan, MD,
Ameet Singh, MD*

8:50AM

Identification of Human Nasal Mucosal Epithelial Stem Cells

Mrinmoy Sanyal, PhD

8:57AM

Distribution of Human Nasal Mesenchymal Stem Cells

Bradley J. Goldstein, MD, PhD

9:04AM

Constitutive Expression of VEGF Gene Family Ligand and Receptors on Human Upper and Lower Airway Epithelial Cells

Jean Kim, MD, PhD

9:11AM

Anti-Inflammatory Mediators and Sleep Dysfunction in Chronic Rhinosinusitis

Jeremiah Alt, MD, PhD

9:18AM

Discussion/Q&A

9:25AM

Panel: Inferior Turbinate Reduction Surgery: Minimalist vs. Turbinator

Moderator: Pete Batra, MD

*Presenters: Roy Casiano, MD and
Martin Citardj, MD*

9:55AM
Break with Industry Partners

Session: Disease Manifestations and Treatment Outcomes

*Moderators: Ayesha Khalid, MD,
Abtin Tabaee, MD*

10:25AM
A Systematic Review and Meta-analysis of Asthma Outcomes Following Endoscopic Sinus Surgery for Chronic Rhinosinusitis
Rishi Vashishta, MD

10:32AM
Surgical Management of Chronic Rhinosinusitis in Cystic Fibrosis: A Systematic Review
Jonathan Liang, MD

10:39AM
Ostiomeatal Occlusion Does Not Correlate with Sinus Disease in Eosinophilic Rhinosinusitis*
Dr Kornkiat Snidvongs
**(PJ Wormald Research Award from Australasian Rhinologic Society)*

10:46AM
Discussion/Q&A

Session: Treatment Outcomes and Cost Effectiveness
*Moderators: Jean Anderson Eloy, MD,
Jamie Litvack, MD*

10:53AM
Impact of Continued Medical Therapy in Patients with Refractory Chronic Rhinosinusitis
Kristine A. Smith, MD

11:00AM
Impact of Symptom-Based Risk Stratification on the Cost Effective Diagnosis of Patients with Chronic Rhinosinusitis Symptoms
Bruce Tan, MD

11:07AM
Comparison of Outcomes of Endoscopic Ligation and Endovascular Treatment of Sphenopalatine Artery for Epistaxis: A Five-year Series from a Single Institution
Nirav Thakkar, MD

11:14AM
Discussion/Q&A

11:19AM
Panel: The Cutting Edge: From Lab Bench to Bedside - Improving Care for Our Patients

Moderator: Ralph Metson, MD
*Panelists: Bruce Tan, MD; Sarah Wise, MD;
Brad Woodworth, MD*

12:00PM
Lunch Break with Industry Partners

Session: Steroids in Chronic Rhinosinusitis
*Moderators: Steve Pletcher, MD,
Nathan Sautter, MD*

1:00PM
The Effect of Intranasal Fluticasone Propionate Irrigations on Salivary Cortisol, Intraocular Pressure, and Posterior Subcapsular Cataracts in Postsurgical Chronic Rhinosinusitis
Li-Xing Man, MPA, MD, MSc

1:07PM
When do the Risks of Repeated Courses of Corticosteroids Exceed the Risks of Surgery?
Randy Leung, MD

1:14PM
Systemic Prednisone Administration Selectively Alters Granulocyte Subsets in Nasal Polyps from AERD and CRS Patients
Justin Edward, MS

1:21PM
Chronic Rhinosinusitis with Nasal Polyps is Associated with Increased Nrf2 Mediated Antioxidant Gene Expression
Murugappan Ramanathan, MD

1:28PM
Discussion/Q&A

Session: Management of CSF Leaks and Olfaction
*Moderators: Nithin Adappa, MD,
Jonathan Liang, MD*

1:35PM
Acetazolamide for High Intracranial Pressure CSF Leaks
Mohamed R. Chaaban, MD

1:42PM

Porcine Small Intestine Submucosal Graft for Endoscopic Skull Base Reconstruction

Elisa Illing, MD

1:49PM

Interferon Gamma Causes Olfactory Dysfunction Without Concomitant Neuroepithelial Damage

Andrew Lane, MD

1:56PM

Discussion/Q&A

2:03PM

Panel: Evidence-based rhinology: How Has the Evidence Changed my Treatment of Sinonasal Disease?

*Moderator: Michael G. Stewart, MD, MPH
Panelists: Jack Krouse, MD; Brent Senior, MD; David Poetker, MD; Stephanie Joe, MD*

2:55PM

Break with Industry Partners

Session: Sinonasal and Skull Base Tumors

Moderators: Troy Woodard, MD and Adam Zanation, MD

3:25PM

Evolution in the Treatment of Sinonasal Inverted Papilloma: The Pedicle Oriented Endoscopic Surgery

Alessandro Pusateri, MD

3:32PM

p16, EGFR, CyclinD1, and p53 Staining Patterns for Inverted Papilloma

Giant Lin, MD

3:39PM

Quality of Life Metrics after Surgery for Sinonasal Neoplasms: Analysis of Predictive Factors

Nathan Deckard, MD

3:46PM

Sinonasal Quality of Life Outcomes after Minimally Invasive Resection of Sinonasal and Skull Base Tumors

Brian Harrow, MSII, BS

3:53PM

Discussion/Q&A

4:00PM

Rhinology 2013: What Does the Future Hold for Rhinology/Sinus Surgery?

Invited Speaker: David W. Kennedy, MD

Session: Clinical Practice Update: Is Your Practice Current?

Moderators: Naveen Bhandarkar, MD and Erin Wright, MD

4:25PM

A Systematic Review of Non-absorbable, Absorbable and Medicated Spacers Following Endoscopic Sinus Surgery

Xiao Zhao, MD

4:32PM

Systematic Review and Meta-analysis of Total Intravenous Anesthesia and Endoscopic Sinus Surgery

Adam DeConde, MD

4:39PM

The Impact of Neo-Osteogenesis on Disease Control in Chronic Rhinosinusitis after Primary Surgery

Peta-Lee Sacks, MS

4:46PM

Aspirin Desensitization for Samter's Triad Nasal Polyposis: A Systematic Review

Jason Xu, MSc

4:53PM

Discussion/Q&A

5:00PM

Closing Remarks & Meeting Adjourned -

President and President-Elect: Todd Kingdom, MD and Timothy L. Smith, MD, MPH





COSM 2013 Friday PM Session Program Details

Friday, April 12, 2013

JW Marriott Grande Lakes Orlando
Mediterranean 5

1:00PM

Welcome

ARS President Todd Kingdom, MD,
President-Elect Timothy L. Smith, MD, MPH

1:05PM

Panel: Chronic Sinusitis from the Allergist/Immunologist Perspective: Immunotherapy, Steroids, ASA Desensitization, Immunomodulators, and what Allergists expect from our surgery!

Moderator: Robert Kern, MD

Panelists: *Larry Borish, MD; * Anju Tripathy Peters, MD

*Member, American Academy of Allergy, Asthma, and Immunology

Session: Inflammation in Rhinosinusitis

Moderators: Devyani Lal, MD and Eugene Chang, MD

1:50PM

IL-4 and IL-13 Compromise the Sinonasal Epithelial Barrier and Perturb Intercellular Junction Protein Expression

Sarah Wise, MD, Adrienne Laury, MD, Elizabeth Katz, MD, Kyle Den Beste, BA Charles Parkos, MD, PhD, Asma Nusrat, MD Atlanta, GA USA

Introduction:

Altered expression of epithelial intercellular junction proteins have been observed in sinonasal biopsies from nasal polyps and epithelial layers cultured from AFRS patients. These alterations comprise a "leaky" epithelial barrier phenotype. We hypothesize that Th2 cytokines IL-4 and IL-13 modulate epithelial junction proteins thereby contributing to the leaky epithelial barrier.

Methods:

Differentiated, ciliated, primary sinonasal epithelial layers cultured at the air-liquid inter-

face were exposed to IL-4, IL-13, and controls for 24 hours at 37C. Epithelial resistance measurements were taken every 4 hours during cytokine exposure. Western blot and immunofluorescence staining/confocal microscopy were used to assess changes in a panel of tight and adherens junction proteins. Western blot densitometry was quantified with image analysis.

Results:

IL-4 and IL-13 exposure resulted in a mean decrease in transepithelial resistance at 24 hours to 51.6% (n=6) and 68.6% (n=8) of baseline, respectively. Tight junction protein JAM-A expression decreased 42.2% with IL-4 exposure (n=9) and 37.5% with IL-13 exposure (n=9). Adherens junction protein E-cadherin expression decreased 35.3% with IL-4 exposure (n=9) and 32.9% with IL-13 exposure (n=9). Tight junction protein claudin-2 increased 27.0% with IL-4 exposure (n=5) and 53.2% with IL-13 exposure (n=5). There were no appreciable changes in claudin-1, occludin, or ZO-1 with IL-4 or IL-13 exposure.

Conclusion:

Sinonasal epithelial exposure to Th2 cytokines IL-4 and IL-13 results in alterations in intercellular junction proteins JAM-A, claudin-2, and E-cadherin, reflecting increased epithelial permeability. Such changes may explain some of the phenotypic manifestations of Th2-mediated sinonasal disease, such as edema, nasal discharge, and environmental reactivity.

1:57PM

P-glycoprotein is a Marker of Tissue Eosinophilia and Radiographic Inflammation in Chronic Rhinosinusitis without Nasal Polyps

Rachel Feldman, BA, Allen Lam, MD, Peter Sadow, MD, PhD, Benjamin Bleier, MD, Boston, MA USA

Introduction:

P-glycoprotein(P-gp) is a membrane bound efflux pump which is upregulated in chronic rhinosinusitis with nasal polyps(CRSwNP) and participates in epithelial cytokine secretion. Eosinophilic Chronic Rhinosinusitis(ECRS) shares a similar cytokine profile with CRSwNP and is associated with significant inflammation and poor surgical outcomes. The goal of this

study is to determine if P-gp expression correlates with degree of eosinophilia and severity of radiographic inflammation in patients with CRS without polyps(CRSsNP).

Methods:

IRB approved study utilizing sinus tissue in 28 steroid naïve patients with CRS. P-gp expression was calculated using quantitative fluorescent immunohistochemistry(Q-FIHC) to generate an epithelial to background staining ratio. Patients were stratified into low and high epithelial expression groups(<3 and =3, respectively). Average eosinophils per high powered field(hpf) and Lund-Mackay scores were calculated and compared with P-gp staining ratios using a 2-tailed Student's t-test.

Results:

Among the 28 patients, 4(14.29%) had high P-gp expression ratios(mean+/-SD, 4.94+/-1.81) while 24(85.71%) had low expression ratios(1.91+/-0.49). The number of eosinophils per hpf were significantly greater in the high P-gp expression group as compared to the low expression group(36.10+/-39.40 vs. 6.39+/-11.40, p=0.004). The Lund-Mackay scores were significantly greater in the high P-gp expression group as compared to the low expression group(12.50+/-3.70 vs. 7.29+/-4.75, p<0.05).

Conclusions:

P-gp is known to be overexpressed in CRSwNP. This preliminary study suggests that among patients with CRSsNP, P-gp is similarly overexpressed in those with high tissue eosinophilia and correlates with severity of radiographic inflammation.

2:04PM

The In-Vivo Effect of Leptospermum Honey on Cytokine Expression in CRS Patients

Jamil Manji, BSc.H, Andrew Thamboo, MD, San V. Sunkaraneni, DO, Cathie Garnis, Ph.D., Amin Javer, MD, Vancouver, BC

Background:

Leptospermum (Manuka) Honey (LH) is a natural anti-inflammatory and antimicrobial agent. Leptospermum Honey (LH) nasal irrigation has been demonstrated to be effective in improving symptoms in a subgroup of Chronic Rhinosinusitis (CRS) patients. Currently, the

effect of LH on tissue has only been studied in-vitro.

Objective:

To compare the cytokine expression profile of tissue from patients receiving daily LH irrigation versus normal saline for three months following sinus surgery.

Methods:

Patients with CRS and enrolled in a randomized control trial of LH irrigation on postoperative outcomes were chosen. Tissue biopsies were collected over a three-month course of treatment following functional endoscopic sinus surgery. The Bio-Rad suspension array system was used to measure the concentration of seventeen cytokines on a Luminex platform. Data analysis was performed with a permutation test for non-parametric data and Benjamin and Hochberg method for multiple testing.

Results:

Tissue samples from twenty-two patients were collected. When compared to control patients, four cytokines were significantly elevated (CI=99%) in tissue from the LH group after three months of treatment: IL-6 (p=8.56E-5), IL-8 (p=3.25E-4), IL-13 (p=1.97E-4), and MCP-1 (p=2.21E-4). This pattern was similarly reflected between groups after 5-weeks of treatment.

Conclusion:

Leptospermum (Manuka) Honey has the effect of up-regulating IL-6, IL-8, IL-13, and MCP-1 in sinonasal epithelial tissue.

2:12PM

Differential Expression of VCAM and ICAM by Sinonasal Fibroblasts Among Control and Chronic Rhinosinusitis Patients

Samuel Oyer, MD, Rodney Schlosser, MD, Jennifer Mulligan, PhD, Charleston, SC

Background:

Chronic rhinosinusitis (CRS) is characterized by inflammatory cell migration into sinus tissue with resultant inflammation fueled by a milieu of cytokines. Fibroblasts may play a role in directing inflammation through expression of vascular cell adhesion molecule (VCAM) which attracts eosinophils and mast cells and may contribute to Th2 skewing, and intercellular adhesion mol-

ecule (ICAM) which attracts neutrophils and to a lesser degree, eosinophils, and may contribute to mixed Th1/Th2 skewing. The purpose of this study is to compare sinus fibroblast adhesion molecule expression in vivo among CRS subtypes and in vitro following cytokine stimulation.

Methods:

Sinus biopsies were taken from control patients (n=13), chronic rhinosinusitis without polyps (CRSsNP, n=6), and with polyps (CRSwNP, n=15). In vivo VCAM and ICAM were measured by flow cytometry from single cell suspensions of tissue biopsies. Changes in VCAM and ICAM expression to cytokine exposure was assessed using in vitro cultured sinonasal fibroblasts treated with TNF- α , IL-4, or IFN- γ .

Results:

In vivo VCAM expression was lowest in controls, higher in CRSsNP, and highest in CRSwNP. In vitro stimulation with TNF- α and IL-4, but not IFN- γ , increased VCAM among CRSsNP, while expression in CRSwNP remained elevated with all treatments except IFN- γ . In vivo ICAM expression was elevated in both CRS subtypes. In vitro stimulation with TNF- α and IFN- γ , but not IL-4, increased ICAM expression in all patients with the largest effects among the CRSsNP subgroup.

Conclusions:

Sinonasal fibroblast expression of adhesion molecules varies by disease state and is selectively influenced by exposure to inflammatory cytokines.

2:18PM

Discussion/ Q&A

Session: Topical Therapies and Delivery

Moderators: Karen Fong, MD, Luke Rudmik, MD

2:25PM

Budesonide Nasal Irrigations in the Management of Chronic Rhinosinusitis

David Jang, MD, Vasileios Lachanas, MD, Stilianos Kountakis, MD, Augusta, GA

Objective:

To demonstrate that budesonide nasal irrigations (BNI) improve quality of life and

endoscopy scores in patients with chronic rhinosinusitis (CRS)

Study Design:

Retrospective review of prospectively-collected data.

Methods:

We identified sixty patients who were prescribed BNI postoperatively, but had a lapse in therapy for a minimum of one month. The twenty-item sinonasal outcomes test (SNOT-20) and Lund-Kennedy endoscopy scores with BNI and without BNI were compared using paired analyses, controlling for administration of oral steroids tapers. All patients were prescribed conventional nasal steroids, a leukotriene inhibitor, and nasal saline irrigations. Both parametric (paired t-test) and non-parametric (Wilcoxon test) analyses were performed.

Results:

Thirty patients had eosinophilic chronic rhinosinusitis with polyps (eCRSwNP), thirteen had allergic fungal sinusitis (AFS), thirteen had Samter's triad (ST), and four had eosinophilic chronic rhinosinusitis without polyps (eCRSsNP). Mean follow-up time was 36 months. 55% of patients had lower SNOT scores (mean difference 8.8), and 56% had lower endoscopy scores with BNI (mean difference 3.4). SNOT-20 scores were significantly improved with BNI on paired t-test analysis ($p=0.048$). Endoscopy scores were significantly improved in the eCRS group ($p=0.019$). Non-parametric analysis yielded no significant differences with BNI.

Conclusion:

The addition of BNI is beneficial in the treatment of patients with inflammatory CRS.

2:32PM

Effect of High Dose Intraocular Steroids on Intraocular Pressure

Kristin Seiberling, MD, Christopher Church, MD, Dennis Chang, MD, Janice Nyirady, NP, Francine Park, MS, Loma Linda, CA

Objective:

Intraocular and oral corticosteroids are widely used in the management of chronic rhinosinusitis with nasal polyps (CRSwNP). High dose

topical steroids (HDTs) (budesonide, dexamethasone) are increasingly used for long-term maintenance in these patients. Oral steroids have the potential to cause increased intraocular pressure (IOP) and glaucoma. It is unclear whether HDTs have the same potential. The objective of this study is to determine the effect of HDTs on IOP.

Methods:

Two groups of patients with CRSwNP treated with HDTs (budesonide or dexamethasone) were prospectively enrolled. Patients with history of elevated IOP or glaucoma were excluded. Group one consisted of patients who had been on HDTs at the time of enrollment for at least a month. Group two consisted of patients who were placed on HDTs at the time of enrollment. For group one, IOP was measured once, at enrollment. Group 2 had IOP measured both before and after 4 weeks of therapy.

Results:

Nineteen patients in group 1 and 9 patients in group 2 completed the study. In group 1, the average duration of therapy was 7.4 months (1-30 months). Sixteen patients in group 1 had normal IOP. In 3 patients there were 3 single eye pressures measured over 20 mmHg. None of the patients in group 2 had a significant change in IOP or an IOP over 20 mmHg after 4 weeks of therapy.

Conclusion:

High dose topical steroids given for a period of at least 1 month does not appear to increase IOP.

2:39PM

Effects of Intranasal Budesonide Delivered by Nasal Nebulizer on Symptoms and Objective Measures of Nasal Congestion in Perennial Allergic Rhinitis (PAR)

*Fuad Baroody, MD, James Lane, BSc, Marianella Paz-Silva, MD, Kristal Wimmer-Kunito, MD, Jayant Pinto, MD, Robert Naclerio, MD
Chicago, IL*

Introduction:

We hypothesized that intranasally nebulized budesonide would distribute better and be of greater benefit than an aqueous delivered intranasal steroid. To investigate this hypothesis, we performed a pilot study investigating nebulized budesonide vs placebo.

Methods:

We performed a parallel, randomized, double-blind, placebo-controlled, pilot study in subjects (n=40) with PAR caused by dustmites or mold. After recording baseline symptoms, subjects were randomized to budesonide respulses (0.25 mg), or an equivalent placebo for 26 days. Nasal peak inspiratory flow (NPIF) and symptoms (graded on a 0-3 scale) were recorded by the subjects twice daily. Rhino-conjunctivitis quality of life (QOL) as well as nasal volume, measured by acoustic rhinometry, were obtained at baseline, after 2 weeks, and at the end of treatment.

Results:

The total change from baseline in symptoms was greater for the group on budesonide (-86.5) compared to placebo (-51.5) (p=0.48). When the total change from baseline was compared between the groups, budesonide resulted in higher NPIF (945 l/min) than placebo (485 l/min), p=0.099. QOL improved in both groups compared to baseline with no significant difference between the groups. On the final visit, nasal volume was higher in the group on budesonide (16.9+/-0.9 cc) compared to placebo (14.2+/-1 cc), p=0.055.

Conclusions:

Compared to placebo, administration of nebulized budesonide in subjects with PAR resulted in improvements in symptoms and objective measures of nasal congestion which approached but did not achieve statistical significance. A higher dose of active agent, and a larger number of subjects might have improved statistical significance.

2:46PM

The Effect of Head Position on Distribution of Topical Medication using the Mucosal Atomization Device on the Paranasal Sinuses: A Cadaver Study

*Al-Rahim Habib, BSc., Andrew Thamboo, MD, Rachelle Dar Santos, BSc, Jamil Manji, BSc, Eng Cern Gan, MD, Amin Javer, MD
Vancouver, BC*

Objective:

To determine the effect of head position, Lateral-Head-Back (LHB) versus Vertex-to-Floor (VTF), in the distribution of topical nasal

medication via Mucosal Atomization Device (MAD) in cadaver specimens.

Methods:

Fourteen cadaver specimens received complete functional endoscopic sinus dissection. The MAD was used to administer 1cc of fluorescein impregnated saline solution through the nose in both the LHB and VTF position and visualized by blue light. Sites of distribution (inferior turbinate, anterior septum, middle turbinate, maxillary sinus, ethmoid sinus, frontal recess, frontal sinus, sphenoethmoid recess, sphenoid sinus, nasopharynx and olfactory cleft) were recorded with endoscopic image capturing. Three rhinologists were separately blinded to analyze the images for the presence of staining.

Results:

Fourteen cadaver specimens (n=28 nasal cavities) received administration of the fluorescein nasal spray in the LHB or VTF position. LHB position had significant distribution of fluorescein to all pertinent anatomical sites compared to the VTF position (p=0.01; odds ratio [OR] = 2.77; 95% confidence interval [CI] 2.16-3.57). Specifically, LHB had significantly greater distribution to the ethmoid sinus, frontal recess and frontal sinus when compared to the VTF position (p<0.0001; odds ratio [OR], 3.92; 95% confidence intervals [CI] 2.17-7.10).

Conclusion:

LHB position shows greater distribution to the ethmoid sinus, frontal recess and frontal sinus when compared to VTF position. These areas are of particular clinical relevance to reduce mucosal edema in patients with CRS.

2:53PM

Discussion/Q&A

3:00PM

Break with Industry Partners

3:25PM

Invited Speaker: Andrew Goldberg, MD
Update on the Etiology of CRS: Do our Sinuses Crave Certain Bacteria for Health?

Session: Rhinosinusitis: The Role of Bacteria

Moderators: Pete Manes, MD, Erin O'Brien, MD

3:50PM

Impact of Therapy on the CRS Sinus Microbiome

Cindy Liu, MD, MPH, Katerina Soldanova, BS, Michael Dwan, BS, Lance Price, PhD., Paul Keim, PhD., Andrew Lane, MD
Baltimore, MD

Introduction:

Chronic rhinosinusitis is heterogeneous and typically treated with maximum medical therapy. However, little is known about the impact of medical therapy on the sinus microbiota.

Methods:

Adult patients with or without CRS, who have not received antibiotics or corticosteroids in the previous 8 weeks, were eligible. Three groups were enrolled: Control (n = 40), CRSsNP (n = 4), and CRSwNP (n = 2). A single maxillary sinus swab was collected from the controls, and pre- and post-therapy maxillary sinus swabs were collected from CRS participants. All were collected under endoscopic guidance. RNA was extracted from each swab to generate cDNA for 16S rRNA gene-based pyrosequencing analysis. The pyrosequences were processed, taxonomically classified, and underwent comparative analyses.

Results:

A total of 74,498 sequences were obtained. There was greater diversity (p < 0.05) and more active *Corynebacterium* spp. and *Propionibacterium acnes* in the sinus microbiota of controls than of untreated CRS patients (p < 0.05). In contrast, the untreated CRS microbiota had more of various *Staphylococcus* species. After maximum medical therapy, the treated CRS sinus microbiota showed frequent, minor gains in *P. acnes* and *S. epidermidis* and minor losses of *S. aureus*. But these changes were accompanied by increases in *Pseudomonas* spp. Microbiota diversity increased significantly post-treatment (p < 0.05) to a level comparable to the controls.

Conclusion:

Current maximum medical therapy can positively affect the sinus microbiota, including increasing microbiota diversity. Yet, broad-spectrum antibiotics are limited in restoring microbiota composition and may shift the microbiota towards resistant bacterial types.

3:57PM

The Impact of Culturable Bacterial Community on Histopathology in CRS

*Darren Rom, MD, Kornkiat Snidvongs, PhD, Peta-Lee Sacks, MS, Ellie Pratt, BSc, Raymond Sacks, MD
Sydney, Australia*

Background:

The influence of the local microbial community on inflammatory subtype in chronic Rhinosinusitis (CRS) has been proposed by some researchers. Mechanisms such as super-antigen suggest that Th-2/eosinophilic dominated inflammation is a product of local flora and not an intrinsic mucosal process. The associations between cultured bacteria and the histopathology and clinical features of patients with CRS are described.

Methods:

A cross-sectional study involving patients with CRS undergoing surgery was undertaken. Nasal swabs were performed at surgery for microbiological evaluation. Mucosal biopsies were taken and a histopathological profile was performed. Disease specific quality of life and nasal symptom scores were recorded. The presence of culturable organisms and particular pathogens were compared with histopathology and clinical outcomes.

Results:

95 patients were assessed (51.6% male, mean age 45.6+14.0 years), of which 47.3% had a culturable organism. High tissue eosinophilia (>10/HPF) was found in 34% of these patients and 27% predominantly neutrophilic. No association between tissue eosinophilia and neutrophilia was demonstrated for gram-positive or gram-negative organisms, *Staphylococcus aureus* or *Pseudomonas* species. A culturable pathogen predicted subepithelial fibrosis ($\chi^2=6.36$, $p=0.04$) and gram-negative bacteria were most strongly associated ($\chi^2=18.82$, $p<0.01$). There were no other significant associations with other clinical outcomes.

Conclusion:

These findings suggest the culturable bacterial community has little impact on histopathology in CRS. While there are more sensitive tests to detect bacteria in the sinuses, the impact of the simple 'culturable' bacteria on the underlying pathologic process is limited. Changes, such as

subepithelial fibrosis, suggests colonisation may lead to undesirable local mucosal damage.

4:04PM

Comparing Sinus and Pulmonary Cultures in Patients with Bronchiectasis and Chronic Rhinosinusitis

*Vijay Ramakrishnan, MD, Geoffrey Ferril, MD, Jeffrey Suh, MD
Aurora, CO*

Introduction:

Bronchiectasis is an uncommon disease of the lower airways characterized by bronchial wall destruction and permanent bronchiolar dilation. Several etiologic categories exist, and in general, patients with bronchiectasis have an increased incidence of chronic rhinosinusitis (CRS). The present study evaluates the correlation of bacterial culture results from the upper and lower airways in patients with bronchiectasis and CRS.

Methods:

Retrospective chart review from a tertiary care respiratory hospital was performed. The clinical database was searched by ICD-9 codes for patients with bronchiectasis and CRS, and patients with endoscopically-derived sinus cultures were included in the study. Demographic data, history of prior endoscopic sinus surgery, and bronchiectasis etiology were obtained. Upper and lower airway cultures were compared using the chance adjusted agreement, or Kappa statistic.

Results:

Eighty-one patients were included in the study (age 17-88 years, mean 59; M:F ratio of 44-37). The most common etiologies of bronchiectasis were idiopathic (26), mycobacterium (16), and immunodeficiency (8). A statistically significant correlation of upper and lower airway bacterial cultures was found with respect to the five most common bacteria identified (Kappa=0.323; $p=0.014$).

Conclusion:

The current study supports the Unified Airway Theory from a bacteriologic perspective, as correlation of upper and lower airway bacteriology was seen with most bacteria identified. This finding carries implications for disease pathogenesis, clinical care, and future research.

4:11PM
Discussion/Q&A

4:18PM
**Panel: Everyday Struggles in Our Practices-
Expert Solutions!**

*Moderator: Donald Lanza, MD
Panelists: John DelGaudio, MD; Todd Kingdom,
MD; Marc Dubin, MD; Stacey Gray, MD*

5:00PM
Closing Remarks and Adjournment
*Timothy L. Smith, MD, MPH
President-elect and Program Chair*

COSM 2013 Saturday Session Program Details

Saturday, April 13, 2013
*JW Marriott Grande Lakes Orlando
Mediterranean 5*

8:00AM
Welcome
*Timothy L. Smith, MD, MPH
President-Elect and Program Chair*

8:05AM
Presidential Address
Todd Kingdom, MD

Session: Surgical Practices
Moderators: Greg Davis, MD, Zach Soler, MD

8:15AM
**Office-Based Balloon Sinus Dilation: 52+
week Follow-up of a Prospective Multicenter
Study**

*Ashley Sikand, MD, Stacey Silvers, MD, Raza
Pasha, MD, Alan Shikani, MD, Boris Karanfilov,
MD, Michael Sillers, MD
Henderson, NV*

Introduction:

Balloon Sinus Dilation (BSD) is an increasingly-used tool in Endoscopic Sinus Surgery (ESS), and emerging data demonstrates safety and efficacy when used in an office setting under local anesthesia.

Methods:

Twenty-four week outcomes were previously reported for a large group of chronic rhinosinusitis patients refractory to medical management who underwent office-based transnasal BSD (Karanfilov et al, 2012). Peripheral sinuses were dilated as medically appropriate, and outcomes assessed by the validated SNOT20 quality of life (QOL) instrument and revision rates. Adverse events were collected to unearth any delayed safety concerns. We now report results for patients followed at least 52 weeks.

Results:

Of the original 203 patients enrolled, 122 were followed to their 52 week visit, with an average follow-up of 1.4 years (71.1 weeks). There were no baseline differences in SNOT20 or Lund-McKay scoring between patients who were followed to 52 weeks and those who were not, although those followed to 52 weeks had a significantly higher rate of prior sinus surgery. SNOT20 scores showed statistically significant ($p < 0.0001$) and clinically meaningful (> 0.8) change of -1.1 at 52+ weeks. Revision rate was 7.4% (9/122). There were no device or procedure-related adverse events between 24 and 52+ weeks.

Conclusions:

Performance of ESS with BSD in the office under local anesthesia has previously been shown to be technically feasible, tolerable, and safe. Results presented here demonstrate durable efficacy with clinically-meaningful improvement in symptoms and a low revision rate in a cohort of over 100 patients with an average follow-up of 1.4 years.

8:22AM

Novel Vacuum-Powered Microdebrider for Office Polypectomy: A Case Series

*Amin Javer, MD, Al-Rahim Habib, MD, Eng Cern Gan, MD, Iain Hathorn, MD
Vancouver, BC*

Introduction:

The waiting time for functional endoscopic sinus surgery (FESS) in patients with Chronic Rhinosinusitis (CRS) refractory to medical treatment can be lengthy. Many such patients with nasal polyposis (NP) have significant nasal obstruction resulting in poor quality of life. A simple and safe office-based polypectomy device to de-bulk nasal polyps allows immediate alleviation of nasal obstruction and better access for topical medications.

Objective:

To report the safety and efficacy of a novel vacuum-powered microdebrider as a simple polypectomy device in the outpatient clinic setting.

Methods:

Patients suffering from CRSwNP were selected for office polypectomy with a vacuum-powered microdebrider between May 2012 and November 2012. These patients were either awaiting surgery, not keen for surgery, or had recurrent polyposis post surgery that was amenable to office polypectomy. Pre and post NP grade and procedural questionnaires were completed pertinent to completeness, surgeon experience and patient discomfort.

Results:

Thirty-seven patients underwent office polypectomy in this case series. Thirty-three (89%) procedures were successfully completed. Of incomplete resections, 3 (8%) required traditional electric-powered microdebrider resection of remnant fibrous nasal polyps and 1 (3%) was due to a defective device. Twenty-eight (76%) cases presented with NP below the middle meatus or with total obstruction. Twenty-seven (96%) were reduced to within the middle meatus. All patients reported acceptable discomfort during use of the vacuum-powered microdebrider. There were no complications.

Conclusion:

Our findings indicate that as a simple polypectomy device, this is a safe, effective, well-tolerated and easy to use instrument to resect non-fibrous nasal polyps.

8:29 AM

Nasal Surgery for Obstructive Sleep Apnea-A Role for Endoscopic Sinus Surgery (ESS)?

*Rohan Wijewickrama, MD, Niranjan Sritharan, BSc., Rahul Gupta, MD, Ziad Rohayem, MD, Melinda David-Malesevich, MD, Peter Catalano, MD
Boston, MA*

Background:

The curative impact of nasal surgery on patients undergoing septal and turbinate surgery for obstructive sleep apnea (OSA) has been minimal. New models of nasal airflow mechanics have shed important light on key functional elements of nasal obstruction. Based on this information, we evaluated nasal surgery targeting areas of maximum nasal airflow as an appropriate treatment option for patients with OSA.

Methods:

An IRB-approved study was performed including adult patients with diagnoses of both "chronic rhinosinusitis" and "obstructive sleep apnea" who underwent nasal and endoscopic sinus surgery by a single rhinologic surgeon during an 18-month period. Nasal surgery included: uncinectomy, anterior/total ethmoidectomy, lateral excision of concha bullosa/hypertrophied middle turbinate, septoplasty and inferior turbinate reduction. The primary outcome measure was change in apnea-hypopnea index (AHI). Additional outcome measures included change in body mass index and oxygen-saturation (O₂)-nadir.

Results:

22 patients were identified with pre- and post-operative polysomnography results. Average preoperative AHI was 32.7 (Range 7.5 - 97.3) which was reduced by 19.3 to an average post-operative AHI of 13.4 (Range 3.3 - 47.5) (p=0.0002). However, O₂-nadir and BMI remained relatively stable (? O₂-nadir -1.1%; ?BMI 0.3). No surgical complications occurred in this cohort.

Conclusions:

Nasal surgery for OSA may be further optimized by concurrent targeted middle meatal surgery aimed at increasing sinonasal airflow. Our surgical protocol is the first to demonstrate significant reduction in AHI for OSA patients regardless of severity.

8:36AM

A Comparison of Septal Stapler to Suture Closure in Nasal Septoplasty: A Prospective, Randomized Trial Evaluating the Effect on Operative Time and Outcomes

*Leigh Sowerby, MD, Erin Wright, MD
London, ON*

Background:

Septoplasty requires coaptation of the mucosal flaps; classically this was done with nasal packing. Quilting sutures provide a welcome alternative to packing, but can be time-consuming to place. A septal stapler has recently been developed that provides a rapid alternative to quilting sutures but the time savings has not been quantified.

Study Design:

Prospective, randomized trial comparing a septal stapler to quilting suture for coaptation of mucosal flaps in septoplasty.

Method:

After meeting inclusion criteria, patients underwent septoplasty and inferior turbinoplasty. The total operative time, surgical segment times, and time for closure was recorded. Pre-operative and post-operative NOSE scores were recorded. A sample size of 16 was determined to detect a difference of 5 minutes in closure time.

Results:

A total of 16 patients were enrolled in the study. The mean time for closure with septal stapler was 35 +/-22 seconds versus 7 minutes +/- 1 minute 10 seconds for suture closure ($p < 0.0001$). The mean total operative time using the septal stapler was 28 minutes +/- 6 minutes while 43 minutes +/- 13 minutes was required for suture ($p = 0.014$). No difference in post-operative complications was seen or in pre- and post-operative NOSE scores.

Conclusions:

Coaptation of the mucosal flaps in septoplasty with a septal stapler affords a time-savings in the operating room with no difference in operative outcome.

8:43AM

Discussion/Q&A

Session: Novel Research at the Cutting Edge

*Moderators: Vijay Ramakrishnan, MD,
Ameet Singh, MD*

8:50AM

Identification of Human Nasal Mucosal Epithelial Stem Cells

*Mrinmoy Sanyal, PhD, Justin Edward, MS
Ethan Soudry, MD, Dawn Bravo, PhD
Peter Hwang, MD, Jayakar Nayak, MD, PhD
Stanford, CA USA*

Introduction:

New epithelial cells are generated through the proliferation and differentiation of resident stem cells in the adult nasal cavity. In several diseases, such as cystic fibrosis (CF) and chronic rhinosinusitis (CRS), we hypothesize that stem cells are likely functionally defective or fail to regenerate to maintain normal mucociliary clearance. To better understand the etiopathogenesis of these conditions, we attempted to reliably define and characterize human nasal epithelial stem cell populations.

Methods:

Single cell suspensions of human ethmoid sinus tissue were prepared following endoscopic sinus surgery. Based on surface markers established for lung epithelial progenitor cells, we used a panel of antibodies (epithelial cell adhesion molecules (EpCAM), CD45 (for hematopoietic cells), nerve growth factor receptor (NGFR/CD271), intercellular adhesion molecule-1 (ICAM-1/CD54) and integrin alpha 6 (ITGA6/CD49f)) to identify epithelial progenitor candidates by hi-dimensional flow cytometry and the gating technique of fluorescence minus one (FMO) controls. A lineage-negative population was purified to 100% homogeneity and analyzed by immunofluorescence microscopy and air-liquid interface culture.

Results:

A rare population of approximately 0.06% of total ethmoid cells was discriminated as EpCAM-CD45-, and NGFR+/ICAM-1+/ITGA6+ by surface marker expression. Immunofluorescence microscopy confirmed the purity and viability of sorted cells, and upon in vitro culture, the clonal cell population spontaneously differentiated into epithelial lineage cells.

Conclusion:

Based on cellular coordinates of murine and human lung epithelial cells, we have identified a promising population of putative multipotent native human nasal epithelial stem cells within sinus tissues with the capacity to differentiate into mucociliary cells of the normal nasal epithelium.

8:57AM

Distribution of Human Nasal Mesenchymal Stem Cells

*Bradley Goldstein, MD, PhD, Seth Lieberman, MD, Roy Casiano, MD
Miami, FL USA*

Introduction/Background:

Olfactory neurons reside within the neuroepithelium of the human nasal mucosa. Neuroepithelium is restricted to the superior regions, lining portions of the septum and superior turbinates in general. Olfactory epithelium is a self-renewing tissue, producing new neurons from stem and progenitor cells in its basal layers. In addition, there exists a mesenchymal-like stem cell (MSC) located within the underlying lamina propria. Little is known about the function of this nasal MSC, or its relationship to the olfactory lineage, but there is considerable interest in utilizing the nasal MSC for cell-based therapies. We sought to further explore the biology of the nasal MSC by establishing neurosphere cultures from adult human nasal biopsies.

Methods:

Adult patients undergoing endoscopic surgery for treatment of sinonasal or skull base disorders were consented for the use of nasal tissue samples for research. We established cultures from superior, middle and inferior turbinates. Cells grown as neurospheres were analyzed immunochemically and via flow cytometry.

Results:

Nasal MSC cultures were obtained from olfactory as well as non-olfactory regions, from all 3 turbinates. These MSC cultures exhibit characteristic robust neurosphere formation and express CD90, CD105, STRO-1 and nestin.

Conclusions:

The unexpected anatomic distribution of nasal MSCs suggests a broad role for this cell, and further experiments are underway to define

MSC function. Given the rapid pace in efforts aimed at the development of cell-based therapies, these findings have important implications for efforts aimed at utilizing nasal MSCs therapeutically.

9:04AM

Constitutive Expression of VEGF Gene Family Ligand and Receptors on Human Upper and Lower Airway Epithelial Cells

*Jean Kim, Md, PhD, Hyun Lee, Ph.D,
Baltimore, MD*

Introduction:

We previously reported that VEGF-A is abundantly expressed by primary human nasal epithelial cells (PNEC) and functions to promote cell hyperplasia in chronic rhinosinusitis with nasal polyposis (CRSwNP). Therefore we aimed to examine the full expression profile of other members of the VEGF gene family of ligands and receptors that may potentially play a role in the development of CRSwNP.

Methods:

mRNA and protein expression of VEGF genes, receptors, and co-receptors was examined from cultured PNEC and compared to that from primary human bronchial epithelial cells (PBEC) and BEAS2B cell line by realtime PCR and flow cytometry.

Results:

We report abundant expression of VEGF-A, VEGF-B, and VEGF-C, detected by mRNA and flow cytometric analysis on PNEC. We herein report that there is significant expression of VEGFR3 and both neuropilin co-receptors, NP1 and NP2, but no detectable VEGFR1 or VEGFR2 at baseline conditions on PNEC. Lower airway PBEC and BEAS2B cells displayed similar patterns of expression.

Conclusions:

PNEC express high constitutive levels of VEGF gene family homolog of ligands and receptors. Expression of multiple VEGF ligand-receptor combinations may function as redundant pathways to promote upper and lower airway epithelial cell growth during airway inflammation.

9:11AM

Anti-inflammatory Mediators and Sleep Dysfunction in Chronic Rhinosinusitis

*Jeremiah Alt, MD, PhD, Nathan Sautter, MD, Kara Detwiller, MD, Dennis Trune, MD, MBA, Jess Mace, MPH, Timothy Smith, MD, MPH
Portland, OR*

Introduction:

The pathophysiology of sleep disturbance in patients with chronic rhinosinusitis (CRS) is poorly understood. Pro-inflammatory cytokines are involved in physiological sleep regulation. It is hypothesized that anti-inflammatory cytokines inhibit non-rapid eye movement sleep (NREMS) through inhibition of somnifacient pro-inflammatory mediators. We therefore, evaluated the expression of anti-inflammatory mediators known to inhibit NREMS sleep in patients with CRS.

Methods:

A total of 20 patients diagnosed with medically refractory CRS were prospectively enrolled and completed the Pittsburgh Sleep Quality Index (PSQI) survey. Ethmoid mucosa samples were obtained during endoscopic sinus surgery and quantitative real-time polymerase chain reaction was performed for interleukin (IL) -4, -13, and transforming growth factor beta (TGF- β). The average change in crossover threshold was calculated and differences in target gene expression were correlated to both PSQI total and sub-domain scores using unadjusted Spearman's correlation coefficients.

Results:

Eighteen (90%) of study subjects with CRS reported poor quality of sleep as measured by the PSQI. Increased expression of TGF- β significantly correlated with poor PSQI sleep duration scores ($r = -0.443$; $p = 0.050$), while elevated levels of IL-4 expression were associated with worse sleep disturbance ($r = -0.548$; $p = 0.012$). Increased expression of IL-13 also correlated with worse total PSQI scores ($r = -0.417$; $p = 0.075$).

Conclusions:

Patients with CRS generally have poor sleep quality as measured by the PSQI instrument. The up-regulation of anti-inflammatory mediators in CRS may be, in part, associated with the inflammation-brain regulated effects on sleep quality.

9:18AM

Discussion/Q&A

9:25AM

Panel: Inferior Turbinate Reduction Surgery: Minimalist vs. Turbinator

Moderator: Pete Batra, MD

*Presenters: Roy Casiano, MD,
Martin Citardi, MD*

9:55AM

Break with Industry Partners

Session: Disease Manifestations and Treatment Outcomes

*Moderators: Ayesha Khalid, MD,
Abtin Tabaei, MD*

10:25AM

A Systematic Review and Meta-analysis of Asthma Outcomes Following Endoscopic Sinus Surgery for Chronic Rhinosinusitis

*Rishi Vashishta, MD, Rodney Schlosser, MD
Zachary Soler, MD, MSc
Charleston, SC USA*

Background:

A clinical question which commonly arises is whether endoscopic sinus surgery for chronic rhinosinusitis can improve asthma-specific outcomes in patients suffering from both conditions. This study presents a systematic review and meta-analysis to assess the effects of endoscopic sinus surgery on asthma outcomes.

Data Sources:

Ovid MEDLINE and the Cochrane databases.

Methods:

The above sources were searched to identify studies examining asthma outcomes in patients with chronic rhinosinusitis following endoscopic sinus surgery. Included studies involved a cohort of at least 5 patients and reported at least one postoperative asthma outcome following sinus surgery.

Results:

Twenty-one studies involving 812 patients were included in the analysis. Mean (SD) follow up was 26.7 (30.3) months postoperatively. Patients reported improved overall asthma control in 77.7% (95% CI, 72.4% to 82.3%) of cases. The frequency of asthma attacks decreased in 85.1% (95% CI, 75.1% to 91.7%)

of patients and the number of hospitalizations decreased in 64.8% (95% CI, 53.2% to 74.9%). Decreased use of oral corticosteroid was seen in 72.9% (95% CI, 67.3% to 77.8%) of patients; inhaled corticosteroid use decreased in 28.6% (95% CI, 23.1% to 35.0%) and bronchodilator use decreased in 36.4% (95% CI, 29.4% to 44.1%) of patients. Mean (SD) improvement in percent predicted FEV1 was 1.62%, but was not statistically significant.

Conclusions:

Endoscopic sinus surgery in patients with concomitant bronchial asthma appears to improve some but not all asthma outcome measures. A lack of controlled clinical trials limits the strength of conclusions which can be reached.

10:32AM

Surgical Management of Chronic Rhinosinusitis in Cystic Fibrosis: A Systematic Review

Jonathan Liang, MD, Thomas Higgins, MD, MSPH, Stacey Ishman, MPH, Emily Boss, MD, MPH, James Benke, BS, Sandra Lin, MD Baltimore, MD

Objective:

To systematically review literature on the effectiveness of surgical management for chronic rhinosinusitis in cystic fibrosis (CF) patients.

Methods:

We performed a literature search encompassing the last 25 years in PubMed, Embase, and Cochrane CENTRAL. Inclusion criteria included English language papers containing original data, more than 6 subjects, and measurable clinical outcomes. Data was systematically collected on study design, patient demographics, clinical characteristics and outcomes, and level-of-evidence. Two investigators independently reviewed all manuscripts. A quality assessment of included studies was performed to assess bias.

Findings:

The initial search yielded 415 abstracts, of which 21 articles were included, detailing 561 adult and pediatric CF patients who underwent surgical therapy. Surgical treatment in all studies included endoscopic sinus surgery. Outcome measures included sinonasal symptoms (12/21), endoscopic findings (6/21), pul-

monary function testing (6/21), recurrence or revision surgery (4/21), hospitalization (3/21), need for antibiotic therapy (1/21), pulmonary exacerbations (1/21), and radiographic findings (1/21). The level-of-evidence was predominantly level 4 (16/21); there were no level 1 evidence studies. Most studies found improvement in symptom measures and endoscopic findings but no improvement in lower airway function after surgical therapy. Post-operative measures of the other outcomes were inconclusive or inconsistent.

Conclusions:

Endoscopic sinus surgery for adult and pediatric CF sinusitis yielded clinical improvement primarily in patient sinonasal symptoms and endoscopic findings. It is unclear whether surgical intervention modifies lower airway disease. Future prospective studies with predetermined, objective, and validated outcome measures are needed to determine the effectiveness of surgical intervention for CF-related chronic rhinosinusitis.

10:39AM

Ostiomeatal Occlusion Does Not Correlate with Sinus Disease in Eosinophilic Rhinosinusitis*

Dr Kornkiat Snidvongs

**(PJ Wormald Research Award from Australasian Rhinologic Society)*

Objective:

Ostiomeatal complex (OMC) occlusion may play a role in the pathogenesis of some chronic rhinosinusitis (CRS) subgroups but its role in diffuse mucosal inflammation is strongly debated. The association between radiological OMC occlusion and its draining sinuses in patients with eosinophilic rhinosinusitis (E CRS) compared to non E CRS is investigated.

Methods:

Patients with CRS who underwent endoscopic sinus surgery were investigated. Pre-operative computed tomography scans were evaluated. Structured histopathology reporting was performed. The study group was patients with high tissue eosinophil >10/high power fields (HPF) and the control group were patients with low tissue eosinophil ≤10/HPF. The radiological relationship of OMC occlusion to the draining sinus was analyzed in each group.

Results:

Seventy patients with a mean age of 49.7 ± 14.1 years were analyzed. Forty-one (48.7%) patients had high tissue eosinophil $>10/HPF$. All patients with ECRS had maxillary disease and there were 36.2% without OMC occlusion. There was no association of OMC occlusion to the either anterior ethmoid (ECRS; OR=1.84 (0.24, 14.14), $p=0.55$, non ECRS; OR=1.57 (0.34, 7.33), $p=0.56$) or frontal sinuses (ECRS; OR=0.67 (0.12, 3.82), $p=0.65$, non ECRS; OR=1.58 (0.45, 5.54), $p=0.47$). For patients with non-ECRS, maxillary sinus disease was present in 96.2% of those with OMC occlusion and 50% of those without (odds ratio (OR) =25.0 (2.77, 226.08); $p<0.001$).

Conclusion:

OMC occlusion is not associated with draining sinuses for patients with ECRS. Simple surgical interventions directed at the OMC are unlikely to be of benefit to this CRS subgroup.

10:46AM

Discussion/Q&A

Session: Treatment Outcomes and Cost Effectiveness

Moderators: Jean Anderson Eloy, MD, Jamie Litvack, MD

10:53AM

Impact of Continued Medical Therapy in Patients with Refractory Chronic Rhinosinusitis

*Kristine Smith, MD, Luke Rudmik, MD
Calgary, Alberta Canada*

Background:

Prolonged surgical wait-times in Canada offers a unique opportunity to study the impact of ongoing medical therapy in patients with refractory chronic rhinosinusitis (CRS) who are candidates for endoscopic sinus surgery (ESS). The primary objective of this study was to evaluate the change in disease-specific quality of life (QoL) in patients with refractory CRS who received ongoing medical therapy pending ESS.

Methods:

A total of 18 patients were prospectively enrolled between November 2011 and November 2012. Inclusion criteria: > 18 years, CRS defined by AAO adult sinusitis guidelines,

failed initial medical therapy (defined by a minimum of 3 months of topical intranasal steroid, 7 day course of systemic steroid, +/- 2 week course of broad spectrum systemic antibiotic), and elected ESS. The primary outcome was change in disease-specific QoL (SNOT-22) between time of enrollment and immediately prior to ESS. Secondary outcomes included: medication usage, physician visits, and work days missed.

Results:

At the time of enrollment, the mean SNOT-22 (SD) score was 58.8 (19.5). Following continued medical therapy for a mean of 5.7 months, the mean SNOT-22 score increased to 63.4 (22.3). This difference was not statistically significant ($p=0.509$).

Conclusions:

Data from this study suggests that patients with refractory CRS receive no improvement in disease-specific QoL from ongoing medical therapy while awaiting ESS. This highlights the importance of ESS in the management of refractory CRS.

11:00AM

Impact of Symptom-based Risk Stratification on the Cost Effective Diagnosis of Patients with Chronic Rhinosinusitis Symptoms

*Bruce Tan, MD, Guanning, Lu, BS, Randy Leung, MD, Rakesh Chandra, MD, David Conley, MD, Robert Kern, MD
Chicago, IL*

Background:

Current symptom criteria poorly predict a chronic rhinosinusitis (CRS) diagnosis resulting in cost inefficient treatment of symptomatic patients.

Objective:

To analyze the positive predictive value (PPV) of symptoms and examine the cost effectiveness of the subsequent treatment algorithm using a Markov economic model.

Methods:

We calculated the PPV of individual symptoms previously collected from a cross-sectional study of 80 patients presenting to an otolaryngology clinic with CRS symptoms. Classification and regression tree (CART) analysis optimized

the sequence of symptoms to risk stratify CRS patients. Calculated PPV were applied to a Markov economic model comparing an upfront CT (uCT) algorithm against an empiric medical therapy (EMT) algorithm depending on the availability of point of care (POC) imaging.

Results:

The PPV of individual symptoms ranged from 0.39 to 0.69 for patients reporting facial pain and hyposmia respectively. CART modelling constructed a dichotomous tree based on forehead pain, maxillary pain, hyposmia, nasal discharge, and facial pain (C-statistic 0.83). When POC CT is available, median costs (\$64-\$319) favor uCT for all individual symptoms. If POC CT is unavailable, median costs favor uCT for most symptoms except hyposmia (-\$100) and discolored nasal discharge (-\$24) but all symptoms were equivocal on cost sensitivity analysis. The three-tiered CART model subcategorized patients into tiers where uCT was favored (median costs: \$332-\$504) and others where EMT was always favored (median costs -\$121 to -\$275).

Conclusion:

Individual symptoms, or symptoms in combination, varied the likelihood of a CRS diagnosis and impacts the cost effectiveness of subsequent medical care.

11:07AM

Comparison of Outcomes of Endoscopic Ligation and Endovascular Treatment of Sphenopalatine Artery for Epistaxis: a five-year Series from a Single Institution

*Nirav Thakkar, MD, Joseph Raviv, MD
Chicago, IL*

Introduction:

Approximately 90% of patients with epistaxis are treated effectively with an anterior nasal packing and outpatient follow-up. Conventional treatment for those that fail anterior packing is a posterior packing with inpatient monitoring for 3-5 days. Transnasal endoscopic sphenopalatine artery ligation (ESAL) and endovascular embolization are options typically reserved for cases in which packing has failed. The objective of this study is to evaluate the safety and efficacy of ESAL and intravascular embolization for the treatment of severe epistaxis.

Methods:

This study is a retrospective review of all ESAL and embolization procedures from 2007 to 2012 at our institution. A comparison of safety and efficacy of each procedure was performed along with a literature review on ESAL, embolization, and the cost effectiveness of each procedure.

Results:

Over 5 years, 33 patients were treated with ESAL and 11 were embolized with success rate 94% and 82% respectively. There was one post-operative complication for ESAL patients, which was sinusitis that resolved with antibiotic treatment. Of the patients treated with embolization, 1 patient died and 1 patient had severe facial pain requiring prolonged narcotic pain control.

Conclusion:

This is the largest series reported in the US of ESAL patients and the only review that compares them to embolization. Surgical intervention by ESAL for the treatment of severe epistaxis was safer and more effective than embolization. Given the safety, efficacy, and cost effectiveness of early intervention, otolaryngologists should strongly consider ESAL as primary treatment for severe epistaxis.

11:14AM

Discussion/Q&A

11:19AM

Panel: The Cutting Edge: From Lab Bench to Bedside-Improving Care for Our Patients

Moderator: Ralph Metson, MD

*Panelists: Bruce Tan, MD; Sarah Wise, MD;
Brad Woodworth, MD*

12:00PM

Lunch Break with Industry Partners

Session: Steroids in Chronic Rhinosinusitis

Moderators: *Steve Pletcher, MD,*
Nathan Sautter, MD

1:00PM

The Effect of Intranasal Fluticasone Propionate Irrigations on Salivary Cortisol, Intraocular Pressure, and Posterior Subcapsular Cataracts in Postsurgical Chronic Rhinosinusitis Patients

Li-Xing Man, MSc, MD, MPA, Zachary Farhood, BA, Robert Feldman, MD, Philip Orlander, MD Amber Luong, MD, PhD, Samer Fakhri, MD Martin Citardi, MD Rochester, NY USA

Introduction:

Intranasal corticosteroid irrigations, especially budesonide, are used increasingly in the management of chronic rhinosinusitis. In post-endoscopic sinus surgery patients, irrigations may offer improved delivery at higher doses to the paranasal sinuses than intranasal spray preparations. Fluticasone propionate may have higher potency and lower systemic bioavailability than budesonide, but there is little data on its effects as an intranasal irrigation on the adrenal axis or on ocular findings.

Methods:

Adult patients who had previously undergone bilateral endoscopic sinus surgery and had not taken systemic corticosteroids in the last 6 months were prospectively enrolled. Subjects irrigated with 3 mg of fluticasone propionate in 240 mL saline solution twice daily. Salivary cortisol, intraocular pressure, and the presence of posterior subcapsular cataracts were measured before drug administration and after 6 weeks of continuous use.

Results:

Twenty-two subjects completed the study. No subjects had salivary cortisol levels below the normal range before or after therapy, and there was no statistical difference in mean salivary cortisol levels pre- and post-treatment (0.301 vs. 0.399 µg/dL; $p=0.30$). There was no clinical or statistical difference in mean intraocular pressure before or after therapy (13.5 vs. 13.5 mm Hg; $p=0.86$). No subjects developed a posterior subcapsular cataract.

Conclusion:

Fluticasone propionate irrigations did not suppress salivary cortisol levels or result in ocular changes. Irrigation with fluticasone propionate 3 mg in 240 mL saline twice daily may be a safe alternative to other intranasal or systemic corticosteroid treatments for chronic rhinosinusitis patients.

1:07PM

When do the Risks of Repeated Courses of Corticosteroids Exceed the Risks of Surgery?

Randy Leung, MD, Keith Dinnie, Timothy Smith, MD, MPH Barrie, ON

Introduction:

When patients with chronic rhinosinusitis with nasal polyposis require repeated courses of systemic corticosteroids to maintain quality of life, the relative risk of repeated steroid courses versus surgery is unclear. This study aims to identify the threshold when the risks of repeated courses of corticosteroid exceed the risks of surgery.

Methods:

An evidence-based risk analysis was simulated using literature reported complication rates, quality of life changes, and Medicare costs.

Results:

Risk simulations demonstrated a base case estimate of a five-fold risk associated with surgery over a single course of prednisone.

Conclusions:

This represents the first rationalized evidence-based assessment of risk for repeated systemic steroids versus surgery. This threshold provides a tool to clinicians for evidence-based decision making in complex situations.

1:14PM

Systemic Prednisone Administration Selectively Alters Granulocyte Subsets in Nasal Polyps from AERD and CRS Patients

Justin Edward, MS, Mrinmoy Sanyal, PhD, Vijay Ramakrishnan, MD, Peter Hwang, MD, Todd Kingdom, MD, Jayakar Nayaki, MD, PhD Stanford, CA

Introduction:

Nasal polyps (NP) are classically associated with abundant eosinophils; however, other granulocytes such as neutrophils and basophils are also present and clinically significant. Though systemic steroids transiently reduce the cellular burden of NP, the mechanism for this change remains unclear. Therefore, we sought to determine the effects of prednisone treatment on granulocyte subsets in patients with chronic rhinosinusitis with nasal polyps (CRSwNP) and in the subset with aspirin exacerbated respiratory disease (AERD).

Methods:

NP, adjacent ethmoid sinus tissue, and peripheral blood mononuclear cells (PBMCs) were obtained from patients undergoing endoscopic sinus surgery. Fresh samples from five cohorts: CRSwNP±prednisone (n=6 each), AERD±prednisone (n=6 each), and controls (n=9), were analyzed by hi-dimensional flow cytometry to gate and quantify all granulocyte populations. Some specimens were archived for confocal immunofluorescence microscopy.

Results:

Eosinophils are significantly reduced ($p=0.0004$, $n=6$) in NP in both AERD and CRSwNP after preoperative treatment with oral prednisone. A significant decrease in neutrophils ($p<0.05$, $n=6$) is also seen in NP after prednisone treatment in CRSwNP, but not in AERD. In contrast, steroids do not significantly change the percentage of basophils ($p=0.48$, $n=6$) within NP from either group. Interestingly, granulocyte subsets in both the adjacent ethmoid sinus mucosa and PBMCs are unaffected by steroid treatment. Confocal microscopy further validated these findings.

Conclusions:

Eosinophil and neutrophil counts are focally affected within NP tissue by systemic steroid exposure, without notable granulocyte alterations in the surrounding regional tissues.

These data provide direct insights into the cellular effects of prednisone exposure in patients with CRSwNP.

1:21PM

Chronic Rhinosinusitis with Nasal Polyps is Associated with Increased Nrf2 Mediated Antioxidant Gene Expression

Murugappan Ramanathan, MD, Gina Paris, BS, Michelle Mendiola, BS, Shyam Biswal, PhD, Andrew Lane, MD Baltimore, MD

Background:

Chronic Rhinosinusitis with Nasal Polyps (CRSwNP) is an uncontrolled inflammatory condition and its pathogenesis remains unclear. Recent studies suggest that environmental exposures may contribute towards sustained sinonasal inflammation. Nrf2 is a redox-sensitive transcription factor that upregulates a battery of antioxidative genes and cytoprotective enzymes that constitute the cellular response to environmental exposures and oxidative stress. The role of Nrf2 and its associated anti-oxidant genes in CRS has never previously been explored.

Methods:

Sinonasal mucosal biopsies from the ethmoid cavity were taken from CRSwNP patients during routine endoscopic sinus surgery. Similar tissue was also acquired from non-diseased control patients during orbital or skull base surgery. mRNA was extracted from samples and real-time PCR was performed for the following Nrf2 mediated antioxidant genes: HO-1, GCLC, GCLM, and NQO1.

Results:

mRNA for all the Nrf2 regulated anti-oxidant genes was detected in both CRSwNP and control patients. However, CRSwNP patients had statistically significant increases in mRNA expression of Nrf2 mediated antioxidants when compared to controls.

Conclusions:

Elevated levels of Nrf2 mediated anti-oxidants in CRSwNP likely represents the body's cellular defense against increased oxidative stress. Although Nrf2 levels and associated anti-oxidants are increased in CRSwNP compared to controls, these levels may be insufficient to

detoxify the oxidative stress burden. Further studies are needed to determine the potential of Nrf2 mediated anti-oxidants as a therapeutic target in CRSwNP.

1:28PM

Discussion/Q&A

Session: Management of CSF Leaks and Olfaction

*Moderators: Nithin Adappa, MD,
Jonathon Liang, MD*

1:35PM

Acetazolamide for High Intracranial Pressure CSF Leaks

*Mohamad Chaaban, MD
Ajaz Chaudhry, MD, Elissa Illing, MD
Kristen Riley, MD, Bradford Woodworth, MD
LaGrange, GA USA*

Objectives/Hypothesis:

Acetazolamide has become a standard treatment for CSF leaks associated with intracranial hypertension. The purpose of the current study was to evaluate the effectiveness of acetazolamide at decreasing elevated CSF pressure in this patient population.

Methods:

Prospective evaluation and data collection of high intracranial pressure CSF leaks was performed. Subjects underwent CSF diversion and postoperative assessment of pressure changes via a standard protocol. Lumbar drains or ventriculostomies were clamped on postoperative day 2 for 4 hours prior to assessment with a manometer. Acetazolamide (500 mg) was administered orally immediately following the recording and CSF pressure measured after 4 hours. Data regarding demographics, etiology of CSF leak, body mass index (BMI), location and size of defect, and clinical follow up were also collected.

Results:

Thirty-two patients (avg. age 50) with 36 CSF leaks (33 spontaneous, 3 traumatic) and an average BMI of 35.1 were evaluated. Success rate of primary repair was 94.4%, but all patients were effectively sealed with subsequent endoscopic reconstruction (avg. 80

weeks follow up). Intracranial pressure (cm H₂O) via lumbar puncture or ventriculostomy (n=2) after clamping was 31.3±7.3. Administration of acetazolamide significantly decreased intracranial pressure to 21.4±7.4 in the 4 hour time frame studied (p<0.0001).

Conclusion:

This study provides some of the first direct evidence of decreased intracranial pressure associated with the oral administration of acetazolamide. In combination with the excellent endoscopic repair outcomes noted in a high risk population, this evidence supports the routine use of acetazolamide in patients with high intracranial pressure CSF leak.

1:42PM

Porcine Small Intestine Submucosal Graft for Endoscopic Skull Base Reconstruction

*Elisa Illing, MD, Mohamad Chaaban, MD,
Kristen Riley, MD, Bradford Woodworth, MD
Birmingham, AL*

Objectives/Hypothesis:

Skull base defects and encephaloceles of the sinus and nasal cavities are routinely repaired endoscopically with high success rates using a variety of materials including bone, cartilage, fascia, acellular dermal allografts, and xenografts. However, there is a paucity of data regarding the use of porcine small intestine submucosal (SIS) grafts for endoscopic dural repair. The purpose of the current study was to review outcomes using SIS grafts in the endoscopic reconstruction of skull base defects.

Methods:

Review of prospectively collected data regarding skull base defect repair using SIS was performed. Demographics, location and size of skull base defect, method of repair, successful closure, and complications were recorded.

Results:

Over 4 years, 146 patients (avg. age 46) underwent 161 primary skull base repairs utilizing porcine SIS. Etiologies included tumor (75), spontaneous (47), trauma (34), and congenital (5). The majority of repairs were in combination with a nasoseptal flap (n=113). Average defect size (length vs. width) was 13.3x10.7mm. Success rate on first attempt was 94.4% (152/161), but all defects were effectively

sealed on subsequent endoscopic revision. The average follow up was 77 weeks. There was an 8.1% incidence of major postoperative complications [recurrent CSF leak (9), meningitis (2), periorbital cellulitis (1), and invasive fungal sinusitis (1)] that resulted in no residual long term sequelae.

Conclusion:

Dural repair utilizing porcine SIS graft was associated with excellent outcomes in the current study and supports its routine use in the endoscopic closure of skull base defects.

1:49PM

Interferon Gamma Causes Olfactory Dysfunction Without Concomitant Neuroepithelial Damage

*Andrew Lane, MD, Tatyana Pozharskaya, MS
Baltimore, MD*

Introduction:

Olfactory loss is a debilitating symptom of chronic rhinosinusitis (CRS). The pathophysiology of inflammatory olfactory dysfunction likely involves both conductive and sensorineural components. To study the interaction of CRS-associated inflammatory cytokines with the olfactory epithelium, a transgenic mouse model was developed that allows temporally-controlled local gene expression. Interferon-gamma (IFNG) is a prototypical Th1 cytokine linked to non-polypoid CRS, as well as sinonasal viral and bacterial infections. In this study, the effects of chronic IFNG expression on olfactory histology and function were investigated.

Methods:

IFNG secretion by olfactory sustentacular cells was induced in the transgenic mouse. Viability and gross behavior were unaffected. Mice were sacrificed after 6 weeks of IFNG expression, and olfactory tissue was studied by histology, immunohistochemistry, and electro-olfactogram (EOG). Findings were compared with uninduced littermates.

Results:

IFNG expression did not result in alteration of the normal histologic architecture of the neuroepithelium or lamina propria. However, EOG recordings demonstrated a significant decrease in odorant responses after IFNG expression. In addition, a marked increase in submucosal

CD45-positive cells was observed, the majority of which were CD3 and CD4 positive lymphocytes.

Conclusion:

Chronic IFNG expression in the mouse olfactory epithelium results in diminished odorant responsiveness, despite the absence of inflammatory tissue damage. This suggests a direct effect of IFNG on olfactory neuron function that may underlie olfactory loss in CRSsNP or viral infections. The infiltration of submucosal lymphocytes raises the possibility that other downstream cytokines also contribute to olfactory dysfunction.

1:56PM

Discussion/Q&A

2:03PM

Panel: Evidence-Based Rhinology: How has the Evidence Changed my Treatment of Sinonasal Disease?

*Moderator: Michael G. Stewart, MD, MPH
Panelists: Jack Krouse, MD; Brent Senior, MD;
David Poetker, MD; Stephanie Joe, MD*

2:55PM

Break with Industry Partners

Session: Sinonasal and Skull Base Tumors

*Moderators: Troy Woodard, MD ,
Adam Zanation, MD*

3:25PM

Evolution in the treatment of sinonasal inverted papilloma: the Pedicle Oriented Endoscopic Surgery (POES)

*Alessandro Pusateri, MD, Georgios Giourgos, MD, Elina Matti, MD, Francesco Chu, MD
Michele Caputo, MD, Fabio Pagella, MD*

Introduction:

The global efficacy of the endoscopic treatment in sinonasal inverted papilloma (IP) is known, and reaches a 95%. The objective of this study is to evaluate an even more conservative endoscopic approach, based on the research of the tumor's pedicle and the aggressive treatment concentrated on its site of attachment.

Methods:

Retrospective analysis of the patients treated in our institution for sinonasal IP, between 2002 and 2011 and a minimum of 12 months of follow-up. Group A received a standard endoscopic sinus surgery including whole sinus' demucosization, bony wall drilling and endoscopic medial maxillectomy in case of maxillary localization. Group B patients' instead, underwent the Pedicle Oriented Endoscopic Surgery (POES), in this group, bony demucosization and drilling were selectively conducted around the site of pedicle's attachment of the tumor.

Results:

The cohort included 73 patients (49 males, 24 females), mean age 59 years (25 – 83 years), mean follow-up 63 months (12 – 138 months). Group A/Group B: 37/36 patients. IP persistence-recurrence: Group A/Group B: 0/1 cases. Oncological success: Global endoscopic/Group A/Group B: 98.6% (72/73) / 100% (37/37) / 97.2% (35/36). No major intra- and post-operative complications were observed.

Conclusions:

Our data confirm the efficacy of the endonasal endoscopic treatment for sinonasal IP. Moreover, the even more conservative endoscopic treatment proposed (POES) seems to offer good control of the disease, shorter operating time, avoidance of unnecessary surgery with respect of not involved structures and permits a follow-up aimed at the site of pedicle's attachment.

3:32PM

p16, EGFR, CyclinD1, and p53 Staining Patterns for Inverted Papilloma

*Giant Lin, MD, Mark Zacharek, MD, Jonathan McHugh, MD, Thomas Carey, PhD
Ann Arbor, MI*

Introduction:

We aim to better characterize the staining patterns of inverted papilloma (IP) with and without carcinoma by performing immunohistochemistry with p16, EGFR, p53, and Cyclin D1 antibodies on a large patient cohort.

Methods:

We identified 162 IP specimens from 122 patients treated at the University of Michigan between 1996 and 2011. 22 specimens con-

tained carcinoma. Tumor was extracted for construction of two tissue microarrays and stained for p16, EGFR, p53, and Cyclin D1. Tumor staining intensity and percentage staining were scored by an experienced head and neck pathologist.

Results:

For IP and IP with carcinoma, p16 stained in 100/133 (75%) versus 4/21 (19%) specimens ($p < 0.001$), EGFR in 71/135 (53%) versus 15/21 (71%) specimens (NS), p53 in 65/135 (48%) versus 16/21 (76%) specimens ($p < 0.05$), Cyclin D1 in 110/136 (81%) versus 16/21 (76%) specimens (NS). Mean percentage staining for IP and IP with carcinoma was 12% versus 7% for p16 ($p < 0.001$), 20% versus 34% for EGFR (NS), 4% versus 24% for p53 ($p < 0.001$), and 17% versus 21% for Cyclin D1 (NS). Applying criteria for positive staining as $> 10\%$, specimens with carcinoma were positive for p16 in 14%, EGFR in 68%, p53 in 50%, and CyclinD1 in 45%. Benign IP was positive for p16 in 35%, EGFR in 43%, p53 in 14%, and CyclinD1 in 51%.

Conclusion:

EGFR and Cyclin D1 staining is heterogeneous and not significantly different between IP and IP with carcinoma. Low affinity to p16 and high levels of p53 may serve as markers for malignancy in this disease.

3:39PM

Quality of Life Metrics after Surgery for Sinonasal Neoplasms: Analysis of Predictive Factors

*Nathan Deckard, MD, Brian Harrow, MSII, BS, Samuel Barnett, MD, Pete Batra, MD
Dallas, TX*

Introduction:

Endoscopic resection of sinonasal and skull base neoplasms has been an important advance in the field of skull base surgery. However, there is a relative paucity of literature assessing the quality of life (QOL) of patients undergoing endoscopic tumor surgery.

Methods:

Prospective QOL data was collected using the Sino-Nasal Outcome Test (SNOT-20), Lund-Kennedy Endoscopic Score (LKE), Anterior Skull Base Questionnaire (ASBQ), and European QOL questionnaire (EQ5) in 71

patients with sinonasal and skull base tumors managed between January 2009 and August 2012. Statistical analysis was performed to identify predictive factors affecting QOL.

Results:

The mean age was 53 years and mean follow-up was 14.5 months at the time QOL data was collected. Benign and malignant tumors represented 39 (54.9%) and 32 (45.1%) cases, respectively. Twenty malignancies (62.5%) were stage T3 or T4, while 23 required postoperative chemotherapy and radiation (CRT). Factors predicting worsened postop QOL included malignant histopathology, T3 or T4 tumors, and the use of postop CRT ($p < 0.05$). The presence of an intraoperative CSF leak was only statistically significant on SNOT-20 scores. There was a strong correlation between the ASBQ, EQ5, and SNOT-20 scores ($r > 0.5$), a moderate correlation between the SNOT-20 and EQ5 ($r > 0.3$), while the LKE had only weak correlations to any of the QOL scores collected ($r < 0.3$).

Conclusions:

Patients who have undergone endoscopic resection of sinonasal tumors have quantifiable QOL results adversely affected by malignant histology, especially for stages T3 and T4 and postoperative CRT. These predictive factors may guide patient counseling in the preoperative period.

3:46PM

Sinonasal Quality of Life Outcomes after Minimally Invasive Resection of Sinonasal and Skull Base Tumors

*Brian Harrow, MSII, BS, Pete Batra, MD
Dallas, TX*

Background:

Minimally invasive endoscopic resection (MIER) has emerged as the standard for surgical management of benign and malignant sinonasal and skull base neoplasms. The objective of the present study was to assess sinonasal quality of life (QOL) and to analyze factors that impact symptomatology after surgery.

Methods:

Single-institution observational cohort study was performed on 94 patients over a 3-year period.

Results:

The mean age of 55.2 years, with male:female ratio of 1.5:1. Benign and malignant tumors were observed in 48% and 52%, respectively. The mean preoperative Sinonasal Outcome Test score (SNOT-20) for the cohort was 1.27, decreasing to 0.90 ($p = 0.002$) 6-months postoperatively. Patients with benign neoplasms had a lower mean preop SNOT-20 score at 1.11 decreasing to 0.64 ($p = 0.002$), while patients with malignant tumors had a higher mean preop SNOT-20 score of 1.42 decreasing to 1.08 ($p = 0.134$) 6 months after surgery. The SNOT-20 scores for females improved 0.53 ($p = 0.002$) compared to 0.23 ($p = 0.154$) for males at 6-months. Statistically significant sinonasal QOL improvement was noted in non-smokers (0.62, $p = 0.0006$), no prior radiation or chemotherapy (0.59, $p = 0.0029$) and no prior surgery (0.51, $p = 0.0012$). Multiple variable regression analysis demonstrated that the two strongest predictors for lack of SNOT-20 improvement to be previous history of smoking ($p < 0.05$) and prior chemoradiation ($p < 0.01$) ($R^2 = 0.24$).

Conclusion:

MIER results in overall improvement in SNOT-20 scores, with greater change being noted in patients with benign tumors and females. Prior smoking and chemoradiation strongly predict the lack of improvement in sinonasal QOL after surgery.

3:53PM

Discussion/Q&A

4:00PM

Rhinology 2013: What Does the Future Hold for Rhinology/Sinus Surgery?

Invited Speaker: David W. Kennedy, MD

Session: Clinical Practice Update: Is Your Practice Current?

*Moderators: Naveen Bhandarkar, MD,
Erin Wright, MD*

4:25PM

A Systematic Review of Non-absorbable, Absorbable and Medicated Spacers Following Endoscopic Sinus Surgery

*Xiao Zhao, MD, Aman Grewal, MD, Matthias Briel, MSc, John Lee, MD, MSc
Toronto, ON*

Background:

Middle meatal (MM) spacers may reduce adhesions following endoscopic sinus surgery (ESS). However, there is no consensus as to which materials and adjuncts are the most effective for this purpose. The primary objective of this study was to examine the effectiveness of absorbable spacers (AS) versus non-absorbable spacers (NAS) in reducing adhesions following ESS for chronic sinusitis. Secondly, we assessed steroidal versus non-steroidal MM spacers in reducing adhesions.

Methods:

Following PRISMA guidelines, a systematic review of randomized controlled trials (RCTs) was conducted and a meta-analysis on relevant outcome data was performed. Electronic search was done using OVID MEDLINE, EMBASE, Cochrane Central register of Controlled Trials, and Web of Science. Independent data extraction and evaluation was conducted.

Results:

For our primary objective, 6 RCTs were included in the systematic review. A pooled estimate of relevant trials revealed a non-significant trend favoring AS in reducing adhesion formation compared to NAS (RR=0.40, 95% CI 0.15-1.03). This trend was not apparent if NAS are left for greater than 48 hours after ESS. For our secondary objective, we identified 4 RCTs that compared steroidal versus non-steroidal spacers. While a pooled analysis could not be achieved due to inconsistent reporting of MM adhesions, two studies demonstrated significantly less adhesions in the steroidal spacer group.

Conclusions:

Comparison between NAS and AS showed that there was no significant difference in adhesion rates if NAS are used for at least 48 hours after surgery. Steroidal spacers may reduce adhesions, but more consistent data reporting is required for meta-analysis.

4:32PM

Systematic Review and Meta-analysis of Total Intravenous Anesthesia and Endoscopic Sinus Surgery

*Adam DeConde, MD, Christopher Thompson, MD, Edward Wu, MD, Jeffrey Suh, MD
Los Angeles, CA*

Objectives/Hypothesis:

Systematically review the impact of total intravenous anesthesia (TIVA) versus inhalational anesthesia (IA) on visual field, blood loss and cardiovascular parameters during endoscopic sinus surgery.

Study Design:

Systematic review and meta-analysis.

Methods:

MEDLINE (1950—October 20, 2012) was searched using a search strategy designed to include all randomized controlled trials (RCTs) that discussed TIVA, IA and endoscopic sinus surgery. An abstract search was then used to identify RCTs directly comparing TIVA and IA in endoscopic sinus surgery. All articles selected then underwent full-text review. Data on visual field scores, blood loss and cardiovascular parameters was then extracted, compared and analyzed.

Results:

There were 42 articles identified by the search strategy. Full-text review identified 9 articles that met eligibility criteria and contained extractable data. Although inconsistently reported, preoperative characteristics (Lund-Mackay scores and history of nasal polyps) were similar ($p > 0.05$) between the two groups. No difference was found between heart rate, mean arterial pressure, anesthesia time, operative time or estimated blood loss. Only 7 studies reported a visibility score, but overall favored the TIVA group ($p < 0.001$).

Conclusions:

Current evidence supporting TIVA is limited to a handful of inconsistently controlled and reported studies. Standardized grading of visibility scores and pre-operative characteristics as well as cost analysis would better establish the role of TIVA in endoscopic sinus surgery.

4:39PM

The Impact of Neo-osteogenesis on Disease Control in Chronic Rhinosinusitis after Primary Surgery

*Peta-Lee Sacks, MS, Kornkiat Snidvongs, MD, Darren Rom, Peter Earls, MD, Raymond Sacks, MD, Richard Harvey, MD
Hornsby, NSW*

Background:

Osteitic bone is a feature of chronic rhinosinusitis (CRS), potentially playing a critical role in its pathogenesis. Although seen after previous endoscopic sinus surgery (ESS), it is also a denovo feature in patients without prior interventions. Here, osteitis is associated with high tissue and serum eosinophilia. However, the impact on prognosis is unclear. This study investigates clinical and endoscopic outcomes between patients with and without osteitis after primary ESS

Methods:

Prospective cohort of previously unoperated patients with CRS undergoing ESS was performed. Sinuses were scored radiologically for osteitis using the Global Osteitis Scale and Kennedy Osteitis Scale preoperatively. Disease-specific quality-of-life (SNOT-22), nasal symptom score, endoscopic scores (Lund-Kennedy) and clinical outcomes including oral steroid use, frequency of nasal washes and infective exacerbations were collected at baseline and one year post-surgery. The presence and extent of osteitis was assessed to clinical outcome.

Results:

53 patients were included in this study (41.5% female, age 47.4 ± 13.8 yrs) of which 42.9% had features of osteitis on CT. There was no significant association between the presence nor severity of osteitis at the time of surgery and SNOT-22 or endoscopy scores. However, the presence of osteitis predicted the need for oral steroid use post-operatively ($p=0.026$). High tissue eosinophilia could not predict this alone ($p=0.55$). There was no significant relationship between osteitis and the frequency of steroid irrigations nor infective exacerbations.

Conclusion:

Osteitis in CRS is associated with the degree of eosinophilic activity but as an independent process it was associated with little impact of the disease course.

4:46PM

Aspirin Desensitization for Samter's Triad Nasal Polyposis: A Systematic Review of the Literature

Jason Xu, MSc, Leigh Sowerby, MD, Brian Rotenberg, MD, MPH
London, ON

Introduction:

Nasal polyposis in Samter's Triad is more likely to be refractory when treated by traditional approaches and have higher rates of recurrence. Aspirin desensitization may be an effective therapeutic option that targets underlying disease etiology. We conduct a systematic review of the current literature regarding aspirin desensitization treatment for nasal polyposis in patients with Samter's Triad.

Methods:

All English literature published between January 1995 and June 2012 reporting nasal outcomes following aspirin desensitization in Samter's Triad patients were eligible for inclusion. Exclusion criteria were non-investigative, non-human, and ex-vivo studies. Studies were categorized by level of evidence and evaluated for quality using the Downs and Black scale.

Results:

A total of 476 citations were retrieved and 12 studies met the criteria for analysis. Outcome measurements included self-reported symptom scores, amount of corticosteroid use, rate of revision surgery, and quantitative measurements such as rhinomanometry. Overall, most studies reported a significant improvement in symptom scores, decrease in corticosteroid use, and decrease in revision surgery. A few studies showed promising results with quantitative outcomes. However, most studies were of Level 4 evidence with small sample sizes. Rates of adverse events ranged from 12.5% to 23%.

Conclusions:

Unlike traditional treatments for nasal polyposis, aspirin desensitization targets Samter's Triad etiology rather than phenotype and has potential to be an effective therapeutic option. While the current literature shows positive results, higher quality studies are needed for conclusive benefit to be demonstrated.

4:53PM

Discussion/Q&A

5:00PM

Closing Remarks & Meeting Adjourned

President and President-Elect: Todd Kingdom, MD, Timothy L. Smith, MD, MPH

A New Paradigm for Managing Epiphora: Endoscopic Evaluation and Treatment of the Inferior Meatus

John DelGaudio, MD
Atlanta, GA USA

Objective:

Nasolacrimal duct obstruction (NLDO) is a common presenting complaint to the otolaryngologist, and frequently requires surgical intervention by dacryocystorhinostomy (DCR). Evaluation of the inferior meatus (IM) for obstructive pathology has been recently described by the author. We are the only institution performing routine office endoscopy of the IM to identify distal NLD pathology, and have reported our experience with directed endoscopic treatment of the IM with excellent results. We will present our diagnostic and treatment paradigm for epiphora.

Methods:

Prospectively treated. Adult patients presenting to the author's tertiary rhinology practice with epiphora were routinely evaluated for pathology at the IM with office nasal endoscopy. Endoscopic findings and surgical outcomes were reviewed.

Results:

The majority of evaluated patients had pathology at the IM, including NLD orifice cysts, mucosal hypertrophy at Hasner's valve, obstructing polypoid degeneration of inferior turbinates, dacryoliths, and scar tissue. Endoscopic treatment of the specific obstructive pathologies in the IM are less invasive and as effective (>90%) as DCR.

Conclusions:

We have found that distal NLDO is found in most patients with epiphora and can be attributed to a number of pathologies in the IM. These pathologies are very amenable to a minimally invasive endoscopic treatment. We recommend endoscopic evaluation of the IM and the NLD orifice in patients with epiphora as part of the standard workup. We present our diagnostic and treatment paradigm for patients with epiphora.

A One-year Comprehensive Study: The Microbiology and Antimicrobial Resistance Patterns of Sinus Cultures

Anne Cosgriff, MD, Edward Hepworth, MD,
Cutler Jeffrey, MD, James Small, MD,
Christopher Lind, BS
Denver, Colorado USA

Introduction:

This study examined the bacteriology of sinus cultures in a rhinology focused practice. A large scale antibiogram of sensitivity and resistance patterns to commonly tested antibiotics was developed.

Methods:

A retrospective chart review of 274 patients who underwent 491 cultures for either acute or chronic sinusitis within a one year period from 2010 to 2011 was performed. Per lab protocol, cultures were tested against an appropriate subset of 40 antibiotics to determine antibiotic sensitivity and resistance patterns.

Results:

87.37% (429 of 491) of cultures grew at least one organism. Of the 253 patients who had such positive growth, the average age at culture was 53.28 years. 113 were male, and 140 were female. In this population, 648 bacteria were isolated. 224 (88.5%) of patients had undergone past sinus surgery. 76 distinct bacterial species were identified. The most frequent isolates were: *Staphylococcus aureus* (99 were methicillin-sensitive and 36 were methicillin-resistant), coagulase negative *Staphylococcus* species, not otherwise designated (75), *Staphylococcus epidermidis* (66), *Pseudomonas aeruginosa* (42), *Diphtheroids* (38), *Streptococcus pneumoniae* (37), alpha hemolytic *Streptococcus*, not otherwise designated (31), *Moraxella branhamella catarrhalis* (30), *Haemophilus influenzae* (30), *Escherichia coli* (11), and *Streptococcus viridans* (11). These isolates accounted for 78.09% of the bacteria cultured (506/648).

Conclusion:

While 76 bacterial species were identified, the most commonly occurring species included *Staphylococcus*, *Pseudomonas*, *Diphtheroids*, and *Streptococcus*. To assist in caring for future patients in our practice, an antibiogram of one year of cultures was developed.

A Pilot, Open-label Study to Assess the Safety and Performance of a Maxillary Sinus Ostium Self-Dilation Device

*Iain Hathorn, MD, Al-Rahim Habib, BSc, Rachele Dar Santos, BSc, Eng Cern Gan, MD Amin Javer, MD
Vancouver, BC Canada*

Introduction:

The maxillary sinus ostium (MSO) is commonly obstructed in patients suffering from Chronic Rhinosinusitis (CRS) and surgery may be required to reestablish drainage and ventilation. Recently, a novel osmotic self-dilating expansion device has been developed for use in the office to expand sinonasal ostia without surgical resection. This device has demonstrated safety and successful dilation of sinonasal ostia in an ovine model.

Objective:

To conduct a pilot study to determine the safety and feasibility of a MSO self-dilating expansion device in human subjects.

Methods:

Primary CRS patients presenting with chronic maxillary sinus inflammation requiring FESS were enrolled into the study. Each MSO was evaluated prior to surgery to determine suitability of placement. The device was inserted at the start of surgery and removed after 60 minutes. Endoscopic evaluation for patency was performed immediately after removal, at 6 days, 1 month, and 3 months postoperatively. Adverse events were recorded at each visit.

Results:

Ten patients (n=18 MSO) were treated in this series. 17 (94%) devices remained inserted for 60 minutes and achieved a mean dilation to 4.8 ± 0.5mm. Light bleeding during placement was reported in 12 (67%) cases. No adverse events occurred during insertion, removal or throughout the postoperative recovery. Presently 8 MSO have been evaluated at 3 months post insertion of which 7 (88%) have been confirmed patent.

Conclusion:

Placement of a novel osmotic self-dilating expansion device in human MSO is safe, achievable and effective.

A Rare Case of Sinonasal Hemangiopericytoma: Case Report and Review of Literature

*Jonathan Simmonds, BA, Elie Rebeiz, MD
Boston, MA, USA*

Hemangiopericytomas are soft tissue tumors composed of pericytic cells that are characterized by their, "staghorn" vascular branching and their variable clinical presentation. Fifteen to 25% of all HPC occur in the head and neck, with only 5% found in the nose or paranasal sinuses. Sinonasal hemangiopericytoma (SNHPC) is considered distinct from its soft tissue counterpart - the former showing a more uniform cellular organization, has convincing pericytic differentiation and is associated with a far better prognosis. With less than 200 cases of SNHPC reported in the literature, only limited assumptions can be made about this rare tumor.

Here, we present another case of SNHPC in a 42-year-old Chinese woman who presented with a 6-week history of epistaxis from the left side of her nose and a 1-year history of anosmia. Nasal endoscopy revealed a pulsatile, vascular mass in the left middle meatus. CT and MRI studies show an enhancing mass in the left nasal cavity, with thinning and erosion of the left cribriform plate. Endoscopic biopsy showed a Spindle Cell neoplasm consistent with Hemangiopericytoma that stained positively VEGF, NSE, factor XIIIa, S-100 protein, and CD34, and negative for actin, desmin, CD31, and pankeratin. Embolization of the sphenopalatine and labial artery as well as neoadjuvant radiation therapy was performed to shrink the tumor before complete endoscopic resection was performed with negative septal and posterior ethmoidal margins with 250cc of blood loss. The patient remained free of disease on her one-year follow up

Accessory Tragus in the Nasopharynx: Case Report, Literature Review, and Discussion of Embryologic Development

*Soroush Zaghi, MD, Leenoy Hendizadeh, BS, Dana Haydel, MD, Jeffrey Koempel, MD
Los Angeles, CA, USA*

Introduction:

An accessory tragus may result from the aberrant development of the first branchial arch between the third and seventh weeks of intrauterine life. Accessory tragi commonly present in the pre-auricular region near the primary tragus, but they may also present in other more unusual locations. Here we present the first known case of a congenital accessory tragus that was found in the nasopharynx.

Method:

Case report, literature review, and discussion of embryologic development.

Case:

A nine year-old-girl presented with complaints of nasal airway obstruction, mouth breathing, and loud snoring. On exam, an obvious mass, covered with what appeared to be normal mucosa, was noted extending from the nasopharynx into the oropharynx. MRI revealed a 1.4 cm hyperintense, pedunculated, polypoid lesion adjacent to the right pharyngeal wall near the level of the palate. The patient underwent endoscopic resection in the OR. Pathologic analysis confirmed the mass as a rudimentary accessory tragus.

Discussion:

Accessory tragi occur with a frequency of 1 to 10 per 1000 births and are usually isolated anomalies. Although they most commonly occur in the pre-auricular region, accessory tragi may also occur anywhere along the lateral to medial migration course of embryologic remnants from the first branchial arch. Other atypical locations for accessory tragi include attached to the glabella, nasal vestibule, malleus, and Eustachian tube.

Conclusion:

We present the first described case of accessory tragus in the nasopharynx and provide an educational module to help providers understand the clinical relevance of migration patterns in embryologic development.

Ambient Warming of Nasal Irrigation Solutions: Implications for Safe Topical Drug Delivery and Patient Compliance

*Janalee Holmes, MD, Timothy Haffey, MD, Troy Woodard, MD, Raj Sindwani, MD
Cleveland, OH USA*

Background:

Topical drug delivery for chronic rhinosinusitis using nasal irrigation or nebulization is gaining popularity. Paranasal sinus exostoses (PSE) appears to be a complication of cold nasal irrigations, akin to exostoses in the ear canal. Many compounded irrigation solutions require refrigeration, and patients are advised to irrigate with solutions at room temperature. However, the time it takes for common irrigants to adequately warm is unknown.

Methods:

Standard formulations of common sinonasal medications and saline were tested. A non-contact laser thermometer was used to record temperatures within the refrigerator, and at standard intervals until the solutions reached ambient temperature. A NasoNeb device was also used and temperatures pre and post-nebulization were recorded.

Results:

Ambient temperature was 73.5 °F. The average refrigerated temperature was 43.5 °F. After 45 and 60 minutes of passive warming, the average temperature of the solutions was 59.8 °F and 62.5 °F, respectively. It took 120 minutes for these solutions to approach ambient temperature. The rate of warming of the various solutions was similar. When solutions were nebulized directly out of the refrigerator, they warmed from 40.5 °F to 61.7 °F on average.

Conclusion:

Although the critical temperature associated with PSE formation is unknown, it seems prudent to advise patients to leave refrigerated irrigation solutions at room temperature for at least 45 minutes prior to use, or to actively warm them. The protracted time taken for ambient warming may impact patient compliance for using solutions at room temperature. Temperature appears less of an issue with nebulized drug delivery.

Analysis of 1200 Endoscopic Draf IIa Frontal Sinusotomies: Intraoperative Findings and Results

Allison Fry, BS, Wade Han, MD
Orlando, FL USA

Frontal sinus outflow stenosis is common following functional endoscopic sinus surgery (FESS). Anterior ethmoidectomy in patients with a hypercellular frontoethmoid region may lead to iatrogenic adhesion or synechia obstruction of an otherwise patent but narrow frontal sinus drainage pathway. Endoscopic Draf IIa procedure, with removal of all frontoethmoid cells, is one of the techniques to improve frontal outflow patency. In this study, we retrospectively reviewed 1200 consecutive completed and attempted Draf IIa frontal sinusotomies performed at a community based general otolaryngologic practice during 2010-2012. Intraoperative findings were analyzed from operative notes and still images taken with a 70 degree rigid nasendoscope at the end of the frontal surgery. When available, postoperative symptom scores and postoperative angled endoscopic findings of frontal sinusotomies were tabulated. Over 95% of post-Draf IIa patients are frontal symptom free with a follow up period of at least 6 months. When indicated postoperatively, in office 70 degree endoscopic examination and sinus CT images generally showed patent frontal sinus outflow tracts. Routine Endoscopic Draf IIa integrated with FESS is a viable approach with a low incidence of post operative frontal drainage obstruction and subjective symptoms.

Cemento-Ossifying Fibroma of the Skull Base

Toby Steele, MD, Edward Strong, MD
Sacramento, California USA

Introduction:

Cemento-Ossifying fibroma(COF) is a rare benign osseous lesion originating from the craniofacial skeleton. While the majority of these lesions arise within the mandible, less common sites include the maxilla, paranasal sinuses, orbit and skull base. With fewer than 100 reported cases in the literature, we present a case of COF arising from the skull base.

Case Description:

A 20 year old male presented in January of 2012 with a one year history of progressive left orbital pressure, headache, and proptosis. Physical examination revealed exophthalmos and hypophthalmos. Extraocular movements were intact x 6 and facial animation and sensation were normal. CT revealed 4.0 x 3.4 x 2.3 cm homogeneous mass arising within the roof of the left orbit. The mass had a well-circumscribed thin rim and contained a few coarse calcifications.

After consultation with the Neurosurgical team, the patient underwent a bicoronal approach for a left frontal craniotomy, tumor resection, and reconstruction with a pericranial flap and contoured MESH implant. The patient's post-operative course was uneventful, and post-operative CT confirmed complete tumor resection with satisfactory orbital roof reconstruction. Histological sections showed proliferation of spindle cells with bland nuclei and production of round to oval cemento-ossifying material. There were no malignant cells identified.

Discussion:

COF is a rare benign osseous lesion that often represents a diagnostic dilemma for the surgeon and pathologist. The tumor may present with cosmetic deformity, infection, proptosis, sinonasal obstruction, and rarely intracranial complications. Complete surgical resection is necessary to prevent recurrence and surveillance imaging is recommended.

Central Skull Base Osteomyelitis: An Emerging Clinical Entity

Andrew Johnson, MD, Pete Batra, MD
Dallas, TX USA

Background:

Skull base osteomyelitis (SBO) most commonly results as a complication of otitis externa in diabetic patients. Central or atypical presentations, unrelated to aural pathology, have been documented, though restricted to small patient series or case reports. The current study systematically analyzed the literature to construct the clinical profile of this rare but potentially fatal entity.

Methods:

The Medline (Ovid) database was searched for all published cases of central SBO. Statistical analysis was performed to identify trends affecting overall outcomes or differences in treatment.

Results:

A total of 43 cases were included with mean age of 52 years and male:female ratio of 2.3:1. The most common cranial nerve palsies included VI (33%) followed by IX (30%) and X (30%). *Staphylococcus aureus* (21%) and *P. aeruginosa* (21%) were the two most common causative pathogens. The mean duration of antimicrobial therapy was 21 weeks, with 70% requiring IV antibiotics for a mean duration of 6.9 weeks. Nineteen of 43 patients (44%) required adjunct surgical debridement. The overall mortality was 9%, with additional 34% experiencing disease-related complications. Women were more likely than men to require multiple courses of therapy (46% vs 10%, $p = .01$). History of cardiovascular disease correlated with longer duration of therapy (54.8 vs 14.3 weeks, $p = .02$).

Conclusion:

Osteomyelitis of the central skull base remains a rare, highly morbid disease that poses significant challenges for timely and accurate diagnosis and therapy. Females and those with pre-existing cardiovascular disease may require longer courses of therapy to optimize care.

Cerebrospinal Fluid Leak - a Novel Mechanism of Injury to a Well Known Complication of Septorhinoplasty

Mamie Higgins, BA, Abib Agbetoba, MD, Kevin Yao, MD, FACS, Michael Shohet, MD, FACS
Buffalo, New York USA

Background:

Septoplasty represents one of the most commonly performed rhinologic procedures in otolaryngology. Associated complications have been well documented in literature with cerebrospinal fluid (CSF) leak representing one of the most rare and potentially fatal outcomes. We present a case report of an iatrogenic CSF leak occurring in the sphenoid sinus following a septorhinoplasty procedure as well as a review of the literature on iatrogenic CSF leaks.

Methods:

Case report and literature review. The patient's medical records, computerized tomography (CT) imaging, magnetic resonance imaging (MRI), and original operative report were reviewed.

Results:

A 48 year-old female underwent septorhinoplasty at an outside facility complicated by postoperative CSF rhinorrhea two weeks following the procedure. Given progression of ventriculomegaly, hydrocephalus, and persistence of an anterior sellar floor defect, the patient ultimately underwent endoscopic exploration and repair. Intraoperatively pulsatile CSF was immediately visualized from a defect at the face of the sphenoid just medial to the natural ostium. Upon entry into the sphenoid sinus, defect of the rostrum was noted and a 1 cm defect was easily exposed at the sellar floor. A repair with pedicled posterior septal flap and free middle turbinate osteomucoperiosteal graft and subsequent CSF shunting resulted in clinical resolution.

Conclusion:

CSF leak following surgical procedures of the nasal septum represent rare and potentially fatal complications. The case described represents a unique case of iatrogenic CSF leak occurring at the anterior sellar floor following a septorhinoplasty operation. Potential mechanisms and treatment options are detailed.

Chronic Granulomatous Invasive Fungal Sinusitis With Intracranial Extension-A Case Report and Review of the Literature

Ashleigh Halderman, MD, Raj Sindwani, MD
Cleveland, OH USA

Introduction:

Chronic granulomatous invasive fungal sinusitis (CGIFS) is a rare clinical entity in North America. There is no consensus in the literature on the ideal method of surgical and/or medical management of CGIFS. Traditionally, aggressive surgical resection and long term IV Amphotericin B have been used. We present a rare case in which a patient with extensive orbital and intracranial CGIFS was managed successfully with a conservative approach.

Methods:

Case report and review of the literature.

Results: A 48 year old African American male presented with unilateral headache, proptosis, papilledema, and facial paresthesias. Imaging revealed an infiltrative process with extensive intracranial and orbital involvement. Biopsy showed fungal elements associated with a granulomatous reaction without angioinvasion or significant necrosis consistent with the diagnosis of CGIFS. *Aspergillus fumigatus* was cultured. Aggressive surgical resection would have resulted in significant morbidity and possible mortality. Therefore, the decision was made to manage with conservative surgical debridement and long term oral Voriconazole. The patient's symptoms and exam findings slowly resolved and he had almost complete resolution of disease on MRI after 8 months of therapy.

Conclusion:

There is no consensus on the ideal management of CGIFS, and treatment should be individualized. This case and the recent literature support a more conservative surgical approach in some patients with extensive CGIFS. The use of oral Voriconazole is effective and has significant advantages over more toxic and intravenously administered agents.

Clinical and Anatomic Characteristics of Patients with Complications of Acute Rhinosinusitis

Ilya Likhтеров, MD, Megan Durr, MD
Cathleen Kenary, BS, Steven Pletcher, MD
San Francisco, CA USA

Background:

Acute rhinosinusitis is a common disorder with rare yet serious complications. Risk factors for the development of orbital and intracranial complications of acute sinusitis remain largely unknown. The purpose of this study is to evaluate whether increased aeration of the sinuses is associated with developing complications of sinusitis. The frontal sinus volume is used as a metric for overall sinus aeration.

Methods:

This is a retrospective comparison of thirty patients (17 pediatric and 13 adult) treated at an academic medical center for complications of acute rhinosinusitis with thirty age and sex matched controls. Frontal sinus volumes were calculated from computer tomography scans using commercially-available software.

Results:

Pediatric patient with complications of sinusitis had increased aeration of their frontal sinuses compared to controls ($p < 0.05$). This difference remained significant when using disease-matched (sinusitis without complications) controls. No difference in frontal sinus volumes was found in adult patients with complications of sinusitis when compared to age and sex-matched controls.

Conclusion:

Anatomic variations of sinus aeration are associated with the development of complications of acute sinusitis in the pediatric population. This study demonstrates a specific association of frontal sinus volume with complications of acute sinusitis which may reflect an association of sinus hyper-aeration to the development of complications.

Clinical and Pathologic Characterization of Nasal Abuse of Opioid-acetaminophen Medications

*Peter Vosler, MD, PhD, Stella Lee, MD, Jorge Contreras, MD, Eric Wang, MD, Barry Schaitkin, MD, Berrylin Ferguson, MD
Pittsburgh, PA USA*

Background:

The nasal abuse of crushed opioids and acetaminophen is a growing problem, frequently leading to nasal necrosis and fungal colonization. Failure to recognize the underlying cause of fungal colonization may lead to inappropriate prolonged antifungal therapy, as has been advocated by other studies.

Objective:

To increase awareness of the typical presentation of intranasal opioid-acetaminophen abuse, and outline optimal therapy.

Methods:

Retrospective case series and literature review.

Results:

Seven adults ranging in age from 23 to 46 years seen between January to October of 2012 with nasal complaints were subsequently discovered to be using intranasal opioid-acetaminophen drugs. All patients presented with nasal pain. Intranasal endoscopic exam showed fibrinous debris and tissue necrosis in all patients. Septal perforation was seen in 6/7 (85.7%) patients. Pathology/culture revealed the presence of fungus in 6/7 (85.7%) of patients. Unlike previous reports, no tissue invasion by fungus was found. Systemic antifungals and intranasal antifungal irrigations were started in 3 patients without clear benefit. Polarizable material was seen in 4/7 (57.1%) of the pathology specimens. Patients who abstained from intranasal drug use with concomitant repeated debridement demonstrated the greatest improvement.

Conclusion:

Intranasal opioid-acetaminophen abuse causes nasal pain, tissue necrosis, high risk of septal perforation, and fungal colonization. Antifungal therapy was of no benefit in the current series of patients in contrast to previous reports. Therapy should include debridement, and most importantly, cessation of intranasal opioids-acetaminophen, which often requires drug rehabilitation.

Clinical Manifestations of Granulomatosis with Polyangiitis (GPA: Wegener's granulomatosis) in the Upper Respiratory Tracts by Otolaryngologists of Japan

*Yasuaki Harabuchi, MD, PhD, Kan Kishibe, MD, PhD, Yuki Komabayashi, MD
Asahikawa, Hokkaido Japan*

Patients enrolled in this study consisted of total 91 patients with GPA who were dealt by otolaryngology in Japan. Of all 91 patients, 56% patients suffered in upper respiratory tract (URT) alone. As the findings of PR3-ANCA, histology and initial diagnosis, of 40 patients involving sites other than URT, 64% and 73% were positive for PR3-ANCA and histology, respectively. On the other hand, of 51 patients involving URT alone, only 49% and 31% were positive for PR3-ANCA and histology, respectively. With regard to diagnosis, definitive and probable diagnoses were done in 78% and 20% patients involving sites other than URT, respectively. On the other hand, definitive and probable diagnoses were done in only 22% and 37% patients involving URT alone, respectively. Forty one percents were inapplicable to diagnostic criteria of Japan. Of 21 patients who were inapplicable to the diagnostic criteria, 13 (62%) patients developed additional symptoms and signs during observation period, and then they got into the diagnostic criteria in Japan. In these patients, MPO-ANCA positive cases were found in 8 patients and 3 patients have equal and more than 2 sub-lesions in the upper respiratory tracts. If the diagnostic criteria includes the cases with MPO-ANCA(+) and 2 lesions of URT, of 21 patients without criteria 11 patients entered the criteria, then diagnostic rate will increase to 86% from 59% even though limited form. Thus about 60% of the patients with symptoms of upper respiratory tract alone did not satisfy the Japanese diagnostic criteria at the initial visit.

Clinical Outcome of Middle Turbinate Resection During Endoscopic Sinus Surgery: A Systematic Review

*Garret Choby, MD, Candace Hobson, MD, Stella Lee, MD, Eric Wang, MD
Pittsburgh, PA USA*

Introduction:

The middle turbinate (MT) is often preserved during endoscopic sinus surgery (ESS) in an effort to maintain nasal physiology and as a useful anatomic landmark. However, resection is performed in select cases due to involvement of the MT in the inflammatory process, obstruction, or instability. Controversy exists regarding the effects of middle turbinate resection and the benefits of preservation. The purpose of this systematic review is to evaluate the evidence regarding middle turbinate resection in patients undergoing ESS for chronic rhinosinusitis (CRS).

Methods:

A systematic review of the literature was performed for publications examining clinical outcomes of MT resection during ESS performed for CRS. Inclusion criteria included adult patient population (≥ 18 years old), history of CRS, level 2B or higher evidence and defined clinical outcome: synechiae, bleeding, revision rates, olfaction, and symptom scores.

Results:

6 articles met inclusion criteria and were included in this review. There were a total of 507 patients studied over 1 prospective randomized controlled trial, 2 prospective non-controlled trials and 3 prospective observational studies. Although the studies are quite heterogeneous, they suggest that MT resection does not significantly adversely affect patient quality of life compared to MT preservation and may benefit visualization during post-operative debridement.

Conclusions:

Due to the small number of patients and heterogeneity of data reported in the studies evaluated, the clinical outcome of middle turbinate resection remains unclear. In the small number of studies meeting inclusion criteria, it does not appear that MT resection negatively impacts clinical outcome following ESS.

Clinical Outcome of the use of Nasal Packing Following Endoscopic Sinus Surgery for Chronic Rhinosinusitis: A Systematic Review and Meta-analysis

*Candace Hobson, MD, Garrett Choby, MD, Stella Lee, MD, Eric Wang, MD
Pittsburgh, PA USA*

Introduction:

The objective of this systematic review was to evaluate the outcomes of patients who underwent packing of the middle meatus at the completion of endoscopic sinus surgery (ESS) for chronic rhinosinusitis (CRS).

Methods:

Prospective randomized controlled studies of patients who underwent packing of the middle meatus at the completion of ESS were reviewed and included for meta-analysis. Outcome measures extracted and analyzed included rates of synechiae, middle meatal patency, presence of inflammation, and quality of life measures (nasal obstruction, facial pain, headache). We compared the use of packing versus no packing and the resulting effect on surgical outcomes.

Results:

Seventeen prospective, randomized, controlled trials met inclusion criteria resulting in a total of 865 subjects. Middle meatal packing of any type, including absorbable and non-absorbable, was associated with a decreased risk of synechiae formation (RR = 0.544); however, this did not achieve statistical significance ($p=0.052$) on meta-analysis. The data for middle meatal patency, nasal obstruction, inflammation, and facial pain/headache were too heterogeneous to be analyzed for statistical significance.

Conclusions:

This systematic review reveals that nasal packing does not significantly affect the risk of adhesions after ESS. Data evaluating the surgical outcomes of middle meatal patency, nasal obstruction, inflammation, and facial pain/headache were inconsistently measured in the studies included, and were thus not suitable for meta-analysis.

Clinicodemographic and Hospital Characteristics Associated with the Presentation of Acute Bacterial Sinusitis Complications in Adults

Ahmad Sedaghat, MD, PhD, Stacey Gray, MD, Stacey Ishman, MD, MPH
Boston, MA USA

Background:

Acute rhinosinusitis (ARS) is a common complication of upper respiratory infections. Despite antibiotic therapy, some cases of ARS will become complicated by orbital or intracranial involvement.

Methods:

Cross-sectional analysis of the 2008 Nationwide Emergency Department Sample (NEDS) database using all patients older than eighteen years old with a diagnosis of ARS. Factors associated with ARS complications such as patient characteristics (age, gender, comorbid conditions, family income level and insurance type) and hospital-specific characteristics (geographic location, urban designation and teaching status) were identified.

Results:

564,662 patients were included, 551 (0.1%) of whom were diagnosed with an orbital or intracranial complication of ARS. Male gender (odds ratio [OR]=1.84, $P<0.001$), a concomitant diagnosis of chronic rhinosinusitis (CRS) (OR=8.32, $P<0.001$) or comorbidities including HIV infection, lymphomas, leukemias, cystic fibrosis, and/or immune disorders (OR=2.27, $P=0.024$) as well as presentation to metropolitan teaching (OR=2.05, $P<0.001$) and non-teaching (OR=6.53, $P<0.001$) hospitals were associated with complications. Although patients from the lowest income groups were least associated with ARS complications, no particular socioeconomic trend was observed in subgroup analysis of patients with periorbital cellulitis, orbital complications or intracranial complications. The only consistent association with all subgroups of ARS complications was a concomitant diagnosis of CRS.

Conclusions:

Complications of ARS in adults are associated with CRS as well as comorbidities including cystic fibrosis or immunodeficiencies. The index of suspicion for ARS complications should be raised in these patients to improve outcomes through timely diagnosis and treatment, in particular in a patient population that may not tolerate such illness.

Differences in Skull Base Thickness in Patients with Spontaneous CSF Leaks

Alkis Psaltis, MD, PhD, Lewis Overton, BS, Nessa Fox, BS, Rodney Schlosser, MD
Charleston, SC USA

Aim:

Spontaneous cerebrospinal fluid (SCSF) leaks are increasingly recognized as one of the most common etiologies of CSF leak. They are associated with increased intracranial pressures and often present with unique clinical and radiological features. This study evaluates the skull base thickness in SCSF patients.

Methods:

CT scans of 95 patients were evaluated by 2 blinded observers. The anterior skull base bony thickness was compared at consistent locations in different planes for 32 patients with SCSF leaks, 26 patients with traumatic leaks and 37 race-matched controls.

Results:

SCSF were most common in the sphenoid in African Americans and in the ethmoid roof in whites. The sella was significantly larger and thinner in African Americans ($p<0.05$). Irrespective of race, patients with SCSF leaks had larger sellas and thinner skull bases in the lateral lamella and ethmoid roof regions, measured coronally, and in the ethmoid roof and sphenoid planum regions, measured sagittally ($p<0.05$).

Conclusion:

Patients with spontaneous CSF leaks have thinner skull bases in several locations when compared to patients with traumatic leaks and healthy controls. Whether this thinner skull base predisposes to spontaneous CSF leaks or is a consequence of the underlying increased CSF pressure remains unknown.

Distal Spontaneous Pseudomeningoceles of the Skull Base

*Seth Lieberman, MD, Roy Casiano, MD
Miami, FL USA*

Introduction:

A pseudomeningocele is a collection of cerebrospinal fluid (CSF) in the soft tissue that is not surrounded by arachnoid membranes. The following represents the first reported cases of nasopharyngeal pseudomeningoceles tracking submucosally to the sphenoid sinus.

Methods:

Case series

Results:

Two examples of distant spontaneous pseudomeningoceles of the skull base are presented. In one case, the CSF leak was contained behind the mucosa of the Eustachian tube. At the time of surgery, the patient was not having active CSF rhinorrhea. With the aid of intrathecal fluorescein, the leak was tracked back to the vidian canal and sphenoid sinus. A nasoseptal flap was used for a repair. In the other case, the patient was actively leaking at the time of surgery. The leak was found on the dorsum of the soft palate. The fistula was tracked submucosally to the lateral nasopharyngeal wall and ultimately to the vidian canal. This was repaired with an underlay bone graft. Both patients had elevated CSF pressures and were managed with a shunt. Both patients had complicated courses of their disease with multiple episodes of preoperative and postoperative meningitis.

Conclusion:

Spontaneous CSF leaks from the skull base can track submucosally to areas distant from the skull base. These pseudomeningoceles may be associated with elevated intracranial pressure and, though rare, may be an underrecognized entity.

Dysgeusia, Dysosmia, Depression, and Drugs in Chemosensory Disorders

*Michael Stevens, MD
Salt Lake City, UT USA*

Introduction:

Dysgeusia and dysosmia can impact quality of life, but also cause malnutrition.

Materials and Methods:

Forty five patients with dysgeusia and or dysosmia were followed prospectively for up to 4 years to observe their outcome. Depression was present in 46.6% of patients. The etiology of their dysgeusia and or dysosmia included drugs in 8, viral in 7, recurrent sinus infections in 3, 2 each due to sinus surgery, diabetes mellitus, tonsillectomy, and chemotherapy, and 1 each with head injury, graves disease, depression, brain surgery, and multiple causes. There were 10 whose etiology could not be determined. Each patient was given a smell and taste questionnaire, nasal endoscopy, and a CT or MRI scan. A smell identification Test along with taste testing was done on each patient. A screening neurological exam was done along with blood tests on patients whose problem was of unknown cause. Zinc sulfate, sertraline hydrochloride, and gabapentin were offered to patients that did not respond to stopping or changing drugs that might be the cause of their symptoms.

Results:

Eight of twenty six patients were cured by changing or stopping current medication. Six of sixteen that took Zinc, five of eleven that took Zoloft, and 2 of 6 who took Gabapentin had symptoms eliminated. There were 16 whose symptoms resolved spontaneously.

Conclusion:

Thirty five of forty five or 77.7% of patients had complete resolution(25) or dramatic improvement(10) of their symptoms. Therefore, the outlook for these patients is good.

Endoscopic Drainage of an Epidural Abscess from Sphenoid Sinusitis in a 3-Year Old Child

Caroline Kolb, MD, Benjamin Cable, MD, Stacey Wolfe, MD
Honolulu, HI USA

Introduction:

Epidural abscess is an infrequent complication of pediatric sinusitis in patients younger than seven years old due to the later development of the sphenoid and frontal sinuses. Abscesses in teenagers in the frontal region secondary to frontal sinusitis are most commonly reported.

Methods:

We present a rare case of a 3-year old male presenting with mental status changes, fever, and lethargy. Imaging confirmed sphenoid sinusitis culminating in an epidural abscess of the middle cranial fossa. A transsphenoidal approach was used to perform endoscopic drainage of the epidural abscess.

Results:

Endoscopic transsphenoidal drainage of the epidural abscess was successfully performed without the need for craniotomy or other neurosurgical interventions. We discuss the technique and provide a video complement to illustrate the procedure. We review the literature on the success of endoscopic drainage of epidural abscesses as complications of pediatric sinusitis.

Conclusion:

This case demonstrates the feasibility of endoscopic transsphenoidal drainage of a middle cranial fossa epidural abscess. This approach may offer a safe and effective alternative to a high-risk craniotomy in selected cases.

Endoscopic Orbitotomy: Indications and Outcomes

Janalee Holmes, MD, Divya Gumber, BS, Jastin Antisdell, MD, Raj Sindwani, MD
Cleveland, OH USA

Objectives:

Performing surgery on the orbit through minimally invasive approaches has gained favor. Although the orbit is most commonly approached endoscopically in the management of Graves' orbitopathy via orbital decompression, a variety of other indications are emerging which use similar techniques.

Methods:

CPT codes for endoscopic orbital decompression performed between 2002 and 2011 at two major centers were retrospectively reviewed. Patients with a diagnosis of Graves' disease or orbital complication of sinusitis were excluded. Presenting symptoms, operative technique, lesion location, pathology, and postoperative complications were recorded.

Results: During the study period a total of 126 patients had orbital decompressions, with 26 patients meeting inclusion criteria. The majority of patients (17/26) were men, and the average age was 57 (14-88) years. Seventeen patients had solitary orbital lesions isolated to the apex. Nine had sinonasal lesions that directly involved the lamina papyracea and required resection. Diverse etiologies were encountered: including benign (34.6%), malignant (50%), and inflammatory (7.7%). Obtaining a pathologic diagnosis was successful endoscopically in all but two (7.7%) patients. Both of these patients had lesions that were predominantly lateral to the optic nerve. Postoperatively one elderly patient suffered a myocardial infarction. No cases of CSF leak, hemorrhage, or new-onset blindness were experienced.

Conclusion:

Accessing the orbit endoscopically enables surgeons to safely and effectively biopsy and manage a variety of pathologies involving the medial orbit and apex. This approach offers marked advantages over external techniques including avoidance of retraction on the optic nerve, superior visualization, and the avoidance of a facial scar.

Evaluation of Skull Base Reconstruction and Sinonasal Disease Following Endoscopic Skull Base Surgery with Radiation Therapy

*Cristine Klatt-Cromwell, MD, Travis Newberry, MD, Matthew Ewend, MD, Brent Senior, MD, Charles Ebert, MD, Adam Zanation, MD
Chapel Hill, NC USA*

Background:

Endoscopic skull-base surgery and vascularized reconstructions has advanced and become applicable to sinonasal/skull base cancers and invasive benign tumors. Adjuvant radiation for invasive processes offers significant clinical benefit for tumor control. The aim of this study is to assess changes to nasoseptal flap (NSF) reconstructions and sinus mucosa after endoscopic skull-base surgery with radiation.

Methods:

Patients with endoscopic skull-base and dural resection, NSF reconstruction and radiation with post-therapy MRIs were identified over a four-year period. Post-therapy scans were evaluated for enhancement and contracture of NSF and sinus disease evaluated via Lund-Mackay scoring. Vascularity was compared to inferior turbinate mucosa via intrascan pixilated signal intensity.

Results:

Sixteen patients, 10 males, 6 females, ages 10-76, were identified. Nine of sixteen surgeries were for malignancies and all reconstructions demonstrated initial vascularization. Five patients (31.6%) had congested uptake in NSF following radiation, but all were vascularized. Of these, two demonstrated congestion prior to radiation therapy. Average contracture was minimal at 0.03mm. Twelve patients demonstrated mucosal thickening in the sinuses (average LM = 1.93), with 8 demonstrating primarily sphenoid disease. One patient had repeat surgery for vestibular stenosis. No patients reported sinus symptoms that required repeat surgery. No flap deaths or CSF leaks were noted.

Conclusion:

Endoscopic surgery with NSF reconstruction followed by radiation is safe without need for revision sinus surgery or CSF leak repair. NSF reconstruction after radiation maintain vascularity with minimal contraction. This population demonstrates mucosal thickening most commonly in the sphenoid sinus following radiation, however do not require revision surgery.

Frontal Sinus Mucocele as a Late Complication of Frontal Bossing Reduction

*Jiovani Visaya, MD, Nicole Hsu, MD, Rita Roure, MD, Aaron Pearlman, MD
New York, NY USA*

Introduction:

Supraorbital prominence (frontal bossing) is a relatively rare cosmetic deformity associated with hypertrophy of the frontal sinus. Various surgical techniques have been described to address this deformity, including bone contouring/abrasion, setback osteotomies, and inversion of the anterior table. Although such techniques may potentially disrupt the underlying mucosa and interfere with normal sinus function, their long-term complications have not been well described.

Methods:

Case report

Results:

A 38-year-old gentleman presented to the emergency department with intermittent right frontal headache for several years. He suffered from body dysmorphic disorder and had undergone frontal bossing reduction in the Dominican Republic 18 years ago. Physical examination revealed flattening of the forehead with a well-healed bicoronal incision. On nasal endoscopy, polypoid disease was present in both nasal cavities and obstructed visualization of the middle turbinates. Sinus imaging revealed bilateral anterior table defects overlying the frontal sinuses, with opacification of the right frontal, ethmoid, and maxillary sinuses. Despite completing an oral regimen of antibiotics and steroids, repeat imaging demonstrated a right frontal mucocele with persistent right ethmoid and maxillary sinus disease.

Conclusion:

Frontal mucocele may occur as a late complication of frontal bossing reduction. When performing surgical correction of supraorbital prominence, care should be taken to maintain the integrity of the frontal sinus mucosa in an effort to prevent mucocele formation.

Impact of Intraoperative Hydrodebrider Treatment on Postoperative Sinonasal Inflammation

Oswaldo Henriquez, MD, Jennifer Mulligan, PhD, Alkis Psaltis, MD, Eric Wang, MD, Shaun Nguyen, MD, Rodney Schlosser, MD Charleston, SC USA

Introduction:

The impact of intraoperative hydrodebrider sinus irrigation (HSI) during endoscopic sinus surgery (ESS) upon postoperative inflammation, endoscopy and patient reported outcomes has not been studied.

Methods:

Twelve patients with symmetric chronic rhinosinusitis were prospectively randomized to HSI on one side after undergoing ESS. The contralateral side served as internal control. Preoperative CT, endoscopic, SNOT-22 and symptom visual analog scores (VAS) for each side were obtained. At 1, 3 and 6 months post-surgery, endoscopy, SNOT-22 and sinus VAS were recorded. Sinonasal mucosal secretions levels of IL-6, IL-17a and TNF α were measured at the time of surgery, 1 and 3 months post-operatively from each side.

Results:

Endoscopy, SNOT-22 and VAS scores improved on both sides ($p < 0.05$) at all postoperative timepoints ($p < 0.05$). HSI had no impact upon post-operative endoscopy or VAS at any time point. HSI significantly decreased IL-6 levels when compared to the control side at 1 month (-1410 pg/ml vs. +195.4 pg/ml, $p = 0.01$) but not at 3 months (-1922 pg/ml vs. -658.4 pg/ml, $p = 0.46$). Both control sides and HSI treated sides demonstrated decreased IL-17a at 1 and 3 months ($p < 0.05$), however there was no added benefit seen with HSI treatment. No significant change was seen in TNF α on either side at any time point.

Conclusion:

Intraoperative HSI at the time of ESS improves short-term postoperative inflammation as measured by IL-6 levels. The direct clinical impact of this finding and which patients are most likely to benefit warrants further investigation.

Incidence, Predictors, and Variation of Concomitant Nasal and Sinus Surgery, 2000-2009

Melissa Pynnonen, MD, MS, Gordon Sun, MD, MS Ann Arbor, MI USA

Introduction:

In light of increasing rates of both sinus and nasal operations, we undertook this study to describe the frequency of concomitant surgery with endoscopic sinus surgery. We sought to explore potential predictors of concomitant nasal surgery.

Methods:

We performed a secondary analysis of the State Ambulatory Surgery Database of Florida, 2000-2009. This dataset represents a 100% sample of ambulatory endoscopic sinus operations during this time.

Results:

Within this 10 year period there were 114,372 adult cases of endoscopic sinus surgery. After excluding those with missing data, and those cases representing advanced endoscopic procedures, we had 93,724 observations for analysis. We found that the population-standardized incidence of concomitant surgery has increased over 2000-2009 and that the strongest predictors of receipt of concomitant surgery are the surgeon's frequency of performing concomitant surgery and the surgeon's sinus surgery case volume.

Conclusion:

Concomitant nasal surgery is common and is being performed more commonly than ever. We have identified patient, physician, and regional factors associated with receipt of concomitant nasal surgery. More research is needed to better understand these factors.

Indications and Outcomes for the DrafilB Frontal Sinusotomy

*Justin Turner, MD, PhD, Reza Vaezeafshar, MD, Peter Hwang, MD
Nashville, TN USA*

Background:

Advanced frontal surgery techniques are often required when patients fail maximal medical therapy and standard endoscopic surgical approaches. Unlike other extended approaches, postoperative outcomes and indications for the DrafilB frontal sinusotomy have not been extensively reported.

Methods:

Patients undergoing the DrafilB frontal sinusotomy between 2007 and 2012 were identified by retrospective chart review. Data collected included demographics, imaging, sinus patency, and SNOT-20 scores.

Results:

A total of 18 patients were identified with surgery performed on a total of 22 frontal sinuses. 13 of 18 patients had received previous sinus surgery. The most common indications for the extended approach were lateralized middle turbinate remnant (8), mucocele (6), postoperative synechiae (5), and frontal sinus mass (3). Sinus ostium patency was maintained in 19 of 22 sinuses over an average follow-up period of 12.4 months. No complications were reported.

Conclusions:

The DrafilB frontal sinusotomy is a relatively safe procedure with multiple indications. Long-term sinus ostium patency was maintained in the vast majority of operated sinuses, suggesting that the DrafilB procedure may present an acceptable alternative to more aggressive extended frontal sinus approaches in select patients.

Invasive Fungal Sinusitis: A 12-year review

*Nipun Chhabra, MD, Eric Holbrook, MD, Stacey Gray, MD
Boston, MA USA*

Objectives:

We report on a series of patients afflicted with invasive fungal sinusitis (IFS). At the conclusion of this presentation, participants should be able to discuss the characteristics and clinical features of invasive *Aspergillus* and *Mucormycosis* of the paranasal sinuses.

Study Design:

Retrospective case series and review of the literature

Methods:

Over a 12-year period at a single tertiary care institution, 13 cases of IFS were identified. We review the pertinent etiology, clinical manifestations, diagnosis, and treatment of these aggressive mycoses and their associated complications.

Results:

After invasive mycosis was suspected by radiographic and clinical workup, surgical exploration and biopsy confirmed *Mucor* and *Aspergillus* in seven and six patients, respectively. The most common comorbidity was diabetes mellitus. Two patients had severe periodontal disease extending to the maxillary sinus as the inciting event, which is a rare etiology of IFS. Treatment included a multidisciplinary approach with systemic therapy and aggressive surgical debridement when possible. The mortality rate due to IFS alone was 30%.

Conclusions:

In select hosts fungal species may become opportunistic and invasive, resulting in severe morbidity or mortality. The occurrence of IFS has been increasing over the past several decades. *Aspergillus* and *Mucor* employ a variety of immunoevasive mechanisms to gain advantage over their hosts. A high index of clinical suspicion coupled with an early and aggressive combination of medical therapy, surgical intervention, and an understanding of the underlying immunologic competency of the patient is the best regimen to reduce morbidity.

Lobular Capillary Hemangioma of the Inferior Turbinate

Mike Sheu, MD, MPH, Ling Zhou, MD,
Richard Lebowitz, MD
New York, NY USA

Objectives:

- 1) To describe an unusual presentation of lobular capillary hemangioma of the inferior turbinate
- 2) A review of the literature regarding lobular capillary hemangioma in the nasal cavity

Study Design:

Case report and review of the literature

Methods:

A 32 year old female presented to the ENT clinic with a complaint of recurrent epistaxis over several months. Examination of the nasal cavity was significant for a friable vascular lesion emanating from the inferior turbinate. A corresponding lesion was found on CT imaging. She was taken to the OR for complete resection of this lesion including subtotal resection of the inferior turbinate.

Results:

Final pathology of this lesion was consistent with lobular capillary hemangioma.

Conclusion:

Lobular capillary hemangioma is an uncommon vascular lesion of the nasal cavity. To the best of our knowledge, an origin on the inferior turbinate has not previously been described for this lesion. Lobular capillary hemangioma should be considered in the differential diagnosis of vascular nasal cavity lesions, particularly in the setting of recurrent epistaxis.

Management of Rhinosinusitis in the Setting of Endoscopic Transsphenoidal Skull Base Surgery

Mark Friedel, MD, MPH, Seth Kaplan, MD,
Christopher Farrell, MD, James Evans, MD,
Marc Rosen, MD, Gurston New, MD
Philadelphia, PA USA

Introduction:

Endoscopic endonasal skull base surgery (ESBS) has proven to be a safe approach to select cranial base pathologies with potential for reduced patient morbidity. Despite expanding knowledge, there remains a paucity of data regarding management and potential complications in patients undergoing ESBS with rhinosinusitis. We review our patient experience and propose a clinical management algorithm for surgically addressing concurrent rhinosinusitis and skull base pathology.

Methods:

A retrospective chart review identified patients who underwent both endoscopic sinus surgery (ESS) for inflammatory disease and endoscopic transsphenoidal skull base surgery at our tertiary-care institution.

Results:

38 patients were identified. Two patients (5.2%) had a sinus mycetoma, 19/38 (50%) had chronic rhinosinusitis with nasal polyps (CRSP), and the remainder (16/38, [44.7%]) had CRS without nasal polyps. Four of 38 (10.5%) were staged procedures with ESS followed by ESBS whereas 34/38 (89.5%) underwent concurrent surgery. The two patients with sinus mycetomas were staged along with one case of medical refractory purulent rhinosinusitis. The fourth patient was staged based on her preference. Six of 38 (15.8%) developed post-operative sinusitis requiring antibiotic treatment. Two patients in the concurrent group required revision ESS for recurrent nasal polyposis. There were no cases of intraorbital or intracranial infectious complications.

Conclusions:

Most cases of CRS and CRSP can be surgically managed at the time of ESBS without an increased risk of intracranial infection. Patients with medical refractory purulent CRS or a sinus mycetoma were staged to avoid intracranial infectious complications.

Molecular Analysis of Bacterial Flora Associated with Maxillary and Ethmoid Sinusitis Using 16s rRNA Sequencing

Jeffrey Suh, MD, Julia Downes, M.Sc., Paula Carlson, M.Sc., Sidney Finegold, MD Los Angeles, CA USA

Introduction:

The role of bacteria and infection in chronic rhinosinusitis remains undefined. Bacteria have previously been isolated from chronically inflamed sinuses; however, their role in the chronicity of inflammation is unknown. The primary objective is to identify if the bacterial flora differs between ipsilateral maxillary and ethmoid sinus cultures in CRS patients and controls. The second objective is to compare and quantify bacterial counts from cultures in both groups.

Methods:

Specimens were obtained during surgery in patients with CRS or controls via tissue biopsy from the maxillary and posterior ethmoid sinuses. Quantitative culture and identification of organisms was performed via traditional culture and 16s rRNA sequencing. Bacterial colony forming units (CFU) were calculated in each sample.

Results:

In 5 control patients, the most commonly isolated bacteria included *Propionibacterium* sp. with smaller proportions of *Staphylococcus* species and a variety of anaerobic cocci. In 7 CRS patients, facultative GNRs and *Staphylococcus* species predominated, with smaller proportions of aerobic cocci and other bacteria. In both groups, no statistically significant difference ($p > 0.05$) was found between culture sites; similar bacteria were identified from maxillary and ethmoid cultures. Bacterial CFUs were higher in the maxillary ($p = 0.002$) and ethmoid ($p = 0.004$) sinuses of CRS patients than in controls.

Conclusions:

This study illustrates great diversity in bacterial sinus flora between patients, but also a remarkable similarity between ethmoid and maxillary sinus cultures utilizing both standard and culture-independent techniques. The results suggest that more easily available and abundant ethmoid tissue obtained during endonasal surgery is sufficient for bacterial studies.

Mucopyocele of the Middle Turbinate Masquerading as a Nasal Mass

Nipun Chhabra, MD, Stacey Gray, MD Boston, MA USA

Objectives:

To understand a rare case of a mucopyocele of the concha bullosa

Study Design:

Illustrative case report and review of the literature.

Methods:

An elderly gentleman's clinical and operative course is presented. We review the pertinent clinical and radiographic manifestations, diagnosis, and treatment of this rare deformity of the middle turbinate.

Results:

A 76-year old man with a history of unilateral nasal obstruction and chronic sinusitis presented after failed topical and medical therapy. Examination revealed a disfigured and abnormal middle turbinate that completely occluded the right nasal fossa. Intraoperatively, a severely distended concha bullosa over 2 cm filled with copious purulent material was encountered. Surgical debridement and excision of the cavity was performed and the patient symptomatically improved, eventually demonstrating complete clinical resolution.

Conclusions:

Although a concha bullosa is a common anatomic variant of the middle turbinate, a literature review revealed that infection of the concha is very rare. In some cases, secondary infection and distention of the concha can extend to the orbit and even intracranially. A mucopyocele of the concha may present as a unilateral nasal mass and radiographic imaging is often necessary to further delineate the extent of obstruction. The recognition of several important clinical and radiographic features can help aid in the diagnosis of this rare disorder. Similarly, a thorough understanding of the pathophysiology and surgical steps is essential for satisfactory postoperative results.

Nasal Paraganglioma: A Case Report

Omer Saglam, MD, Zuhai Saglam, MD,
Fatma Uzunlar, MD
Beyoglu, Istanbul Turkey

Paragangliomas are rare neuroendocrine neoplasm of extraadrenal autonomic nervous system. These are usually benign, slowgrowing vascular tumors found in the abdomen, thorax, head and neck region. Head and neck paraganglioma is primarily located in the temporal bone and carotid body.

Paragangliomas of nose and paranasal sinus are extremely rare and very few cases have been reported. In this case report we present the case of a 25-year-old female patient with nasal paraganglioma suffering from nasal obstruction and nasal bleeding. Clinical presentation of the tumors were related to the locations. The clinic and radiological findings are not characteristics, and should be differentiating from other nasal pathologies.

Olfactory Changes After Endonasal Endoscopic Transsphenoidal Surgery for Pituitary Adenoma

Shin Hye Kim, MD, Pona Park, MD
Jee Hye Wee, MD, Sung Joon Park, MD,
Doo Hee Han, MD, Chae-Seo Rhee, MD
Seoul, Korea

Objective:

To evaluate the olfactory results after the endonasal endoscopic transsphenoidal approach (EEA) for pituitary adenoma, and to clarify possible risk factors for poor olfactory results.

Methods:

Prospective study comparing olfactory results, for patients who were admitted to our Minimally Invasive Skull Base Center for EEA of pituitary adenoma, was conducted. Olfactory tests were performed preoperatively, and 1, 3 and 6 months after surgery and CT imaging was done preoperatively and 6 month after surgery. Recovery of the olfaction was defined as postoperative score within 75% of preoperative result. Various tumor factors, intraoperative and perioperative surgical findings, and postoperative CT imaging data were analyzed for potential risk factors.

Results:

Postoperative olfaction tests showed abrupt decrease of olfaction at postoperative 1 month and showed recovery from that point. There were significant differences in scores between recovery and non-recovery groups. Our study showed 63.2% of recovery rate. In univariate analysis, male subjects ($p=0.042$), with non-functioning ($p=0.043$) and large ($p=0.006$) tumor, with superior turbinectomy ($p=0.034$) or posterior ethmoidectomy ($p=0.049$) during the operation and short vertical length of septum at anterior wall of the sphenoid sinus ($p=0.032$) were at high risk of non-recovery group. However, in multivariate analysis, only tumor size was a significant risk factor for persistent olfactory loss ($p=0.03$).

Conclusion:

We were able to identify the pattern of olfactory deterioration and recovery of the olfaction after EEA for pituitary adenoma. In addition, tumor size larger than 2.2 cm might be considered as poor prognostic factor for the recovery of olfaction.

Orbital Management in Acute Invasive Fungal Sinusitis: A Systematic Review, Case Series and Evidence Based Treatment Algorithms for a Vexing Conundrum

Devyani Lal, MD, Clifton Ewbank, MS
Phoenix, AZ USA

Background:

Although advances in surgical techniques and anti-fungal therapy have resulted in decreased morbidity and mortality from acute invasive fungal sinusitis (AIFS), management of orbital AIFS remains a dilemma. The purpose of our study was to review our experience and the English literature to create a contemporaneous, evidence-based surgical treatment algorithm for orbital AIFS.

Aims:

1. Retrospective review of orbital AIFS cases
2. Systematic literature review for studies and protocols on orbital AIFS
3. Create an evidence-based surgical treatment algorithm

Methods:

A retrospective review of all cases of orbital AIFS treated by the senior author was conducted. A systematic review of the literature from 1985 onwards was conducted. A surgical treatment algorithm was created.

Results:

Three cases of extensive orbital AIFS involvement at our institution underwent serial surgical debridement with orbital preservation, aggressive anti-fungal therapy and supportive management. All had fixed globes at presentation. All three patients survived, two with intact vision. A systematic literature review did not reveal any studies with algorithms for orbital AIFS management. The largest series of orbital preservation was reported in 8 patients with limited orbital involvement. Case reports presented both orbital exenteration and preservation. Patients from individual reports were analyzed for extent of orbital AIFS, therapeutic interventions and survival. A surgical treatment algorithm was created.

Conclusions:

Orbital preservation may be attempted in orbital involvement in AIFS. Central retinal artery occlusion and orbital apex syndromes may be relative indications for exenteration. Orbit preservation may serve cosmesis even in the setting of a non-functional eye.

Outpatient Endoscopic Sinus Surgery in Cystic Fibrosis Patients - Predictive Factors for In-Hospital Admission

Ethan Soudry, MD, Amar Miglani, MD,
Justin Chen, MD, Paul Mohabir, MD,
Jayakar Nayak, MD, PhD, Peter Hwang, MD
Stanford, CA USA

Background:

A growing number of cystic fibrosis (CF) patients undergo endoscopic sinus surgery (ESS) in the outpatient setting despite their CF related comorbidities. Our objective was to determine the predisposing factors for post operative admission in this unique patient group.

Methods:

Retrospective chart review of cystic fibrosis patients who underwent endoscopic sinus surgery between the years 2005-2012. Multiple preoperative, intraoperative and immediate postoperative variables were correlated to same day discharge versus post operative admission.

Results:

33 patients who underwent 37 outpatient endoscopic sinus surgeries were identified. 17/37 (46%) patients were admitted postoperatively for observation. Surprisingly, pulmonary function, CF related comorbidities and history of lung transplant were not predictors of postoperative admission. Univariate analysis showed that patients were more likely to be admitted if they had a history of = 4 ESS ($p=0.003$), procedure duration > 2.5 hours ($p=0.04$), intraoperative blood loss greater than 150cc ($p=0.006$), increased immediate post op pain scores ($p=0.004$) or required larger doses of narcotics for pain control ($p=0.015$). A maximum recovery unit pain score = 7 was the only significant predisposing factor for postoperative admission on logistic regression analysis ($p=0.02$).

Conclusion:

Nearly half of all the CF patients in our series were admitted post ESS for observation. Interestingly, factors other than the CF related co-morbidities were associated with postoperative admission. Understanding these predisposing factors for postoperative admission may be helpful in the perioperative planning in this patient group undergoing ESS.

Patients Experience with In Office Cone Beam CT: A Survey Study

*Fariha Farid, DO, Boris Karanfilov, MD
Columbus, OH USA*

Introduction:

The diagnosis of chronic rhinosinusitis is based on patient symptoms, endoscopic exam and computed tomography (CT) findings. CT plays a critical role in defining mucosal disease and anatomic abnormalities. The gold standard for sinus imaging is multi-slice computed tomography (MSCT). Cone beam computed tomography (CBCT) was introduced for dental imaging in the late 1990s and technological advances have allowed for use in sinus imaging. The advantages of CBCT include lower radiation dose, cost savings and patient convenience. The purpose of this study is to evaluate the patients experience with hospital based MSCT versus office based CBCT.

Methods:

This was an IRB approved study conducted at a tertiary rhinology practice with an accredited CBCT. 52 patients were enrolled between July 2012 and November 2012 that had undergone a MSCT within the past 3 months. Surveys were completed after the CBCT and consultation with the physician. Inferential statistics determined statistical significance between comparison variables using paired sample t-test. Statistical significance was evaluated at the $\alpha=0.05$ level. The null hypothesis that patients have equal experiences with CBCT versus MSCT was rejected.

Results:

Based on the variables surveyed: convenience, radiation dose, comfort, timeliness of results, accuracy and cost savings, patients responses were statistically significant ($p<0.001$) in favor of CBCT.

Conclusions:

CBCT is a new technology that delivers high-quality low-radiation imaging of the sinuses. This study demonstrates that surveyed patients report point-of-care CBCT as a positive experience compared to MSCT. CBCT is a safe, efficient and cost containing imaging modality for managing chronic rhinosinusitis.

Physician Assessment of Mucopurulence in Chronic Rhinosinusitis: Inter-rater Reliability and Treatment Considerations

*Jorge Contreras, MD, Stella Lee, MD,
Victor Yu, MD, Berylin Ferguson, MD
Pittsburgh, PA USA*

Introduction:

No studies to date address the validity of endoscopic assessment of the character of sino-nasal secretions in patients with mucopurulent chronic rhinosinusitis (CRS) and their association with a positive culture of pathogenic bacteria (PCPB). Our objective was to determine inter-rater reliability (IRR) of physician assessment of mucopurulence in patients with CRS. Risk factors for PCPB were also evaluated.

Methods:

Thirty-eight patients with purulent CRS underwent endoscopically guided sino-nasal cultures via aspiration and/or calginate swab. Two raters independently assessed the presence of mucopurulence.

Results:

The IRR for mucopurulence for the 38 patients was moderate ($K=0.68$). However if IRR was restricted to the 24 patients with a PCPB, then IRR increased ($K=0.74$). The assessment of mucopurulence had a positive predictive value of 76.6%, negative predictive value of 87.5%, with sensitivity of 95.8%, and low specificity of 50% for predicting a PCPB. The relative risk (RR) of a PCPB for patients with previous endoscopic sinus surgery (ESS) was 1.58, for nasal polyps 1.26, asthma 1.08, aspirin-exacerbated respiratory disease 0.76, and allergic rhinitis 0.67. Twelve patients had immunodeficiency and/or autoimmune disease and the majority of PCPB for this group showed *Pseudomonas aeruginosa* (RR for *Pseudomonas* 15.34).

Conclusion:

Physician assessment of mucopurulent CRS shows moderate IRR for the presence of mucopurulence associated with a PCPB. Patients with previous ESS or nasal polyps were more likely to have a PCPB. A history of autoimmune or immunodeficiency disorders increased the risk of a PCPB for *Pseudomonas* and could help direct appropriate choice of antibiotic therapy.

Plasmablastic Lymphoma of the Sinus: A Rare Clinical Entity

*Joshua Yelverton, MD, Austin DeHart, BS
Celeste Powers, MD, PhD, Evan Reiter, MD
Richmond, VA USA*

Purpose:

To present a case of plasmablastic lymphoma (PBL) of the maxillary sinus and to review the imaging, pathology, and reported treatments of this rare neoplasm.

Methods:

Case report and literature review

Summary of Results:

A 44 year old HIV-positive male presented with a one year history of recurrent, worsening episodes of left-sided epistaxis. Physical exam revealed a mass protruding from the left middle meatus. Computed tomography demonstrated an enhancing mass in the left maxillary sinus without significant bone erosion. The patient underwent endoscopic resection. Pathology revealed atypical lymphoid infiltrate consistent with PBL. PBL is most commonly described in the oral cavity of HIV-positive patients. PBL of the paranasal sinuses is rare with only 15 reported cases.

Conclusion:

PBL should be included in the differential diagnosis of any HIV-positive patient who presents with an aerodigestive tract mass. PBL has been found to be an aggressive tumor with poor overall survival. Response to chemotherapeutic regimens has been varied and treatment algorithms are still being investigated.

Polypoid Changes of the Middle Turbinate as an Indicator of Atopic Disease

*Laura White, MD, Melissa Rotella, NP,
John Delgaudio, MD
Atlanta, GA USA*

Introduction:

High levels of local IgE have been demonstrated in nasal polypoid tissue; however, a consistent association between nasal polyps and allergy has not been proven. The authors have observed that polypoid edema isolated to the leading edge of the middle turbinate (MT) is highly associated with allergic rhinitis. The objective of this study was to determine if there is an association between isolated MT polyps and inhalant allergy.

Methods:

A single institution prospective study was performed. Consecutive patients presenting to the senior author that were found to have isolated MT polyps on endoscopic exam were recruited. Nasal and allergy symptoms were documented on the patient's history. Allergy testing was recommended to all patients if it had not been performed within the past 6 months.

Results:

Eighteen patients were found to have isolated MT polypoid edema documented on endoscopic exam. Thirteen patients underwent intradermal or serum allergy testing, while five refused allergy testing of any kind. Thirteen of 13 patients who were tested were found to be positive for inhalant allergy.

Conclusions:

Our findings provide evidence to support an association between isolated middle turbinate polypoid edema and inhalant allergy. Allergy testing should be recommended in patients with isolated MT polypoid edema. These findings should not be extrapolated to support a connection between inhalant allergy and generalized polyps.

WITHDRAWN

Practice Patterns Regarding Non-invasive Sinusitis in the Immunosuppressed Patient Population

Zara Patel, MD
Atlanta, GA USA

Introduction:

The number of immunosuppressed patients seen in both inpatient and outpatient settings is growing remarkably. Currently, there is no guideline on how treatment of non-invasive sinusitis in these patients may differ from that of the general population, and practice patterns vary widely across the country. The purpose of this survey was to examine practice patterns and management for this patient population.

Methods:

A survey was sent to the membership list serve of the American Rhinologic Society. 12 questions were asked. Four demographic questions were asked about the physicians and their practices. Four questions were asked about the type of immunocompromised patients they saw. Two questions were asked about management in the setting of significant acute and chronic sinusitis. The responses were collected and analyzed using Pearson independent chi-square testing.

Results:

Of the 871 members on the list serve only 89 physicians responded. The majority of responders were sinus and skull base surgeons practicing in an academic setting. There was a large range of geographic location, years in practice and patient population. Two significant findings were relating years in practice to management of chronic sinus immunocompromised patients ($p = 0.012$), and the correlation between choice of management option in acute and chronic sinus immunocompromised patients ($p = 0.006$).

Conclusions:

There is no standardized method of treating the vulnerable patient population of immunocompromised patients with non-invasive acute and chronic sinusitis and this survey demonstrates the wide range of practice. Clinical research is needed to standardize and optimize treatment for these patients.

Prognosis for 6th Nerve Palsy Resulting from Paranasal Sinus Disease

Craig Miller, B.S., Vijay Ramakrishnan, MD,
Oswaldo Henriquez, MD, Jeffrey Suh, MD,
Alexander Chiu, MD
Tucson, AZ USA

Introduction:

Cranial nerve VI's (CNVI) proximity to critical vasculature and the sinuses make it susceptible to damage leading to horizontal gaze diplopia. A wide range of literature describes myriad causes for CNVI palsy, but there is a lack of references that recognize paranasal sinus pathology as an etiology as well as the prognosis and timeline for resolution. We describe a series of patients that presented with CNVI palsy, their management, and prognosis for recovery.

Methods:

Multi-institutional retrospective review of patients presenting with CNVI palsy between 2009 and 2012.

Results:

Fourteen patients at 4 institutions were identified. Eight had neoplasms (7 malignant and 1 benign) originating from the paranasal sinuses, three had AFS, two patients had invasive fungal sinusitis and one had chronic bacterial sinusitis. The average follow-up was 9 months (range 1-16 months). Thirteen patients underwent surgery, three received chemotherapy, and four had radiation therapy. The 6th nerve palsy resolved in fifty percent of the cases with an average time to resolution of six weeks (range 2 -12 weeks)

Discussion:

Paranasal sinus pathology is a rare cause of CNVI palsy. Masses compressing, but not destroying, the neurovasculature of the cavernous sinus had optimal post-treatment outcomes with full resolution never occurring prior to 2 weeks from onset. Destructive lesions that invaded CNVI and its vasculature, ie. invasive fungus, were poor indicators for recovery. Knowledge of factors that affect recovery can help clinicians predict disease course and prognosis for resolution of the defect.

Reinitiating CPAP after Transnasal Endoscopic Pituitary Surgery

*William Yao, MD, Daniel Yosher, MD, Masayoshi Takashima, MD
Houston, TX USA*

Objective:

Examination of the possibility of restarting continuous positive airway pressure (CPAP) in patients with obstructive sleep apnea (OSA) following transnasal endoscopic pituitary surgery with cerebrospinal fluid (CSF) leak repair.

Background:

Restarting CPAP for patients with OSA following an endoscopic transnasal pituitary surgery is a concern due to the possibility of surgical repair disruption and pneumocephalus. There are no references in the literature describing the re-initiation of CPAP therapy for these patients. Delineating appropriate management protocols for these patients is needed since untreated OSA can cause significant morbidity and mortality.

Method:

Retrospective case series review.

Results:

Two patients with severe OSA underwent transnasal endoscopic resection of a pituitary adenoma with primary repair of CSF leak. In both cases, patients had an endoscopic examination revealing a well healed surgical repair. The patients were restarted on CPAP four months after the repair. While collaborating with the sleep lab, the patients were titrated to the lowest possible CPAP pressure setting. CT scan of the head obtained one week after restarting CPAP did not reveal evidence of any pneumocephalus or disruption of repair. The patients have continued CPAP therapy without any complications and with good resolution of their OSA symptoms.

Conclusion:

This is the first reported case series describing the safety of reinitiating CPAP therapy for OSA following transnasal endoscopic pituitary surgery. As the incidence of OSA rises, appropriate management algorithms for treating these patients become more important. This review was intended to initiate further discussion on the appropriate treatment of these patients.

Relationship of Antibiotic Failure to Bacterial and Fungal Culture Results in Patients with Acute Rhinosinusitis after Endoscopic Sinus Surgery

*Jennifer Decker, MD, Jay Dutton, MD, Neal Lofchy, MD
Chicago, IL USA*

Introduction:

The microbiology of recurrent sinusitis in patients who have previously required sinus surgery is known to contain resistant organisms that are difficult to treat. Acute infection in these patients typically requires broader-spectrum antibiotics than in the general population. Cultures and a second course of antibiotics are widely used should initial antibiotic treatment fail. However, other factors than bacterial antibiotic resistance may play a role in treatment failure. We examined the bacterial types and resistance patterns in patients with acute rhinosinusitis who failed a first course of antibiotic therapy to determine if bacterial resistance or other factors influenced treatment outcome.

Methods:

A retrospective chart review was performed of sinus cultures over the previous 2 years in a private rhinology practice. Patient who had undergone ESS, developed acute rhinosinusitis, but failed initial antibiotic therapy with available sinus cultures taken were included. Culture results were reviewed for bacterial and fungal growth and antibiotic resistance patterns.

Results:

31% of patients failed initial antibiotics despite documented susceptibility of cultured bacteria to their antibiotics. 14% of patients had resistant bacteria, 18% had fungal growth but no bacterial growth. 26% of patient showed no organism growth, and 10% of patients recovered without a second course of oral antibiotics.

Conclusions:

Failure to respond in acute infection to oral antibiotics in patients with chronic rhinosinusitis is multi-factorial in origin. Disease modifiers such as staphylococcal superantigens, biofilms, and fungal antigens play a large role treatment should include both appropriate antibiotic coverage and focus on underlying inflammatory mediators.

Sinonasal Computational Fluid Dynamics Airflow Patterns in Actual and Virtual Surgery for Chronic Rhinosinusitis

Gitanjali Fleischman, MD, Julia Kimbell, PhD, Dennis Frank, PhD, Charles Ebert, MD, MPH, Brent Senior, MD, Adam Zanation, MD Chapel Hill, NC USA

Objective:

To determine if virtual functional endoscopic sinus surgery (FESS) can be used to predict post-FESS surgical airflow patterns using computational fluid dynamics (CFD).

Methods:

MIMICS™ software was used to construct three-dimensional (3D) airway models based on pre-operative and 12-week post-operative CT scans of an adult patient with chronic rhinosinusitis who underwent FESS. The pre-operative 3D model was then digitally modified to mimic the actual surgery. Steady-state inspiratory airflow was simulated using CFD software Fluent™. Airflow allocation and velocity were compared in the pre-operative, virtual surgery (VS), and post-FESS models.

Results:

All models showed similar airflow patterns within the nasal cavity, excluding sinus regions. Virtual and post-FESS models showed comparable increased airflow into the maxillary and sphenoidal cavities. Nasal resistances were similar in pre-operative and VS models (0.464 and 0.455 Pa/(ml/sec), respectively), and were over twice the resistance of post-FESS model (0.187 Pa/(ml/sec)). Total airflow into the post-FESS maxillary sinus (MS) was greater than two-fold that of the VS model.

Conclusions:

Anatomical changes due to FESS did not affect airflow patterns in the nasal cavity despite the presence of a maxillary antrostomy in both VS and post-FESS models. The VS model was able to accurately predict post-FESS sinus airflow patterns, but not overall nasal resistance nor the amount of total airflow into the MS. These differences may be due to effects of inferior turbinate inflammation not accounted for in the VS model. Future directions will take into account post-surgical healing, allowing us to create a more accurate virtual model.

Sinonasal Respiratory Epithelial Adenomatoid Hamartomas: Case Series and Literature Review

Joseph Brunworth, MD, Rohit Garg, MD, MBA, David Keschner, MD, JD, Lester Thompson, MD, Jivianne Lee, MD Anaheim, CA USA

Background:

Respiratory epithelial adenomatoid hamartomas (REAHs) are rare, benign glandular proliferations of the sinonasal cavity and nasopharynx. Since its initial characterization; literature regarding this lesion has been limited, mostly comprised of case reports and histopathologic analyses.

Objectives:

The aim of this study is to expand our understanding of this unique lesion by presenting a case series of REAHs.

Methods:

A retrospective chart review was performed on patients with a diagnosis of REAH from 2002-2011. Data was collected with respect to age, gender, clinical presentation, histopathology, radiographic features, treatment, and outcomes. As olfactory cleft expansion has been reported to be suggestive of REAH, maximum olfactory cleft widths(MOCs) were also determined.

Results:

51 cases of REAH were identified, 37 males (72.5%) and 14 females(27.5%). The mean age was 58.4 years. Headache, nasal obstruction, rhinorrhea, and hyposmia were the most common presenting symptoms. 16(31.4%) presented as isolated lesions of the nasal cavity, while 35 (68.6%) were associated with concurrent inflammatory pathology. Enlargement of MOCs was evident on computed tomography(CT), with mean MOCs of 8.64mm and 9.4mm in the coronal/axial planes respectively. There were no statistically significant differences between MOCs of isolated (7.96mm) versus associated (9.63mm) lesions (p=0.25). All patients underwent endoscopic resection with no recurrences after a mean follow-up of 27.2 months.

Conclusion:

REAHs are rare entities that should be included in the differential diagnosis of sinonasal masses. Clinically, they may appear as localized, isolated lesions or occur more diffusely in conjunction with other inflammatory processes. Irrespective of clinical presentation, endoscopic removal appears to be curative.

Sinonasal Sarcoidosis: A New System of Classification Acting as a Guide to Diagnosis and Treatment

*William Lawson, MD, DDS, Nancy Jiang, MD, Jeffrey Cheng, MD
New York, NY USA*

Objectives:

The signs and symptoms of sinonasal sarcoidosis are diverse and non-specific. It easily mimics more common sinonasal disorders such as allergic rhinitis, bacterial sinusitis, and atrophic rhinitis. The purpose of this study is to develop a classification system that will help serve as a guide for both diagnosis and treatment.

Study Design:

case series and review of the literature

Methods:

A retrospective chart review was performed of all patients with biopsy proven sinonasal sarcoidosis treated by the senior author from 1974 to 2009. A PubMed literature review of all published case series of sinonasal sarcoidosis was also reviewed.

Results:

The charts of 14 patients were reviewed. Follow up time ranged from 6 months to 28 years. Presenting signs included hypertrophic mucosa, nasal polyps, crusting, nasal enlargement, and destructive processes. Eight patients underwent medical management alone and 6 patients underwent endoscopic sinus surgery. Four out of the 6 patients were successfully treated with surgery. On review of the literature, 218 cases of sinonasal sarcoidosis was found, of which 39 patients underwent surgery and clinical improvement was seen in 12 of these patients.

Conclusions:

Based on critical analysis of the clinical presentation in our case series and on review of the literature, sinonasal sarcoidosis can be classified into 4 subgroups: atrophic, mucosal hypertrophic, destructive, and nasal enlargement. Each subgroup responds differently to treatment and has its own differential diagnosis. Surgery is only indicated for a select group of patients and the vast majority of patients benefit from medical management alone.

Small Colony Variants of Staphylococcus Aureus in Chronic Rhinosinusitis

*Sarah Gitomer, MSIV, Daniel Frank, PhD, Vijay Ramakrishnan, MD
Aurora, CO USA*

Introduction:

WITHDRAWN
S. aureus is a prevalent pathogen in chronic rhinosinusitis (CRS), but is difficult to eradicate and often recurs after treatment. Small colony variants (SCVs) are a metabolically inactive form of bacteria that can live intramucosally and are resistant to antibiotics. In order to determine whether SCVs contribute to S. aureus's ability to persist after standard treatments we compared the prevalence of S. aureus SCVs in CRS patients and controls.

Methods:

Sinus aspirates and endoscopically-guided swabs were collected and plated on gram positive-(CNA) and Staphylococcus-specific (mannitol) media and screened for the presence of phenotypically small colonies. SCVs' species were determined with genetic techniques.

Results:

Thirty-five samples were collected, 22 from CRS patients and 13 from control patients. Fourteen CRS patient samples grew S. aureus (63.6%), and of the S. aureus positive samples, 2 grew SCVs (9.1%), neither of which was confirmed to be S. aureus with genetic sequencing. Of the controls, 9 grew S. aureus (69.2%), and of these, 2 grew SCVs (15.4%), neither of which was S. aureus. Significantly more SCVs grew in the control group than in the CRS group ($p < 0.01$). On average follow-up of 1.9 months, the SCV-positive patients did not develop new symptoms of CRS.

Conclusions:

Despite rigorous screening, neither CRS or control populations were found to be colonized with S. aureus SCVs. Because SCVs were more commonly associated with control patients and not correlated with recurrence of symptoms, we conclude that they are unlikely to be a common cause of recurrence of CRS symptoms.

Surgical Management Of Rhinosinusitis in Onco-Haematological Patients

*Stefano Di Girolamo, MD, Sara Mazzone, MD, Roberta Di Mauro, MD, Maria Cantonetti, MD
Rome, Italy*

Introduction:

Paranasal sinus infection in immunocompromised patients demands a combination of medical and surgical therapy. Multiple medical problems put the surgeon in a challenging choice. The sinus ostia blockage plays a key role in the pathogenesis of the sinus infections. Balloon dilatation surgery (DS), a complementary tool for endoscopic sinus surgery, is a minimally invasive, tissue preserving procedure. The study evaluate the results of this treatment for isolated sinusitis in severe immunocompromised patients.

Materials and Methods:

A retrospective chart review was conducted in 110 patients affected by rhinosinusitis selected in a group of 380 haematologic patients. 25 patients were treated with DS, in 17 was required general anesthesia and in 8 has been used a local anesthetic. The other 85 patients were treated with traditional endoscopic sinus surgery (ESS), 70 with general anesthesia and 15 with local anesthesia.

Results:

In DS group the intraoperative bloodloss was minimum. A lower number of anterior nasal packing and repacking were necessary. Post-surgical nasal debriments and the incidence of crusting and synechiae were lower. Local anesthesia was possible in a larger group patients.

Conclusions:

A careful balance between surgery and medical therapy is mandatory to provide the right treatment for these patients that are often poor surgical candidates. Balloon dilatation surgery represents a potentially low aggressive treatment and appears to be relatively safe and effective in onco-hematologic patients. All these remarks may lead the surgeon to consider a larger number candidates for surgical procedure.

The Diagnosis and Management of Sinonasal Glomangiopericytoma

*Benjamin Paul, MD, Jonathan Lebowitz, Aron Pollack, MD, Richard Lebowitz, MD
New York, NY USA*

Introduction:

The following is a case presentation of a 61 year old male who was referred to the otolaryngology clinic with epistaxis and was found to have a large unilateral nasal mass. After a transnasal endoscopic excision, the lesion was diagnosed as a rare, recently reclassified sinonasal neoplasm termed a glomangiopericytoma.

Discussion:

Previously described as a sinonasal-type hemangiopericytoma, an endonasal glomangiopericytoma has been renamed because of its unique histologic subtype, a perivascular glomus-like myoid phenotype, and distinct clinical behavior when compared with other soft tissue head and neck hemangiopericytomas. Overall, glomangiopericytoma carries a good prognosis after surgical resection as they are indolent with low malignant potential.

Summary:

The following case report highlights the challenging histologic differential diagnosis and discusses of the management of a glomangiopericytoma when the mitotic division rate is unexpectedly high.

The Impact of Preoperative Systemic Antibiotics and Steroids on Surgical Outcomes in CRS Patients Undergoing FESS: A Retrospective Study

Jamil Manji, BSc.H, Andrew Thamboo, MD, Al-Rahim Habib, BSc, Iain Hathorn, MD, Amin Javer, MD FRCSC FARS
Vancouver, BC Canada

Background:

The highly vascularized nature of the paranasal sinuses makes intraoperative blood loss a significant variable for functional endoscopic sinus surgery (FESS). Bleeding into the endoscopic field of view during FESS represents a hindrance to the surgeon and can increase the chance of complications. Several options have been suggested for controlling intraoperative blood loss such as local vasoconstrictors, patient body position, and preoperative corticosteroid treatment.

Objective:

Our objective was to retrospectively assess the impact of systemic preoperative antibiotics and corticosteroids on surgical outcomes in patients undergoing FESS for CRS.

Methods:

A retrospective chart review of 106 patients that had undergone bilateral FESS was conducted. This population consisted of patients that had received the standard of care course of Clavulin and Prednisone for 7 days preoperatively (n=53), and those that had not because they were participants in an unrelated randomized control trial (n=53). Time of surgery (TOS) was the primary outcome measure. Total blood loss (TBL) and blood loss per minute (BL/min) were also recorded.

Results:

TOS was significantly reduced in the group receiving preoperative medication (p=0.0279). However, TBL (p=0.2413) and BL/min (p=0.6452) were not significantly different between the two groups. Population stratification by disease severity produced similar results as in the overall population.

Conclusions:

While we found no significant impact on blood loss; preoperative treatment with systemic antibiotics and steroids may facilitate the ease of FESS cases, as indicated by a significant decrease in duration of surgery.

The Inferiorly Based Septal Transposition Flap for Coverage of Large Nasal Floor Mucosal Defects

Jonathan Ting, MD, Nipun Chhabra, MD, Arthur Wu, MD, Benjamin Bleier, MD
Indianapolis, Indiana USA

Introduction:

To achieve coverage of massive skull base defects, nasoseptal flap harvest may include portions of the nasal floor and inferior meatal mucosa. Exposure of large areas of bone may result in prolonged wound healing and symptomatic nasal crusting. This study describes a novel inferiorly based, contralateral septal transposition flap designed to provide intraoperative mucosal coverage for these regions.

Methods:

A morphometric analysis of the septum, nasal floor, and inferior meatus was performed in 10 multiplanar high-resolution sinus CT scans. Dimensions of the transposition flap required for coverage of the contralateral inferior meatus were calculated and correlated with relevant anatomic landmarks. A review of all cases in which a transposition flap was utilized was performed.

Results:

The average height of the transposition flap and width of the contralateral nasal floor defect were 3.3cm and 1.24cm respectively. In all 10 CT scans, the projected placement of a transposition flap across a midline septal defect resulted in coverage of the nasal floor laterally into the inferior meatus, as long as the inferior border of the septectomy was ~1cm from the nasal floor. Three patients underwent a transposition flap following posterior septectomy and extended nasoseptal flap harvest with good results.

Conclusions:

The expansive mucosal harvest required in the setting of large defects results in extensive areas of demucosalized bone along the nasal floor and inferior meatus. When coupled with a judicious posterior septectomy, the described septal transposition flap can be used to minimize any significant bone exposure following surgery.

The Pedicled Nasoseptal Flap in the Endoscopic Closure of Idiopathic Clival Cerebrospinal Fluid Leaks

Alessandro Pusateri, MD, Enzo Emanuelli, MD, Elina Matti, MD, Davide Locatelli, MD, Frank Rikki Canevari, MD, Fabio Pagella, MD Pavia, Italy

Introduction:

Cerebrospinal fluid (CSF) leaks that originate within the posterior wall of the sphenoid sinus (clivus) pose a surgical challenge due to difficulties with access and visualization. The objective of this report is to illustrate concepts for the successful management of idiopathic clival CSF leaks.

Methods:

A retrospective data analysis was performed on 8 patients who presented to our departments for endoscopic repair of a spontaneous clival CSF leak from 2005 to 2012. A layered reconstruction of the posterior sphenoid sinus wall under endoscopic visualization was performed. Group A (n = 5) received a standard skull base repair with a multilayered reconstruction (underlay and overlay grafting), Group B (n = 3) instead, underwent a single-layered (overlay grafting) reconstruction using a pedicled nasoseptal flap (Hadad flap).

Results:

The patient cohort included 8 women, mean age was 63 years (36 - 91 years). An endoscopic transnasal parasseptal approach was performed in 2 cases (25%), a transthemoidal approach in 6 cases (75%). The average hospital stay was 6.5 days (4 - 12 days). The mean length of follow-up was 49 months (6 - 95 months). The overall success of the endoscopic repair was 87.5% (7/8). Group A / Group B: 80% (4/5) / 100% (3/3).

Conclusions:

This series demonstrates that a minimally invasive endoscopic repair of idiopathic clival CSF leaks may be accomplished with an acceptable rate of morbidity and excellent outcomes, even with a single-layered reconstruction of the defect using a pedicled nasoseptal flap.

The Positive Predictive Value of Radiologic Imaging of Clival Lesions

Akaber Halawi, MD, Myriam Bermudez, MD, Bruce Tan, MD, Rackesh Chandra, MD, Robert Kern, MD, David Conley, MD Chicago, IL USA

Introduction:

Clival lesions represent a heterogeneous group of pathologies often sharing overlapping radiographic features posing a dilemma in accurate pre-operative diagnosis. The objective of this analysis is to assess the positive predictive value of radiologic evaluations of clival lesions.

Methods:

Retrospective chart review of endoscopically resected clival lesions from 2006 to 2012.

Results:

33 patients were identified. Mean age was 49.7. Ten patients had a histologic diagnosis of chordoma, 2 possible low grade chondrosarcomas, 4 craniopharyngiomas extending to the clivus, 2 clival pituitary adenomas, 1 echordosis physaliphora, 1 epidermoid, 1 cholesterol granuloma, 1 meningioma, 3 metastatic carcinomas, 1 squamous cell carcinoma, 1 Burkitt's Lymphoma, 1 pituitocytoma, and 1 rhabdoid papillary. Three chordoma patients were excluded for incomplete imaging. The PPV for radiologic diagnosis of chordomas was 70%; it increases to 76.92% when the radiologic impression includes chordomas and low grade chondrosarcoma. The PPV for malignant lesions was 50%. The PPV for craniopharyngiomas was 100%. 42.9% of patients with chordomas were localized to the clivus, 69.2% were hypointense on T1, 76.9% were hyperintense on T2, varying degree of enhancement (53% showed more than 90% homogenous enhancement), 61% had non-restricted DWI, and 76.9% had cortical disruption on CT scan.

Conclusion:

Although chordomas are the most common clival lesion, other pathologies including malignancy comprise 63.6 % of lesions in this area. The most reliable radiologic features of chordoma are hyperintense T2 signal on MRI, cortical disruption on CT, and location. Radiographic studies have a high but imperfect PPV for this common clival lesion.

The Prevalence of Uncinate Process Osteitis in CRS Patients Versus Controls

Peter Catalano, MD, Meir Warman, MD, Rahul Gupta, MD, Rohan Wijewickrama, MD Boston, MA USA

Background:

Chronic rhinosinusitis (CRS) is a common inflammatory condition with varied etiologies. Osteitis of the underlying bone and in particular the uncinata process (UP) is postulated as one of the main causes for CRS. The prevalence of bone remodeling changes in the uncinata process (UP) of healthy controls has not been previously examined, therefore this study was conducted to determine and compare the prevalence of osteitis of the uncinata bone in patients with CRS versus healthy controls.

Methods:

Prospective histopathologic examination for the presence or absence of osteitis of the UP/uncinate bone was performed in the study group (patients undergoing sinus surgery for CRS) and a similar-sized control group. The presence of osteitis was determined as bone remodeling and the formation of woven bone using polarized light microscopy.

Results:

A total of 20 uncinata bones were examined: 10 from patients with CRS and 10 controls. Mean age of patients was 43 and 44 years in the two groups. Pathologic evidence of osteitis was found in 50% of the CRS patients and in 30% of the control group.

Conclusions:

Osteitis of the uncinata bone is present in both asymptomatic control patients as well as those undergoing surgery for CRS. These results question the contribution of UP osteitis as a significant factor in the pathogenesis of CRS. This preliminary data needs to be further evaluated in large-scale CRS and healthy populations.

The Relationship of the Natural Sphenoid Ostium to the Skull Base

Akaber Halawi, MD, Patrick Simon, MD, Alcina Lidder, MD, Rakesh Chandra, MD Chicago, IL USA

Introduction:

Various intranasal landmarks have been described to aid in localization of the natural sphenoid sinus ostium. The objective of this study is to identify the ostium location relative to the skull base, and to assess relationships between ostium location and either sphenoid disease or pneumatization pattern.

Methods:

202 consecutive Xoran Mini-CAT scans of patients with no prior history of sinus surgery were evaluated. The natural sphenoid ostium was identified in axial, coronal, and sagittal planes. Distances from the planum to the ostium and from the planum to the sinus floor were calculated. Lund-Mackay score and pneumatization pattern were recorded for each sphenoid sinus.

Results:

Mean distance from planum to ostium was 11.2 +/- 2.8mm (range 4.4-19.2mm). This, on average, encompassed 46.5 +/- 11% of the total sphenoid height. ANOVA with post hoc Tukey analysis revealed that the ostium was closer to the planum in sinuses with sellar ($p=0.02$) or presellar ($p=0.009$) pneumatization, compared to those where pneumatization was postsellar. Although asymmetry was observed in some patients, the ostium tended to be in a similar position on each side. There was no significant relationship between ostium location and degree of sinus disease.

Conclusions:

The natural ostium of the sphenoid sinus, on average, is located at the midpoint of the sphenoid face. However, significant variability between patients can be observed. Surgeons should also recognize that the ostium may be closer to the skull base when the sinus is less pneumatized.

The Role of Allergic Rhinitis and Age as Potential Risk Factors for Orbital Complications of Rhinosinusitis in Children: Our Experience

Alessandro Pusateri, MD, Elina Motta, MD, Gian Luigi Marseglia, MD, Sara Lambolla, MD, Michele Caputo, MD, Fabio Pagella, MD
Pavia, Italy

Introduction:

The purpose of this report is to determine allergic rhinitis (AR) and age as potential risk factors for the development of orbital complications of rhinosinusitis in children.

Methods:

We included in the present study 72 patients presenting to our departments with a diagnosis of rhinosinusitis with orbital complications, from 2005 until 2011. All patients were investigated by flexible nasal endoscopy as well as for underlying AR. Computed tomography (CT) was obtained only in selected cases.

Results:

They were grouped according with Chandler's classification: Preseptal cellulitis was diagnosed in 45 patients (62.5%); orbital cellulitis in 25 (34.7%); an orbital subperiosteal abscess in 2 (2.8%). No orbital abscess or cavernous sinus thrombosis were found. In 26 (36.1%) of the 72 patients an accurate allergy evaluation was performed with skin prick testing. AR was found in 7 (53.8%) of 13 children with preseptal cellulitis, in 2 (18.2%) out of 11 with orbital cellulitis, and in 1 (50%) out of 2 with subperiosteal abscess. The prevalence of AR was higher in patients presenting in pollen season from March to August (8:17) than in patients presenting between September and February (2:9).

Conclusions:

AR could be considered a possible cofactor in the pathogenesis of orbital complications of rhinosinusitis in children. Moreover, according to our population, age only influences the type of orbital complication and not the incidence. In fact, in our series, older children are more likely to develop subperiosteal abscess (mean age 7 years), whereas younger children develop preseptal cellulitis (mean age 4.8 years).

Tilt CT Image Reconstruction and Analysis in Assessment of Frontal Sinus Outflow

Allison Fry, BS, Wade Han, MD
Orlando, FL USA

Assessment of frontal sinus outflow and its obstruction is critical during diagnosis and preoperative planning for frontal sinus surgery. Understanding frontal drainage pathway with standard orthogonal triplanar (coronal, axial and sagittal) analysis is challenging because of anatomical variability, inconsistent imaging techniques and oblique nature of the pathway. We hypothesize by tracing the frontal sinus outflow through the inferior frontal and anterior superior ethmoid region, in a plane perpendicular to the outflow pathway, will provide the most visually intuitive understanding of its torturous course amongst various high frontoethmoid cells. This plane will allow surgeons to pinpoint where the outflow obstruction occurs and determine which frontoethmoid cells contribute to the narrowing. In addition, the dimensions and shapes of various relevant anterior ethmoid cells surrounding the outflow pathway can be studied. Cephalometric landmarks are used to achieve a consistent tilt angle where the frontal outflow tract is readily visualized. The tilt angles in 49 consecutive patients undergoing routine maxillofacial CT studies are statistically analyzed. The plane through Nasion and bilateral Orbitale is noted to be the most consistent and useful in studying frontal outflow pathway. It ranges from 20-36 degrees with an average of 27 degrees in relation to the hard palate. The CT image sets in this tilt plane from frontal sinus roof to frontal outflow exit in middle meatus or infundibulum are studied; frontal outflow anatomical findings are recorded and tabulated. Frontal outflow exit anatomy on CT at superior middle meatus/infundibulum is compared with 70 degree rigid middle meatal endoscopic examination.

Turbinate Reduction Using the Turbinate Sculpting Method

*Charles Hurbis, MD
Coos Bay, OR USA*

Intro:

Finding the best method of inferior turbinate reduction continues to be an ongoing process. Options include complete or partial reductions by way of various thermal shrinkage techniques, direct mucosal removal or stroma reductions. Control of the end result can be troublesome since there are large patient to patient variations in anatomy and mucosal make-up. The method that I have found most consistent in correcting inferior turbinate hypertrophy is a precise turbinate sculpting technique which will be described and demonstrated.

Methods:

For this study ten patients were enrolled and treated for turbinate hypertrophy by the sculpting technique. Turbinates were addressed and treated in thirds. Pre, intra and post-operative photos of the airways were documented. Procedural videos were taken for demonstration purposes. Treatment success was based on the NOSE scale subjective responses and acoustic rhinomanometry measurements.

Results:

All of the patients achieved dramatic improvements in their nasal airways both subjectively and objectively measured at 4+ weeks after their surgery. We did not encounter any issues with unusual intra or post-operative bleeding. There were no complications.

Conclusions:

The turbinate sculpting method has allowed us to achieve consistent improvement in our patients with turbinate hypertrophy. This method produces an accurate, uniform reduction of the turbinates, regardless of patient to patient variations in nasal anatomy or mucosal type. It is also a safe technique which allows for maximal safe effect with less chance of over reduction.

Typical Carcinoid Nasopharyngeal Tumor: Highlights of a Unique Case

*Mathieu Bergeron, MD, B.Pharm,
Sylvie Nadeau, MD
Quebec, Quebec Canada*

Objective:

Carcinoid tumors are rare, particularly in the head and neck region. The first case of primary well-differentiated carcinoid tumor arising from the nasopharynx was documented in 2009 by Warman et al and treated by combined external beam radiation and cold somatostatin analogue. No case of this unique type of lesion had been successfully treated with surgery alone until now.

The Case:

A 68 year-old previously healthy woman was referred to our tertiary care center for long-term unilateral nasal congestion of unknown etiology. Upon rigid sinusoscopy exam, a right-sided nasopharynx pedunculated mass close to the Rosenmüller's fossa was visualized. An enhanced MRI showed a nasopharyngeal mass with an isointense nasopharyngeal lesion on T2-weighted involving superior right-sided nasal cavity. Biopsy was highly suspicious of a typical carcinoid. This was confirmed on both the morphologic and immunologic exams. The lesion was successfully removed with transnasal endoscopic surgery with negative margins. Six weeks after the surgery, the patient underwent an octreotide scintigraphy, which was normal.

Conclusion:

To our knowledge, this was the first case successfully treated and cured with endoscopic surgery alone. In case of localized typical carcinoid tumors, negative margins at the time of the surgery and a negative octreotide scintigraphy don't require any other modality of treatment. Periodic follow-ups with complete head and neck exam.

Utility of Three Dimensional CT Reformatting of the Skull Base as an Aid to Surgical Planning

Aaron Fletcher, MD, Jeremy Greenlee, MD, Erin O'Brien, MD, Scott Graham, MD, Eugene Chang, MD
Iowa City, IA USA

Introduction:

Pre-operative identification of skull base defects is central to the planning and success of endoscopic repair. As high-resolution computed tomography (CT) imaging technology has progressed, the subsequent number of 2-dimensional images has increased. The burden of 3-dimensional interpretation of these images has fallen to the surgeon. Our objective is to develop a 3-d computer-generated model to assist surgeons in identifying skull base defects.

Study design:

Retrospective case series of three patients who had undergone endoscopic repair of anterior skull base defects.

Methods:

We utilized Amira, a software platform to convert 2-d CT images to a 3-d model segmented into skull, brain, and soft tissue windows to quantify the size of the skull base defect. Our findings were validated by a neuroradiologist interpretation of the 2-d images.

Results:

We successfully developed a segmented 3-d model of the skull base in approximately 15 minutes time from the 2-d images. This model enabled visualization of the skull base defect from various perspectives, including an endoscopic as well as top-down approach. Quantification of the size and location of the defect were similar between the 3-d model and the 2-d CT findings.

Conclusions:

3-d computer models of the skull base enable the surgeon a unique perspective in the preoperative planning of skull base defect repair. With practice, this technique is accurate and efficient and may assist in the analysis of skull base defects.

Validation of a Novel Device for Nasal Particulate Delivery: A Pilot Study

Khaili Sammy, MD, Brian Rotenberg, MD MPH
London, Ontario Canada

Introduction:

Intranasal medication delivery for chronic rhinosinusitis or allergic rhinitis is considered a mainstay of therapy but is hampered by poor compliance. Amongst reasons given are the unpleasant sensations associated with spray penetration into the naso- or oro-pharynx. Our objective was to validate a novel method of particle delivery to the nose that would abrogate these issues.

Methodology:

Subjects who met study criteria underwent intranasal particle delivery using a novel device (Trivair Nasal Deposition System, Trimel Pharmaceuticals, Toronto) that delivered anhydrous lactose particles into the nose via a transoral air puff (thus elevating soft palate and blocking the nasopharynx). Subjects had their nostrils randomized into four groups (particle size 5 micron and 50 micron versus dose 12.5mg and 25mg). Using a high-definition endoscopic photography, particle deposition was assessed at 1 minute, 10 minutes and 30 minutes on the inferior turbinate, middle turbinate, and nasopharynx respectively. Each image was compared using an expert 2-person panel for percentage particles remaining. Non-parametric data was assessed using Strata software using a Wilcoxin sign-rank test.

Results:

Twelve nostrils in total met study criteria. The results showed no difference in effectiveness of nasal particle retention between the groups based on particle size or dose. No particles entered the naso- or oro-pharynx. There were no statistical differences between the groups.

Conclusion:

This study provides proof-of-principle evidence that the Trivair Nasal Deposition System is effective at retaining medication in the nose without pharyngeal penetration. This provides springboard evidence to move forward with larger studies on this device.

Vibratory Energy Applied to Facial Soft Tissue to Alleviate Pain during Nasal Instrumentations

*Allison Fry, BS, Wade Han, MD
Orlando, FL USA*

Despite adequate topical anesthesia, nasal instrumentations including routine nasoendoscopy and fiberoptic laryngoscopy may involve a considerable amount of pain and discomfort when nasal mucosa membrane is touched in patients who are awake. Classic Melzack-Wall Gate theory of Pain suggests simultaneous stimulation of larger non-noxious surface nerve endings may alleviate perceived pain from smaller nasal cavity nerve endings during intranasal manipulation. We hypothesize, vibratory energy applied transcutaneously to supraorbital and supratrochlear nerves, branches of the larger frontal nerve (V1), may alleviate painful stimuli of the smaller intranasal anterior and posterior ethmoid branches of nasociliary nerve. In maxillary (V2) distribution, vibratory energy applied to the larger infraorbital nerve, through facial soft tissue, may alleviate pain of smaller branches of palatine and superior alveolar nerves intranasally. A pilot study of 30 patients undergoing in office fiberoptic laryngoscopy or deep middle meatal nasoendoscopy was conducted. Vibratory energy was applied to infraorbital and supraorbital regions respectively when mucosa contact is unavoidable and pain is verbalized by the patient. Subjective pain scores rated on Wong-Baker scale of 1-10 by the patient, before and after the vibratory application, were recorded. The pain scores from a control cohort of 30 patients undergoing the same intranasal instrumentation, without external pain alleviator, were obtained and compared. This preliminary study shows that transcutaneous vibratory energy application, over larger terminal branches of trigeminal V1 and V2, alleviates pain perception during in office intranasal or transnasal instrumentations.

Volumetric Analysis of the Paranasal Sinuses in Patients with Cystic Fibrosis

*Winslo Idicula, MD, Stanley McClurg, MD,
Stephen Kirkby, MD, Meredith Merz, MD
Columbus, OH USA*

Objective:

The objective of this study is to use a new volumetric analysis technique to compare the paranasal sinus volumes, as seen on CT scan, of adult Cystic Fibrosis patients to those of normal adult controls. We hypothesize that the sinus volumes will be significantly smaller in patients than in controls.

Study Design:

Retrospective Pilot Study

Methods:

The Terarecon 3D system will be used to calculate the volumes of the maxillary, frontal, and sphenoid sinuses on CT scans in ten adult patients with Cystic Fibrosis and compare them to ten adult controls. This system uses the Hounsfield unit of air within each sinus to compute the volume of the specified spaces in a three dimensional format. These findings will also be correlated to the Lund-Mackay scoring system.

Results:

We will demonstrate the method of the Terarecon 3D system in analyzing sinus volumes. We will report the volumes of the sinuses in our Cystic Fibrosis patient population and the control population. Additionally, we will use this pilot data to determine if a study with a larger sample size is indicated and to determine whether the degree of hypoplasia predicts the severity of symptoms or frequency of surgery.

Discussion:

There is evidence to suggest that patients with cystic fibrosis have hypoplasia of the sinuses. If true, this could also contribute to the propensity to sinus disease in this population. Sinus hypoplasia should be recognized as it has significant surgical ramifications and increases the likelihood of certain complications, including orbital injury.

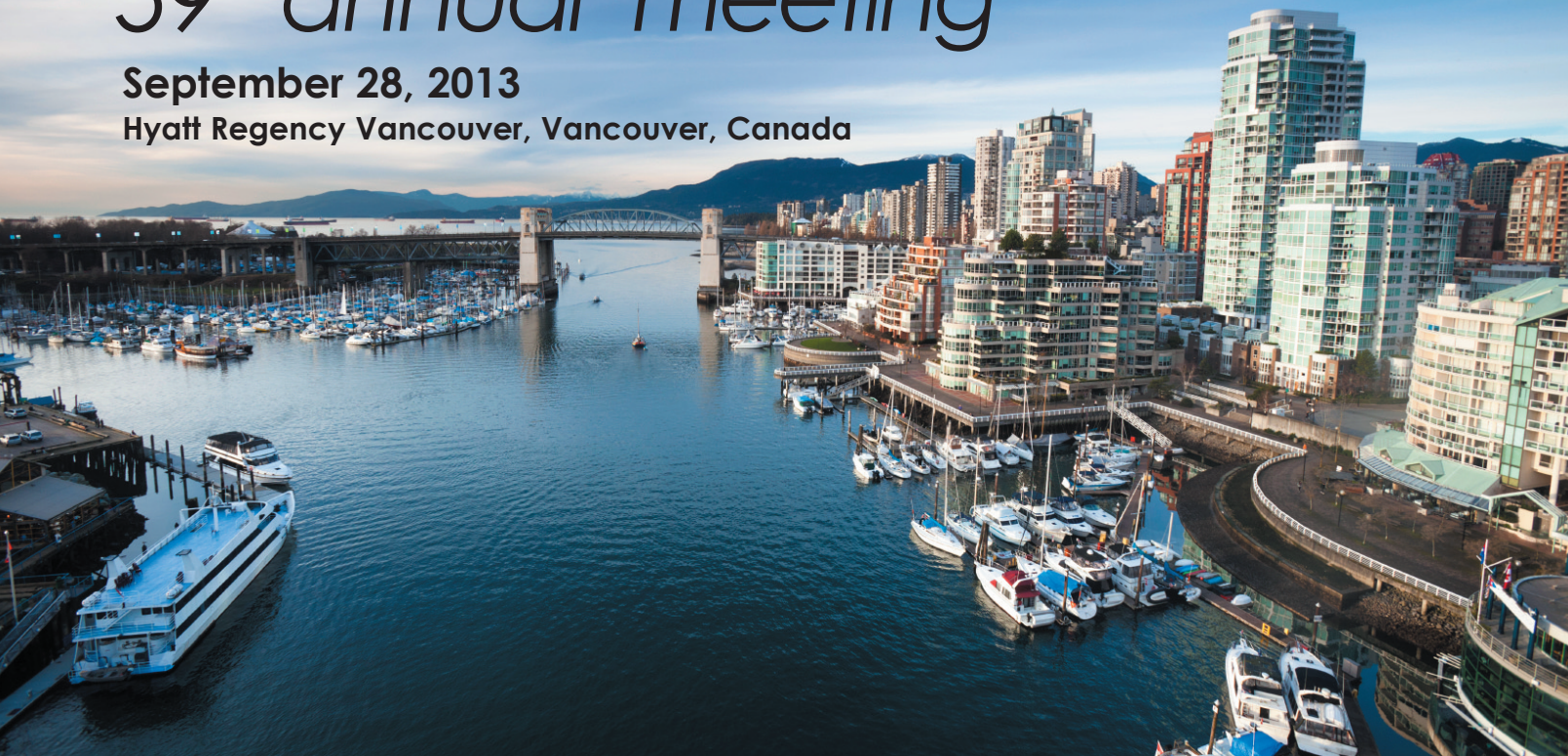



59th annual meeting

September 28, 2013

Hyatt Regency Vancouver, Vancouver, Canada



59th Annual Meeting of the ARS

www.american-rhinologic.org/annual_meeting

Guest Countries: *Australia, China, New Zealand* and *South Korea*

September 28, 2013* Hyatt Regency Vancouver, Vancouver, Canada

**One day prior to AAO-HNS Mtg*

Abstract Deadline: June 10, 2013 **Manuscript Deadline:** Aug. 26, 2013

Program Highlights:

Panel: *What is Happening in the World of Rhinology: An International Forum of Allergy & Rhinology*

Panel: *An Insightful Discussion: In hindsight, I would have handled this differently. Lessons learned the hard way...*

The 9th Annual Kennedy Lecture: Berrylin J. Ferguson, MD: *Twenty-five Years of Sinus Study: learning and unlearning*

Showcasing ARS Research and the International Forum of Allergy and Rhinology

ARS/AAOA Combined Panel: *Changing Your Practice: Strategies to Manage Your Patients with Recalcitrant Rhinosinusitis*

Join your colleagues to discuss the latest advances in our field and discuss your challenging cases!

For further information, please contact Wendi Perez, ARS Administrator, American Rhinologic Society, PO Box 495, Warwick, NY 10990
Tel: 845.988.1631 • Fax: 845.986.1527 • wendi.perez@gmail.com

www.american-rhinologic.org